

Evaluation of Risk Factors and Preventive Measures for Deep Vein Thrombosis of Lower Limbs in Minimal Access Surgery

Shilpa Sapre

Assistant Professor, Partima Institute of Medical Sciences, Naguur, Karim Nagar, Andhra Pradesh, India

Abstract

Deep vein thrombosis of lower limbs affects 1-2% of hospitalized patients. Interplay of factors like vessel wall injury, venous pooling, decreased blood flow and state of hypercoagulability predispose to thrombi formation.

In conventional surgery as compared to the minimal access surgery, the prolonged surgery time, longer hospital stay, prolonged immobilization and enhanced tissue disruption favors thrombi formation in lower limbs. However the risk of deep vein thrombosis in laparoscopic surgery is related to the high intra-abdominal pressure and the reverse trendelenburg position causing venous pooling in lower limbs particularly in upper gastrointestinal surgery.

Keywords: Deep vein thrombosis, laparoscopic surgery, cholecystectomy, gastric by-pass, gynecological surgery, heparin prophylaxis, preventive measures .

AIMS AND OBJECTIVES

This article aims to focus on the relative risk of deep vein thrombosis in laparoscopic gastrointestinal as well as gynecological surgery with a special focus on the thromboprophylaxis and mechanical therapeutic measures necessary to prevent deep vein thrombosis.

MATERIAL AND METHODS

A literature search was performed using Google search engine Highwire press, Springer link and Pubmed using above mentioned keywords. Selected papers were screened for further references. Criteria for selection were the number of cases (excluded if less than 20) methods of analysis (statistical or nonstatistical), operative procedures (only universally accepted procedures) and the institution where study was performed (reputed for laparoscopic surgery).

Search provided a variety of review articles but only 7 were selected as per the criteria.

CONTENT

1. Systemic coagulation and fibrinolysis after laparoscopic and open gastric by-pass.

Nguyen NT, Owings JT, Goselin R et al.

Arch Surg. 2001 Aug; 136 (8): 909-16.

Seventy patients were randomly assigned to laparoscopic (n = 36) or open (n = 34) gastric by-pass. Deep vein thrombosis prophylaxis in form of antiembolism stockings and sequential pneumatic compression devices were given. D-dimer, antithrombin III and protein C levels were checked along with venous duplex scan of lower limbs. DVT was found in 1 of 34 patients after open gastric by-pass but nondeveloped in laparoscopic group.

2. Incidence of lower limbs deep vein thrombosis after open and laparoscopic gastric by-pass a prospective study

Brasiliero AL, Miranda F Jr, Ettinger JE et al.

Obes Surg 2008; 18(1): 52-57.

136 patients were included in the study group of which only 126 concluded the protocol. All were subjected to RYGBP by laparotomy or laparoscopy using 40 mg/day of enoxaprin for 15 days. 69 underwent laparoscopy and 57 underwent open RYGBP. DVT incidence was 0.79% (1/126).

3. Venous stasis and DVT prophylaxis during laparoscopic fundoplication

Kiudelis M, Enndzinis Z et al.

Zentralbl Chir. 2002 Nov; 127(11): 944-49.

Fifty-four patients undergoing elective laparoscopic fundoplication were included in the study and divided into 3 groups. First group were given leg bandages, second group were given intermittent pneumatic compression, third group were given intermittent electric calf muscle stimulation.

Doppler ultrasonography was during operation. DVT and pulmonary embolism incidence after laparoscopic fundoplication was 1.8%.

4. Low frequency of phlebographic DVT after laparoscopic cholecystectomy—A Pilot study

Fredrik Lindberg MD, PhD

Clinical and applied thrombosis/hemostasis Vol 12, Nov. 2006;421-25.

Fifty patients were screened for DVT by bilateral phlebography after laparoscopic cholecystectomy. Frequency was 2%.

5. Incidence of deep vein thrombosis after gynecological laparoscopy.
Feng L, Song J, Wong F, et al. *Chin Med J (Engl)* 2001 Jun; 114(6): 632-35.
Seventy patients undergoing gynecological laparoscopic surgery were screened by B-mode ultrasound supplemented by Doppler. No DVT was found.
6. ORIGINAL ARTICLE
The incidence of venous thromboembolism following gynecological laparoscopic—a multicentric, prospective cohort.
W Ageno, E Manfredi, F Dental, et al.
J Throm Hemostat 2007 Mar; 5(3):503(6).
In a prospective cohort patients undergoing gynecological laparoscopic surgery were assessed by compression ultrasonography and clinically for venous thrombosis. CUS WAS DONE ON 7+/-1 AND 14+/- day postoperative Mean duration of procedure was 60.5 minutes. No episodes of CUS detected DVT nor clinical episodes of DVT were seen.
7. Thromboembolism prophylaxis and incidence of thromboembolic complications after laparoscopic surgery.
Catheline JM, Cappeluto E, Gaillard JL.
Int J Surg Investing. 2000; 2(1):41-47.
2384 patients received low molecular weight heparin (LMWH). Eight patients developed DVT, 6 out of 8 were diagnosed after cessation of LMWH.

operative work up is necessary in all patients undergoing laparoscopic surgery.

Symptoms and signs of DVT are caused by obstruction to venous outflow, inflammation of the vessel wall or pulmonary embolization (Fig. 2).

Diagnosis is on clinical grounds while the imaging modalities confirm the diagnosis. Noninvasive tests like Duplex ultrasound, color Doppler, MRI, CT while invasive tests include venography. Ultrasound (Fig. 3) has a 96% specificity and sensitivity while color Doppler imaging has 100% sensitivity and specificity for diagnosing DVT.

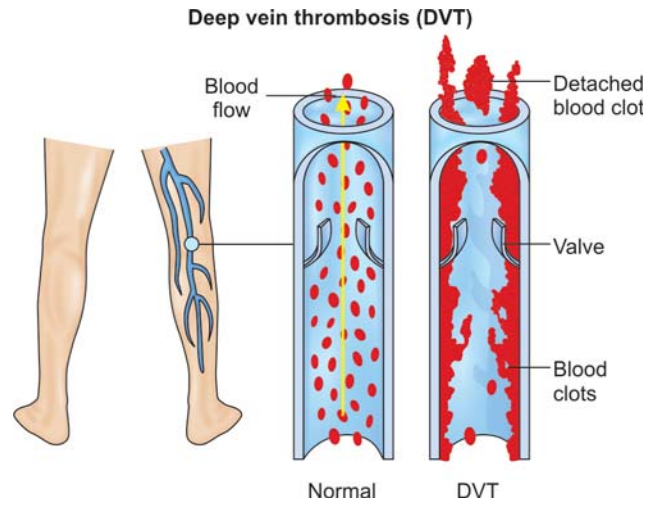


Fig. 1: Defective valve mechanism in DVT

INTRODUCTION

“Necessity is the Mother of Invention”. The pitfalls of conventional surgery paved the way for minimal access surgery. Since its introduction there has been a vast improvement in the techniques and approach of minimal access surgery.

Creation of pneumoperitoneum which is the basis of laparoscopic surgery.

It is associated with reduction in the blood flow of the splanchnic, renal, femoral and venacaval circulation (Fig. 1). This reduction in blood flow associated with venous pooling in lower limbs due to reverse trendelenburg position paramounts to formation of venous thrombi. Migration of venous thrombi to vital organs like brain, lungs heart can prove fatal.

Laparoscopic upper GI surgery are more prone for thrombi formation due to long sugery time, high intraperitoneal pressure and reverse trendelenburg position as compared to gynecological laparoscopic surgery. Even the laparoscopic colorectal surgery are prone for DVT due to extensive dissection, prolonged surgery time, old age and at times associated malignancy.

A variety of risk factors predispose to DVT like previous h/o venous insufficiency, old age, obesity, malignancy, immobilization, hypercoagulable state, varicose veins, surgery more than 2 hours. Hence judicious selection of cases and pre-

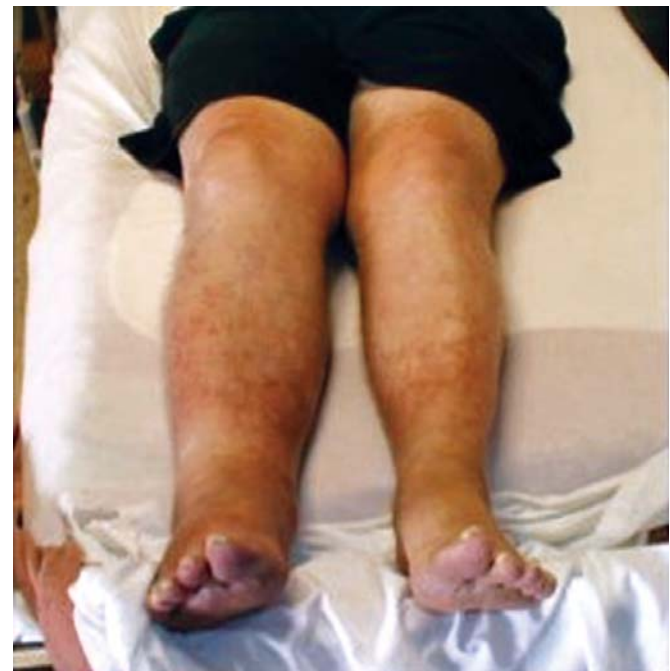

Fig. 2: Patient of deep vein thrombosis

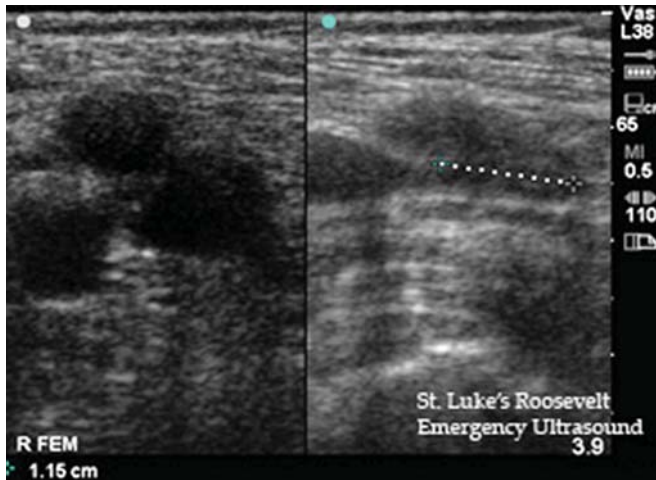


Fig. 3: Ultrasound imaging for deep vein thrombosis

Preventive measures towards thrombosis include use of elastic stockings, intermittent pneumatic compression, electric calf muscle stimulation coupled with thromboprophylaxis in form of LMWH. Heparin prophylaxis is recommended in moderate and high-risk patients hence risk stratification of patients is necessary before surgery to avoid DVT. Recommendations suggest that heparin prophylaxis be started 12-24 hours before surgery and to be continued till discharge of the patient.

Advantages of heparin prophylaxis include cost efficacy, single dose administration and high potency. Adverse effects have been noted with heparin like abdominal hematomas, poor wound healing, bruises, intracranial bleed hence pros and cons should be weighed before using this drug.

DISCUSSION

Laparoscopic surgery specially the upper GI Surgery predispose the patients to DVT as compared to gynecological surgery due patient positioning and high pressure requirements.

Review article 1 shows that open gastric by-pass predisposes to DVT more in comparison to laparoscopic surgery. Mechanical therapeutic measures like elastic stockings, intermittent sequential compression were considered in all patients still 1 patient developed DVT hence these preventive measures seem necessary to prevent a fatal outcome.¹

Review article 2 reflects the incidence of DVT in lower limbs after gastric by-pass. Study showed that obesity may not be a predisposing factor. However obese patients require extensive preoperative check up as well as intraoperative prophylactic measures to curb the risk of DVT.²

Review article 3 was included with a purpose to reflect the role of mechanical therapeutic measures in preventing DVT as well as to study the effect of pneumoperitoneum on femoral venous blood flow. There was a decrease the venous blood flow and the cross-sectional area of the vein after creation of pneumo-

peritoneum. Of all the measures Intermittent sequential compression seems to be most effective in combating the adverse effects of pneumoperitoneum.³

Review article 4 depicts low incidence of DVT after laparoscopic cholecystectomy. The role of thrombo-prophylaxis in all laparoscopic surgeries seems questionable.⁴

Review articles 5 and 6 were included with a purpose to reflect the low incidence of DVT after gynecological surgery for benign conditions like ovarian cyst, endometrioma, adnexal masses and also in patients with infertility. Negation of factors responsible for DVT in upper GI as well as colorectal surgery might be the cause for low risk.^{5,6}

Review article 7 was included with the prospect of highlighting the need for heparin prophylaxis in moderate and high-risk patients prior to surgery. And to be continued till the day of discharge of the patient. It is important as well to advocate the use of low insufflation pressures, intermittent release of pneumoperitoneum and using the reverse Trendelenburg position for a minimum time to avoid DVT.⁷

CONCLUSION

“An ounce of prevention is worth a pound of cure “

Deep vein thrombosis developing after laparoscopic surgery can be prevented by optimizing the intraperitoneal pressure, intermittent release of pneumoperitoneum and using reverse Trendelenburg position for minimum time. Preoperative risk stratification of patients for heparin prophylaxis and intra-operative use of the intermittent pneumatic compression in prolonged surgery is the key to prevent deep vein thrombosis of lower limbs.

REFERENCES

1. Line BR. Pathophysiology and diagnosis of deep vein thrombosis. *Semi Nucl Med* 2001 Apr;31(2):90-101.
2. Pilger E, Obernosterer A, Stark G, Decrinis M. Etiology of DVT of leg. *Acta Med Austriaca* 1991;18(3):68-72.
3. Barrellier MT. Venous Echo Doppler: A future standard test in the diagnosis of thrombosis of lower limbs. *Ann Fr Anaesth Reanim* 1992;11(3):370-76.
4. SS Tan, BK Chong, FL Thoo, JTS Ho, HK Boey. Diagnosis of DVT: Accuracy of colour Doppler ultrasound compared with venography. *Singapore Med J* 1995;36:362-66.
5. Diagnosis of DVT: Accuracy of color Doppler ultrasound compared with venography. *Singapore Med Journal* 1995.
6. Chethan Gangireddy, MDA John, John R Rectenwald, MDA Gilbert R, Upchurch, MDA Thomas W, Wakefield, MDA Shukri Khuri, MDB, William G Henderson, Henke PK. Risk factors and clinical impact of postoperative symptomatic venous thromboembolism. *J Vasc Surg* 2007;45(2)335-42.
7. Holzheimer RG. Review laparoscopic procedures as a risk factor of deep vein thrombosis, superficial ascending thrombophlebitis and pulmonary embolism—Case report and review of literature. *Euro J Med Res* 2004 Sept 29;9(9):417-22.