

# Case Report Related to Laparoscopic Cholecystectomy

Anup Hazra, Richard Siderits, Archan Hazra, Janusz Godyn

Department of Pathology and Laboratory Medicine, UMDNJ-RWJ Medical School and RWJ University Hospital at Hamilton Hamilton, NJ 08690, USA

Correspondence: Anup Hazra

Associate Professor of Pathology and Laboratory Medicine, RWJ Medical School

Vice Chairman and Director of Laboratories, Department of Pathology and Laboratory Medicine

RWJ University Hospital at Hamilton, 1 Hamilton Health Place, Hamilton, NJ 08690

609-584-6569 (p), 609-584-6439 (f), ahazra@rwjuh.edu, hazraan@yahoo.com

## INTRODUCTION

Post laparoscopic cholecystectomy bile spillage, presented clinically as acute appendicitis, mimicking intraoperatively peritoneal carcinomatosis.

Laparoscopic cholecystectomy is a highly popular, minimally invasive surgery, which outweighs the standard “open” surgery for gallbladder operation. However, there are some short-term and long-term complications as a result of intraoperative spillage of bile and gallstones during laparoscopic cholecystectomy. We present this interesting case of a patient who presented with symptoms of acute appendicitis ten years after the laparoscopic cholecystectomy due to the inflammatory response to the bile deposits inside the pelvic peritoneum, which upon diagnostic laparoscopy, mimicked peritoneal carcinomatosis.

## REPORT OF A CASE

The patient was a 30-year-old female who was admitted to the emergency room with intermittent sharp and dull pain to her right lower quadrant for the past two days. Patient denied any nausea, vomiting, diarrhea, constipation or temperature. She was in complete normal health prior to this episode. Her past medical and surgical history included hypothyroidism, known allergies to penicillin, and laparoscopic cholecystectomy ten years before. She denied alcohol, tobacco or drug abuse.

Physical examination revealed normal bowel sounds, positive peritoneal signs and guarding. However, Rovsing’s sign was absent. Laboratory examination showed mild leukocytosis with slight increase of neutrophils. Computed tomography (CT) of abdomen and pelvis showed mild intra and extra hepatic biliary dilatation. Magnetic resonance imaging (MRI) of abdomen showed no evidence of choledocholithiasis.

Preliminary impression was to rule out acute appendicitis, ectopic pregnancy or urinary tract infection.

## MATERIALS AND METHODS

The urinalysis shows no pathologic findings and urine cultures were negative. The patient was admitted for diagnostic laparoscopy and probable laparoscopic appendectomy. During the procedure, the surgeon noted multiple small yellow nodules studded on the omentum, serosa of the appendix, and pelvic peritoneum. Proximal segment of the vermiform appendix (Fig. 1) was slightly dilated. These yellow nodules clinically raised the suspicion of peritoneal carcinomatosis. Fallopian tubes and ovaries were unremarkable. Appendectomy was performed and omental biopsy included some of these nodules.

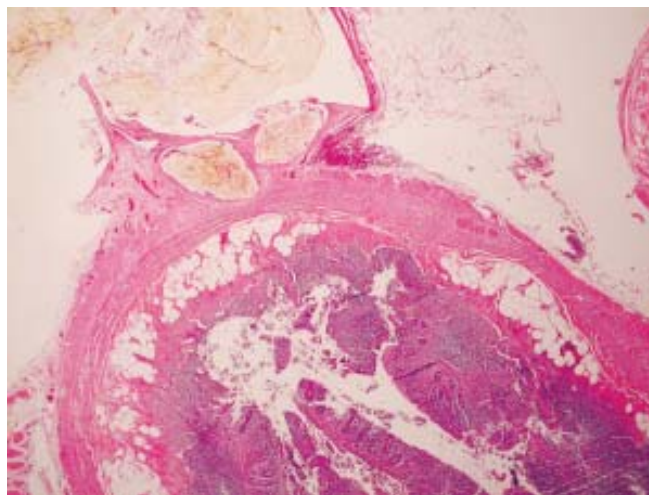


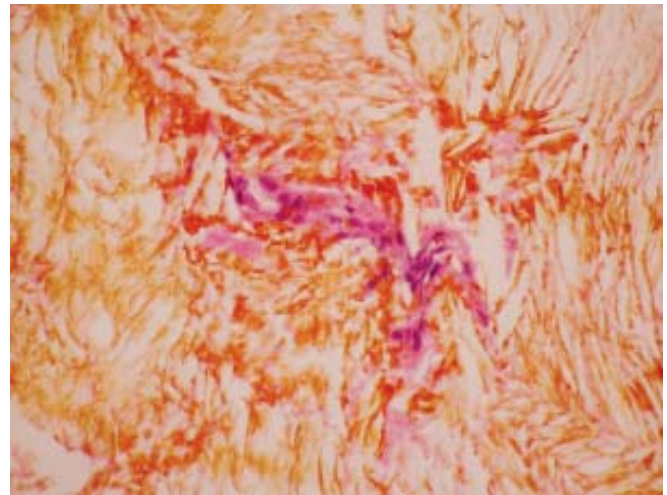
Fig. 1: Vermiform appendix with serosal implants (2X, H and E Stain)

## **PATHOLOGIC FINDINGS**

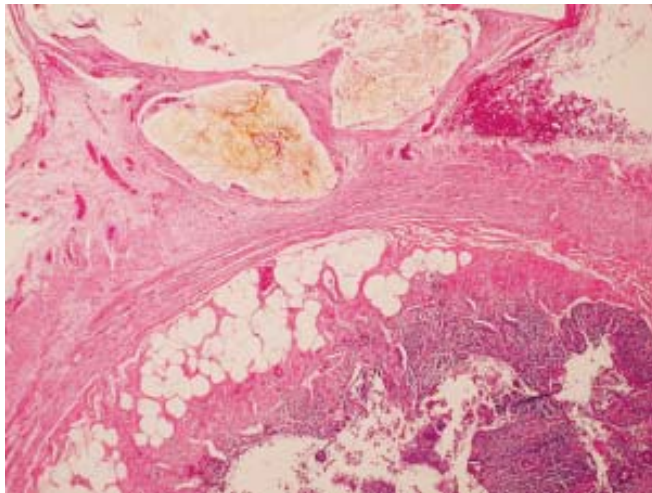
1. Nodules with nonpolarizing yellow bile pigment material/precipitate and cholesterol crystals associated with foreign body (Figs 2 to 4) type chronic granulomatous inflammation on serosa of appendix and omentum. No evidence of carcinoma.
2. Mild periappendicitis. The lumen is slightly distended with hemorrhagic fluid.

## **COMMENT**

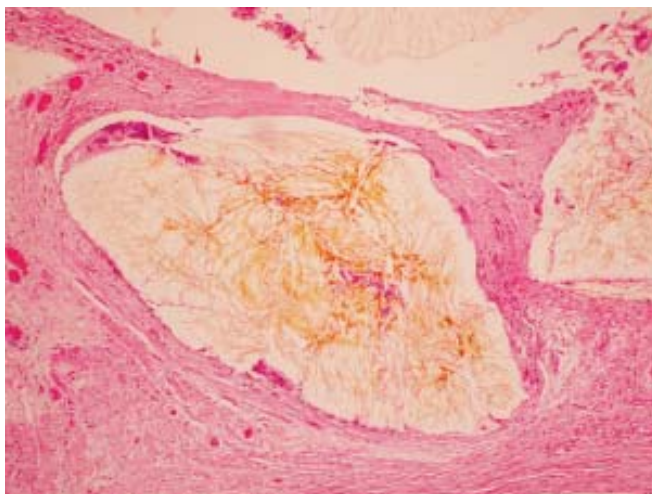
A review of the history of minimal access surgery by Dr RK Mishra<sup>1</sup> goes back to 1585. Laparoscopic surgery was originally popular amongst gynecologists and orthopedic surgeons. The first scientifically documented laparoscopic



**Fig. 4:** Foreign body reaction associated with bile pigment (40X, H and E Stain)



**Fig. 2:** Loculated bile cysts (4X, H and E Stain)



**Fig. 3:** Bile cysts with fibrous adhesions and periappendicitis (10X, H and E Stain)

cholecystectomy was performed by Erich Muhe in Germany in 1985.<sup>1</sup> Eddie Joe Reddick and Olsen popularized this procedure in the United States in 1989.<sup>1</sup>

There are both short and long-term complications of this minimally invasive procedure, especially in laparoscopic cholecystectomy from the spillage of bile and gallstones inside the peritoneal cavity. Minor intraoperative perforation of the gallbladder occurs in approximately 29% cases. Immediate complications include localized bile collection in the gallbladder fossa, which can be treated by endoscopic retrograde cholangiopancreatography (ERCP) with biliary stenting.<sup>2</sup> Some complication resulted in inflammation and intra-abdominal abscess<sup>3</sup> or, retroperitoneal abscess formation, mimicking gluteal abscess.<sup>4</sup> Attempts should be made to irrigate the field of operation to remove the spilled bile and gallstone to avoid future complications. Other complications include granulomatous peritonitis, mimicking pelvic endometriosis.<sup>5</sup> Sometimes, early complications can be manifested by postoperative pain and pyrexia, identified and corrected.

But, some long-term complications are fascinating to both surgeons and pathologists, which may arise even several years after the operation. Careful taking of history is important to correlate the complications of past laparoscopic procedure with the present illness. Intestinal adhesions and obstruction from chronic serositis or abnormal radiographic presentation of the nodules mimicking tumor are not uncommon. A prospectively maintained database of 1528 patients showed complications in 12% of gallstone spillage patients.<sup>6</sup> To avoid psychological trauma to the patient related to misdiagnosing cancer or performing unnecessary laparotomy, the surgeons should follow on those patients postoperatively. Ultrasound or CT is the most sensitive means for tracing spilled gallstones or abscesses. Cholelithoptysis is a rare complication, including chest discomfort and pleural effusion.<sup>7</sup> Some unusual late

presentations of spilled gallstones and bile include abdominal wall sinus,<sup>8</sup> acute appendicitis,<sup>9</sup> and spontaneous erosion through the back,<sup>10</sup> Sometimes, chronic pain and jaundice can be seen from the retained stones.<sup>11</sup> Bile and stones should be completely removed from the peritoneal cavity, to prevent late complications and unwanted laparotomy.

In conclusion, every effort should be made to make this simple procedure valuable to the patient, clinicians themselves, and long-term cost effective for the health care by removing thoroughly the bile and the gallstones from the peritoneal cavity.

## REFERENCES

1. Mishra RK. History of minimal access surgery. [http://www.laparoscopyhospital.com/history\\_of\\_laparoscopy.htm](http://www.laparoscopyhospital.com/history_of_laparoscopy.htm)
2. Meshikhes AW, AbulRahi A, Al-momen SA, Al-Safran Z, Al-Daolah QH. An unusual bile collection after postcholecystectomy bile leakage. *Surgical Laparoscopy, Endoscopy and Percutaneous Techniques* 2007;17(2):138-40.
3. Rice DC, Memon MA, Jamison RL, et al. Long-term consequences of intraoperative spillage of bile and gallstones during laparoscopic cholecystectomy. *Journal of Gastrointestinal Surgery* 1997;1(1):85-91.
4. Dashkovsky I, Cozacov JC. Spillage of stones from the gallbladder during laparoscopic cholecystectomy and complication of a retroperitoneal abscess mimicking gluteal abscess in elderly patients. *Surgical Endoscopy* 2002;16(4):717. Epub 2002 Jan7.
5. Merchant SH, Haghiri S, Gordon GB. Granulomatous peritonitis after laparoscopic cholecystectomy mimicking pelvic endometriosis. *Obstetrics and Gynecology* 2000;96 (5 Pt 2): 830-1.
6. Tumer AR, Yuksek YN, Yasti AC, Gozalan U, Kama NA. Dropped gallstones during laparoscopic cholecystectomy: the consequences. *World Journal of Surgery* 2005;29 (4):437-40.
7. ChanSY, Osborne AW, Purkiss SF. Cholelithoptysis: an unusual complication following laparoscopic cholecystectomy. *Digestive Surgery* 1998;15(6):707-08.
8. Chowbey PK, Goel A, Bagchi N, Sharma A, Khullar R, Soni V, Bajjal M. Abdominal wall sinus: an unusual presentation of spilled gallstone. *Journal of Laparoendoscopic and Advanced Surgical Techniques* 2006;16(6):613-15.
9. Yamamuro M, Okamoto B, Owens B. Unusual presentations of spilled gallstones. *Surgical Endoscopy* 2003;17(9):1498. Epub 2003 Jun17.
10. Memon MA, Deelk RK, Maffi TR, Fitzgibbons RJ Jr. The outcome of unretrieved gallstones in the peritoneal cavity during laparoscopic cholecystectomy. A prospective analysis. *Surgical Endoscopy* 1999;13(9):848-57.
11. Zulfikaroglu B, Ozalp N, Mahir Ozmen M, Koc M. What happens to the lost gallstone during laparoscopic cholecystectomy? *Surgical Endoscopy* 2003;17(1):158. Epub 2002 Oct 29.