

Role of Minimally Invasive Surgery in the Treatment of Ectopic Pregnancy

Babita Gupta

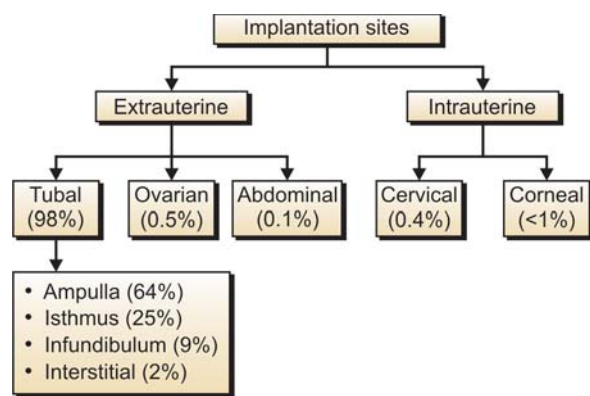
Ex. Senior resident Kasturba Hospital, New Delhi, India
 Ex. Senior resident of Safdarjung Hospital, New Delhi, India

Abstract: Ectopic Pregnancy, in which gestational sac is outside the uterus, is the most common life-threatening emergency in early pregnancy. The incidence of ectopic pregnancy (EP) has increased all over the world from 0.5% thirty years ago, to a present day 1-2%.¹ This complication of early pregnancy, results in not only fetal loss, but also the potential for considerable maternal morbidity and the risk of maternal death.²⁻⁴

Until the risk factors that lead to EP are more fully understood, early detection and appropriate management will be the most effective means of reducing the morbidity and mortality associated with this condition.⁵⁻⁶ Although the incidence of EP increased, with the improvement of diagnostic approaches, patients were detected at an earlier stage and possible to be treated more conservatively.⁷ Surgery remains the mainstay of treatment.⁸ Surgical treatments may be radical (salpingectomy) or conservative (usually salpingostomy), and they may be performed by laparoscopy or laparotomy.⁹ Improved anesthesia and cardiovascular monitoring, together with advanced laparoscopic surgical skills and experience, justifies operative laparoscopy for surgical treatment of EP even in women with hemodynamic instability.¹⁰

Ectopic Pregnancy usually occurs 98% of cases in the uterine tube. Trophoblast can be implanted at various sites:

1. The ampulla (64%)
2. The isthmus (25%)
3. The infundibulum (9%)
4. The intramural junction (2%)
5. Ovarian (0.5%)
6. Cervical (0.4%)
7. Abdominal (0.1%)
8. Intraligamental (0.05%)



Aims and Objectives: The aim of the review to summarize the role of minimal access surgery as in the management of ectopic pregnancy.

Keywords: Ectopic pregnancy, operative laparoscopy, laparoscopic, salpingectomy, cornua, surgical treatment, minimal access surgery.

Material and Method

A literature search was performed using the search engine Google, highwire press and springerlink. Selected papers were taken for the further references.

All articles, RCT, (randomized controlled trial) following predominantly laparoscopic protocol were included for review.

Patients Selection of Laparoscopic Approach

- Confirmed diagnosis
- Absent fetal heart beat
- Hemodynamic stable status
- Accessibility for laparoscopic treatment and trained laparoscopist on duty.

Non-candidates for Laparoscopic Surgery

- Large hemoperitoneum
- Unstable hemodynamic status (stage II or stage III shock)
- Severe pelvic adhesion
- Refusal

Diagnosis

1. Historical Features and Physical Findings

Ectopic pregnancy is usually diagnosed in the first trimester of pregnancy. The most common gestational age at diagnosis is 6 to 10 weeks. Documentation of risk factors is an essential part of history-taking, and asymptomatic clinic patients with risk factors may benefit from routine early imaging. However, more than half of identified ectopic pregnancies are in women without known risk factors.^{11, 12}

Risk factors associated with ectopic pregnancy include:

- Current use of intrauterine device
- Use of clomiphene citrate
- Prior tubal surgery

- Pelvic inflammatory disease
- Infertility
- Induced abortion, adhesions
- Myomata
- Progestin only oral pill

2. Use of Beta Human Chorionic Gonadotropin Measurement

In the emergency department, pregnancy is diagnosed by determining the urine or serum concentration of B human chorionic gonadotropin (β -hCG). This hormone is detectable in urine and blood as early as 1 week before an expected menstrual period. Serum testing detects levels as low as 5 IU/L, whereas urine testing detects levels as low as 20-50 IT/L.^{13, 14} In most cases, screening is done with a urine test, since obtaining the result of a serum test is time-consuming and is not always possible in the evening and at night.

A single serum measurement of the β -hCG concentration, however, cannot identify the location of the gestation sac. If a low serum β -hCG level (< 1000 IU/L) is associated with a higher relative risk of ectopic pregnancy, then can very low levels predict a benign clinical course? A single serum β -hCG measurement cannot exclude ectopic pregnancy or predict the risk of rupture unless it is less than 5 IU/L.¹⁴

In a normal pregnancy, the first trimester β -hCG concentration rapidly increases, doubling about every 2 days. An increase over 48 hours of at least 66% has been used as a cutoff point for viability.¹⁵ Ectopic pregnancy may present with rising, falling or plateau β -hCG levels; thus, serial measurement is most useful to confirm fetal viability rather than to identify ectopic pregnancy.

3. Use of Progesterone Measurement

Measurement of the serum concentration of progesterone has been investigated as a potentially useful adjunct to serum β -hCG measurement, since progesterone levels are stable and independent of gestational age in the first trimester. A Meta analysis, published in 1998, of studies assessing a single progesterone level demonstrated good capacity of low levels (≤ 5 ng/mL) to correctly diagnose pregnancy failure, but this cutoff was unable to discriminate between ectopic pregnancy and intrauterine pregnancy. Both high (≥ 22 ng/mL) and low (≤ 5 ng/mL) cutoff points have since been studied for their ability to correctly identify nonviable pregnancy and ectopic pregnancy.^{16, 17} Invasive diagnostic testing (e.g. D and C) could be postponed in the former patients but offered to the latter, as could treatment with methotrexate, without fear of interrupting a potentially viable intrauterine pregnancy.

4. Ultrasound Imaging

A β -hCG level that has risen above the discriminatory threshold in the absence of sonographic signs of early pregnancy is

considered presumptive evidence of an ectopic pregnancy. With the evolution in ultrasound technology, the discriminatory threshold has dropped from 6500 IU/L with a transabdominal approach to between 1000 and 2000 IU/L with transvaginal imaging.¹⁸ The spectrum of sonographic findings in ectopic pregnancy is broad. Identification of an extrauterine gestational sac containing a yolk sac (with or without an embryo) confirms the diagnosis. Suggestive findings include an empty uterus, cystic or solid adnexal or tubal masses (including the tubal-ring sign, representing a tubal gestational sac), hematosalpinx and echogenic or sonolucent cul-de-sac fluid. It is therefore found that the proportion of patients with the tubal rupture, heavy intra-abdominal bleed and pre-shock/shock have decreased owing to early diagnosis.

Thorough physical and clinical examination with preanesthetic checkup was performed. Surgical intervention was done under general anesthesia, on an in-patients basis.

Four different operative techniques were used:

1. Laparoscopic linear salpingiotomy (tubal aspiration)
2. Laparoscopic salpingectomy
3. Laparoscopic fimbrial expression
4. Laparotomy

Laparoscopic Linear Salpingiotomy

Used as method of choice in patients with unruptured ampullary pregnancy. A linear incision was made over antimesenteric border of tubal segment containing pregnancy with point needle monopolar diathermy. Prior injection of 5-8 ml of diluted solution containing 5 units of vasopressin in 20 ml normal saline is made with 20 gauge spinal needle into the mesosalpinx. Product of conception extrudes itself, if not this can be completed by using hydrodessection or gentle traction with laparoscopic forceps. Copious irrigation is used to dislodge trophoblast. The opening of fallopian tube was left to heal by secondary intention.

Laparoscopic Salpingectomy

This method is chosen for treatment of isthmic pregnancy, with tubal distention, hydrosalpinx, recurrent ectopic in the same tube, severe adhesions or patients choice. This procedure involves resection of segment of tube containing pregnancy in several ways including laser, stapling devices, endoloops, or progressive bipolar coagulation and cutting the mesosalpinx begins at proximal isthmus of tube, progressed to fimbriated end.

Laparoscopic Fimbrial Expression

Milking of the tube was done for the patients with fimbrial ectopic pregnancy. Trophoblastic tissue either sucked out by suction, or retrieved through 10 mm ports and sent for histopathological examination.

Laparotomy

Laparotomy was performed through a pfannenstiel incision and standard surgical techniques (the same laparoscopic techniques) were applied.

Postoperative follow-up consists of serial hCG assessment (twice weekly) until complete negativity (< 5IU/L), with weekly clinical examination and transvaginal ultrasound if needed.

Postoperative management follows the normal practice. Analgesia was prescribed to the patients on demand, namely pethidine, 1.5 ml/kg IM every 4 four hours or diclofenac sodium 100mg.

DISCUSSION

A large number of studies on the management of ectopic pregnancy can be found in the literature, ranging from case report to randomized trial, from expectant management to radical surgery. It is now accepted that the surgical treatment of ectopic pregnancy should be via laparoscopy except for a few exception (contraindication for laparoscopy, state of hemodynamic shock, surgeon with insufficient experience).

Success Rate – K Clasen et al (1997) had strict laparoscopic approach to 194 cases of ectopic pregnancy resulting in a 97.4% success rate.²⁵ Other series of studies also confirm the success rate of operative laparoscopic surgery in ectopic pregnancy between 87-97%.²⁶⁻³⁰

Some authors had performed operative laparoscopic even in hemodynamically unstable patients with good success rate.⁹

Operative Time

Lundorff P et al 1991 conducted a randomized, prospective clinical trial was conducted to comparing the efficacy of laparoscopic treatment with conventional conservative abdominal surgery for tubal pregnancy. Laparoscopic surgery took less time (73 min) versus 88 min for laparotomy group.²⁴ In fact, it actually saves time, as during a laparotomy, opening and closing the abdomen just to gain access to the affected tube consumes precious operating time. Other comparative studies support this fact.^{22,26,27}

Peri- or Postoperative Complication

Chatwani A et al in non-randomized study found statically significant decrease in operative blood transfusion rate in laparoscopic group. Another review article by Mohammed H. (2002) suggested that there was no major difference in intraoperative or postoperative complications in laparoscopic group and laparotomy group.^{20, 21}

Hospital Stay

Various randomized control trial comparing laparoscopic surgery versus laparotomy in treatment of ectopic pregnancy showed shorter hospital stay and convalescence period.^{22, 24}

Fertility Outcome

Concern fertility restoration and pregnancy outcome following conservative or radical approach by minimal access surgery proved no significant difference when compared with open surgery. Overall conception rate of 77.3%, with an ongoing pregnancy rate 81.2% have been reported.^{30, 31}

Cost Effectiveness

In this current era of minimal access surgery the cost of endoscopic/laparoscopic set up is much high and need specialized theater set up, more staff and maintenance. But owing to reduce hospital stay, faster recovery time, the expenditure can be considered cost effective.^{22, 23}

Quality of Life Analysis

Minimal access surgery as an operative choice for management of life-threatening condition like ectopic pregnancy lead to increased quality of life in term of shorter hospital stay, speedy postoperative recovery, reduce need of postoperative analgesia, cosmetically good scar and less psychological trauma to the patients.

CONCLUSION

Critical overview of literature of all possible approach demonstrate that the minimally access surgery is not only safe and effective, but also economical then open laparotomy in the treatment of ectopic pregnancy and should consider as the gold standard in treating in ectopic pregnancy.

REFERENCES

1. Lehner R, Kucera E, Jirecek S, Egarter C, Husslein P, Ectopic pregnancy. Arch Gynecol Obstet 2000 Feb; 263(3): 87-92.
2. Centres for diseases control (CDC). Ectopic pregnancy—United States, 1988-1989. MMWR 1992; 41:591-94.
3. Centres for disease contral (CDC). Ectopic pregnancy—United States, 1990-1992. MMWR 1995; 44:46-48.
4. Why women die. Report on condidential enquiries into maternal deaths in the United Kingdom 1994-1996. Norwich: Stationery Office, 1998.
5. Leach RE, Ory SJ. Management of ectopic pregnancy. Am Fam Physician 1990; 41: 1215-22.
6. Ory SJ. New options for diagnosis and treatment of ectopic pregnancy. JAMA 1992; 267:534-37.

7. Feng W, CAO B, Li Q. Advances in diagnosis and treatment of ectopic pregnancy during the past ten years. *Zhonghu Fu Chan Ke Za Zhi* 2000 Jul;35(7): 408-10.
8. Tay JI, Moore J, Walker JJ. Ectopic pregnancy: Clinical review *BMJ* 2000; 320(1):916-19.
9. Soriano D, Yefet Y, Oelsner G, Goldenberg M, Mashiach Seidman DS. Operative laparoscopy for management of ectopic pregnancy in patients with hypovolemic shock. *J Am Assoc Gynecol Laparosc.* 1997 May;4(3):363-67.
10. Murphy AA, Nager CW, Wujek JJ, Kettel LM, Torp VA, chin HG. Operative laparoscopy versus laparotomy for the management of ectopic pregnancy: a prospective trial. *Fertil Steril* 1992; 57:1180-85.
11. Buckley RG, King KH, Disney JD, Gorman JD, Klasen JH. History and physical examination to estimate the risk of ectopic pregnancy: validation of a clinical prediction model. *Ann Emerg Med* 1999;34: 589-94.
12. Dart RG, Kaplan B, Varaklis K. Predictive value of history and physical examination in patients with suspected ectopic pregnancy. *Ann Emerg Med* 1999;33: 283-90.
13. Brennam DF. Ectopic pregnancy- Part I: Clinical and laboratory diagnosis. *Acad Emerg Med* 1995;2: 1081-89.
14. Kaplan BC, Dart RG, Moskos M, Kuligowska E, Chun B, Adel Hamid M, et al. Ectopic pregnancy: prospective study with improved diagnostic accuracy. *Ann Emerg Med* 1996; 28: 10-7. Comment in *Ann Emerg Med* 1997;29:295-96.
15. Dart RG, Mitterando J, Dart LM. Rate of change of serial beta-human chorionic gonadotropin values as a predictor of ectopic pregnancy in patients with indeterminate transvaginal ultrasound findings. *Ann Emerg Med* 1999;34: 703-10.
16. Buckley RG, King KJ, Disney JD, Riffenburgh RH, Gorman JD, Klausen JH. Serum Progesterone testing to predict ectopic pregnancy in symptomatic first-trimester patients. *Ann Emerg Med* 2000; 36:95-100.
17. Dart R, Ramanujam P, Dart L. Progesterone as a predictor of ectopic pregnancy when the ultrasound is indeterminate. *Am J Emerg Med* 2002, 20:575-9.
18. Kadar N, De Vore G, Romero R, Discriminatory hCG Zone: its use in the sonographic evaluation for ectopic pregnancy. *Obstet Gynecol* 1981;58: 156-61.
19. Nama V, Manyonda I. Tubal ectopic pregnancy: laparoscopic and management. *Arch Gynecol Obstet.* 2008 Jul 30.
20. Henderson SR. Ectopic tubal pregnancy treated by operative laparoscopy. *Am J Obstet Gynecol.* 1990 May; 162(5): 1348.
21. Reich H, Freifeld MI, McGlynn F, Reich E. laparoscopic treatment of tubal pregnancy. *Obstet Gynecol.* 1987 Feb;69(2): 275-79.
22. Chatwani A, Yazigi R, Amin-Hanjani S., Operative laparoscopy in the management of tubal ectopic pregnancy. *J Laparoendosc Surg* 1992 Dec;2(6): 319-24.
23. Fujishita A, Khan KN, Kitajima M, Hiraki K, Miura S, Ihimaru T, Masuzaki H. Re-evaluation of the indication for and limitation of laparoscopic salpingotomy for tubal pregnancy. *Eur J Obstet Gynecol Reprod Biol* 2008.
24. Steiner RA, Ioannidis K, Wight E, Fehr M, Haller U. Minimally invasive surgery in the treatment of extrauterine pregnancy. *Schweiz Rundsch Med Prax* 1993.
25. Clasen K, Camus M, Tournaye H, Devroey P. Ectopic pregnancy: let's cut! Strict laparoscopic approach to 194 consecutive cases and review of literature on alternatives. *Human reproduction* 1997;12(3):596-601.
26. Chapron C, Querleu D, Crepin G. Laparoscopic treatment of ectopic pregnancies: a one hundred cases study. *Eur J Obstet Gynecol Reprod Biol* 1991 Oct 8; 41(3): 187-90.
27. Zouves C, Urman B, Gomel V. Laparoscopic surgical treatment of tubal pregnancy. A safe, effective alternative to laparotomy. *J Reprod Med* 1992 Mar; 37(3): 205-09.
28. Mohamed H, Maiti S, Phillips G. Laparoscopic management of ectopic pregnancy: a 5-year experience. *J Obstet Gynaecol* 2002; Jul; 22(4): 411-14.
29. Aharoni, A, Gyuo, B. and Salat-Baroux, J. Operative laparoscopy for ectopic pregnancy: how experienced should the surgeon be? *Hum. Reprod* 1993;8:2227-30.
30. Jean Bernard Dubuission, Philippe Morice, Charles Chaperon, Antoine De Gayffier, Tarak Mouelhi, Salpingectomy- the laparoscopic surgical choice for ectopic pregnancy. *Human reproduction* 11(6):1199-1203.
31. Martin Vivaldi, R, Nogueras, F, Garcia Montero, M. et al. Emergency laparoscopy. A 20 year experience. *Rev Esp. Enferm Dig.* 1995;87:305-08.
32. Bangsgaard N, Lund CO, Ottesen B, Nilas L. Improved fertility following conservative surgical treatment of ectopic pregnancy. *BJOG* 2003; 110: 765-70.
33. Dubuission JB, Morice P, Chapron C, De Gayffier A, Mouelhi T. Salpingectomy – the laparoscopic surgical choice for ectopic pregnancy. *Hum Reprod* 1996;11:1199-203.
34. Lunderoff P, Thorburn J, Hahlim M, Kallfelt B, Lindblom B. Laparoscopic surgery in ectopic pregnancy. A randomized trial versus laparotomy. *Acta Obstet Gynecol Scand.* 1991;70 (4-5):343-48.