

Laparoscopic Adrenalectomy: Surgical Technique

Thawatchai Tullavardhana

Department of Surgery, Faculty of Medicine, Srinakarinwirot University, Thailand

Abstract

Laparoscopic adrenalectomy was first described in 1992 by Gagner *et al.* In present, this minimally invasive procedure are become “gold standard” surgical management of small and medium sized benign adrenal tumor. This review article aims to describe various type of surgical technique to perform laparoscopic adrenalectomy including new minimally invasive technique as single access laparoscopic adrenalectomy, role of natural orifice transluminal endoscopic surgery (NOTES) in adrenalectomy to complete gland dissection, method of patients selection (indication, contraindication) and show benefits of laparoscopic adrenalectomy compare with conventional open surgery technique.

Keywords: Adrenal gland, laparoscopic surgery, surgical technique, adrenalectomy.

INTRODUCTION

Laparoscopic adrenalectomy was first described in 1992 by Gagner *et al.* In present this minimally invasive procedure are become “gold standard” surgical management of Cushing’s syndrome, pheochromocytoma, aldosteronoma, and adrenal incidentaloma. Benefit outcome of laparoscopic adrenalectomy are less postoperative pain, decrease postoperative morbidity, decreased hospital stay and allow patients to recover faster, more overall patient satisfaction when compared with an open approach.¹

AIMS

The aim of this study was to describe various type of surgical technique to perform laparoscopic adrenalectomy including new minimally invasive technique as single access laparoscopic adrenalectomy, role of natural orifice transluminal endoscopic surgery (NOTE) in adrenalectomy. The following parameters were evaluated for this laparoscopic and procedures.

- Method of patient selection
 - Investigation
 - Indication for surgery
 - Contraindication for surgery
- Preoperative preparation
- Operative technique
 - Type of anesthesia
 - Patient position
 - Operative approach
 - Comparison outcome of various surgical technique
- Intraoperative and postoperative complications
- Postoperative care

- Postoperative recovery
- Benefit outcome compare with open surgery.

MATERIALS AND METHODS

A literature review was performed using Google, MD consult, PubMed. The following search terms were used: laparoscopic adrenalectomy, surgical technique, laparoscopic vs open adrenalectomy, complication of laparoscopic adrenalectomy. Criteria for selection of literature were the methods of analysis (statistical or non-statistical), operative procedure (various type of laparoscopic adrenalectomy technique) and comparison of various surgical technique (operative time, blood loss, complication).

Method of Patient Selection

All of patients present with adrenal lesion should be evaluated for:

1. *Biochemical hormonal activity:* The aim of this test is to determine functional activity of adrenal lesion, such as plasma and urine catecholamines for pheochromocytoma and 24 hours urine cortisol for Cushing’s syndrome. That is important in perioperative care including blood pressure control, fluid and electrolyte status and other anesthesia considerations.
2. *Imaging study:* CT scan is the preferred radiologic modality, Finding on CT scan that suggest benign adrenal lesion include homogenous round shape, size—smaller than 3 cm, smooth, well-circumscribed border and attenuation coefficients less than 10 Hounsfield’s units. Potential adrenal malignancy lesion are finding on CT scan as size larger than 5 cm, presence of central

necrosis, tumor calcification, evidence of nodal, hepatic, venous invasion.^{2,3}

Indication for Surgery

All of hormonal active adrenal tumor and nonfunctional size, more than 4 cm, or rapid increase in size adrenal tumor should be removed. Laparoscopic adrenalectomy is a surgical option but should be carefully in large adrenal masses (8 cm or greater) that may associated with significant longer operative time, increased blood loss, and longer hospital stay. Indication for laparoscopic adrenalectomy is given in Table 1.³⁻⁶

Table 1: Indication for laparoscopic adrenalectomy³

<ul style="list-style-type: none"> • Hormonally active adrenal tumor • Aldosteronoma • Pheochromocytoma • Cortisol-producing adrenal tumor • Nonfunctioning adrenal lesion greater than 5 cm in size • Nonfunctioning adrenal lesion with progressive growth • Solitary adrenal metastasis with negative metastatic survey

Contraindication

Laparoscopic adrenalectomy has few absolute contraindications as suspected primary adrenal carcinoma that shown aggressive activity as adjacent organ invasion should be *en bloc* resection with open surgery. Other of absolute contraindication are severe cardiopulmonary disease, uncontrolled pheochromocytoma and uncorrectable coagulopathy. Relative contraindications are including extensive previous surgery and tumor size more than 12 cm that may increase risk of bleeding and visceral organ injury.³⁻⁵

Preoperative Preparation

All of patients with hormonal active adrenal tumors should be carefully preoperative evaluated in blood pressure control, fluid and electrolyte management. Collaboration between surgeon, endocrinologist, and anesthesiologist are still necessary. Other preoperative preparations include mechanical bowel preparation, broad-spectrum antibiotic prophylaxis, and deep vein thrombosis prophylaxis.³⁻⁵

Operative Technique

There are many surgical approaches to performed laparoscopic adrenalectomy. Including transperitoneal approach and lateral retroperitoneal approach, transthoracic

approach, single incision laparoscopic adrenalectomy, NOTES adrenalectomy will be described.

This procedure was performed under general anesthesia. Routine placement of nasogastric tube and urinary catheter are still requiring.

TRANSPERITONEAL APPROACH

Left Adrenalectomy^{3-5,7}

Patient position: Lateral decubitus position with the left side up, operative table slightly flexed at the level of the umbilicus and the surgeon and assistant were standing on the side opposite to the lesion.

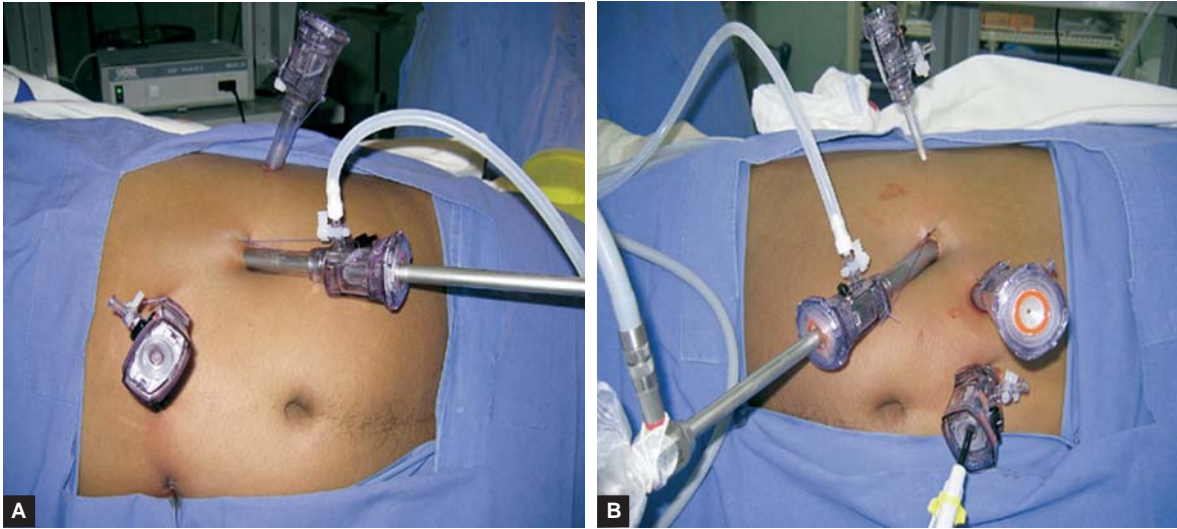
Port site placement: Insertion of Veress needle at 3 cm under costal margin at the anterior axillary line then insufflations of carbon dioxide up to 15 mm Hg. Then 10 mm trocar replaced the Veress needle for a 30 degree 10 mm laparoscope. A second 10 mm trocar on the posterior axillary line, and a third 5 mm trocar on the midclavicular line.

Operative Approach^{3-5,7,8}

1. Mobilization of splenic flexure colon by divide splenocolic ligament, leinorenal ligament and dissection of splenorenal ligament, lateral peritoneal carried up to the diaphragm to provide adequate exposure of left adrenal gland. Ultrasonic laparoscopic coagulation instrument or bipolar cautery can be use during mobilization of adrenal gland.
2. Dissection of Gerota's fascia between upper pole of left kidney and adrenal gland. Continue dissection to medial aspect of kidney for identified of left renal vein.
3. Meticulous dissection was performed for isolation of left adrenal vein then clipped and divided. Mobilizations of medial part of adrenal gland out off of the aorta. All small blood vessels were either clipped or cauterized. Then continues to superior aspects of the adrenal gland. Carefully divide the phrenic vessels at this level, avoid injury to pancreatic tail. The lateral part was mobilized to free adrenal gland from surrounding tissue.
4. Adrenal gland was extracted in a sterile plastic bag through the most anterior trocar. Complete hemostasis checking and suture skin incision. Routine drainage is not necessary.

Right Adrenalectomy

Patient position: Lateral decubitus position with the right side up, operative table slightly flexed at the level of the umbilicus and the surgeon and assistant were standing on the side opposite to the lesion.



Figs 1A and B: Port site placement for laparoscopic (A) left adrenalectomy, and (B) right adrenalectomy

Port site placement: Similar as describe for left adrenalectomy but adding 5 mm port at epigastrium for liver retractor insertion (Figs 1A and B).

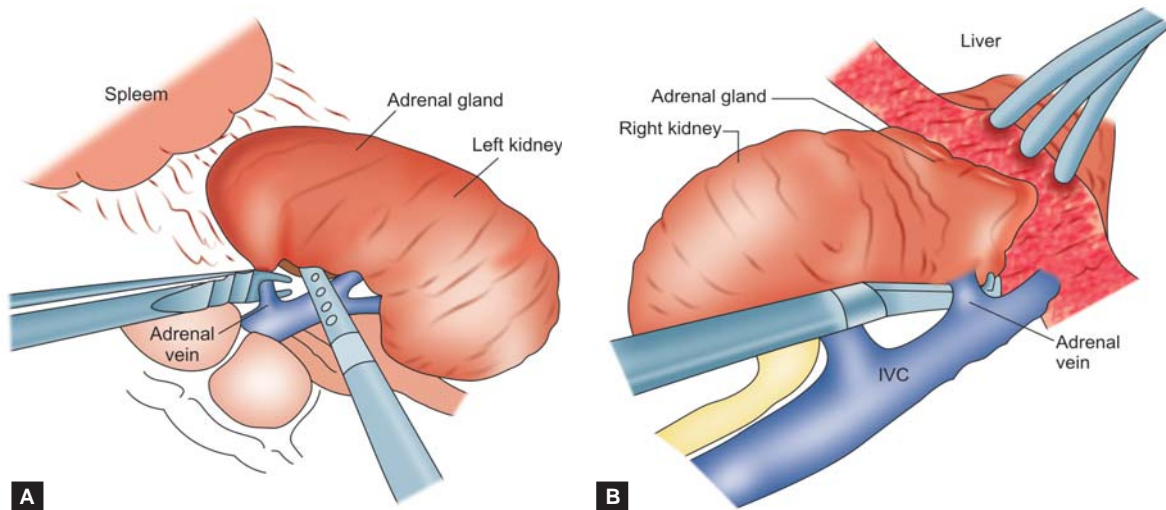
Operative Approach^{3-5,7,8}

1. Mobilization of Toldt’s line through triangular ligament for upward liver retraction. Then mobilization of duodenum to exposure of right kidney, right adrenal gland and inferior vena cava (IVC).
2. Dissection was done medially and upward along IVC for identified right adrenal vein then clipped and divided (Figs 2A and B). This step should be done carefully, avoid massive bleeding from IVC.

3. Continue dissection of adrenal gland as describe in left adrenalectomy. Adrenal gland was extracted in a sterile plastic bag, complete checking for hemostasis and suture skin incision.

Lateral Retroperitoneal Approach

The lateral retroperitoneal approach to the adrenal gland is providing benefit in case of prior extensive abdominal surgery to avoid visceral organ injury. Limitation of this surgical technique in case of adrenal tumor size larger than 7 cm that may lack of anatomical landmark in retroperitoneal space. *Patient position:* Full flank position with slightly flexed operative table for expands the operative space between the



Figs 2A and B: Port side placement for laparoscopic dissection of (A) left adrenal vein, and (B) right adrenal vein

costal margin and the iliac crest (Figs 3A and B). This position is most widely used because it permits proper bowel mobilization and makes exposure of the surgical area.

Retroperitoneal space access: Open Hasson's technique by made 2 cm skin incision is at 2 cm below the inferior edge of the twelfth rib then split the muscles until the lumbodorsal fascia was divided by blunt dissection then enter to retroperitoneal space. Retroperitoneal requires the creation of a working space using a balloon dilatation (800 cc of air inflated to balloon).

Port site placement: After dilatation, 10 mm trocar was inserted for 30 degree 10 mm laparoscope, then insufflations of carbon dioxide to generate pneumoretroperitoneum pressure of 15 mm Hg. A second trocar is placed in the anterior axillary line midway between the costal margin and iliac crest. A third port is placed posteriorly between the twelfth rib and iliac crest along the lateral border of the sacrospinalis muscle. A fourth port (5 mm) is inserted for retraction of the kidney and is placed cephalad to the first port in the anterior axillary line. An optional fourth port is placed in the anterior axillary line 5 to 7 cm inferior to the third port and may be used for retraction during dissection of adrenal gland.

Operative Approach^{3-5,7}

Important key anatomical landmark of this surgical approach is psoas muscle. The kidney and adrenal gland locate on lateral border.

Left Adrenalectomy

1. Dissection along lateral border of psoas muscle to medial border left kidney, then retract kidney upward and anteriorly.
2. Carefully dissection of renal hilum to identified left renal vein and medial border of adrenal gland.

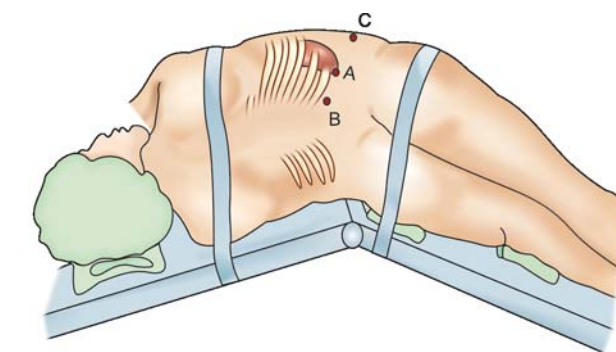
3. Left adrenal vein are located at inferomedial of adrenal gland in conjunction with left renal vein. Identification of left adrenal vein at this level then clipped and divided.
4. Continue mobilization thought lateral and inferior surfaces of adrenal gland and carefully dissected away from the kidney. Then superior aspect and inferior phrenic vessels are controlled with ultrasonic laparoscopic coagulation instrument or bipolar cautery.
5. Adrenal gland was extracted in a sterile plastic bag and extracted from primary port. The trocars were removed and suture skin incision.

Right Adrenalectomy

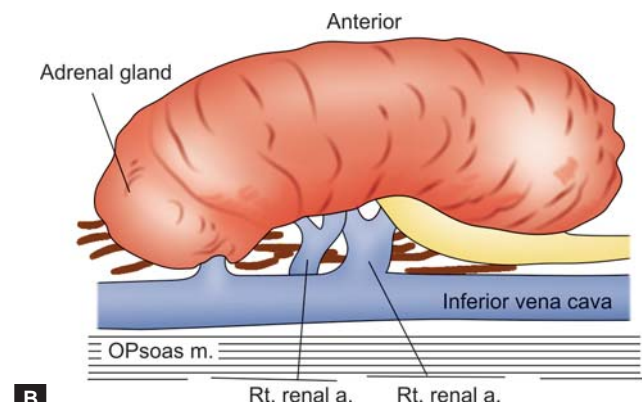
1. Dissection of right adrenal gland is the same principle of left adrenal gland dissection. Psoas muscle is the important key anatomical landmark.
2. After identification of right kidney and right adrenal gland. Carefully dissection of IVC that is located at medial part of psoas muscle.
3. Right adrenal vein was identified in conjunction of IVC the clipped and divided. Avoiding of avulsion injury that may be causing massive hemorrhage.
4. After completion of adrenal gland dissection, specimen was extracted in a sterile plastic bag and extracted from primary port. The trocars were removed and suture skin incision.

Posterior Retroperitoneal Approach

This technique was initially reported in 1999 by Walz et al. The patient is placed on a lateral flank technique and creation of working space by balloon dilatation as described in lateral retroperitoneal approach. A three- to four-port was used for camera and working instruments. Initial dissection was performed at superior of adrenal gland continue thought



A



B

Figs 3A and B: Patient position with port site placement for lateral retroperitoneal right adrenalectomy and important anatomical landmark³

medial surface of adrenal gland the adrenal vessels is exposed and ligation. After complete dissection of the gland then placed into a specimen retrieval bag and removed. This surgical approach is not popular option because need more surgical experience and limitation of working space.^{3,7}

Rubinstin et al report a comparison of perioperative outcome between transperitoneal approach and lateral retroperitoneal approach in 57 consecutive benign adrenal conditions. Finding that both surgical techniques are safe. There are not different in operative time (130 vs 126.5 minutes), blood loss, postoperative pain, length of hospital stay and postoperative complication.⁹

Zusuki et al report clinical outcomes of the transperitoneal, lateral transperitoneal and lateral retroperitoneal approach. This article conclusion is—(1) Lateral transperitoneal approach is proper for a tumor is more than 5 cm and/or the surgeon is not yet skilled in laparoscopic adrenalectomy (2) Lateral retroperitoneal approach is suitable, if the surgeon has performed at least 20 operations, the adrenal tumor is unilateral and the lesion is less than 5 cm.¹⁰

Transthoracic Approach

Gill et al report “Thoracoscopic transdiaphragmatic adrenalectomy” in 3 patients with prior history of extensive abdominal surgery. This technique was performed after double lumen endotracheal intubation without pneumo-insufflation and the patient is placed in the prone position. Four port transthoracic approaches were used. The diaphragm was incised under thoracoscope vision, and then enters to retroperitoneal space to identification of adrenal gland. Adrenal vasculature was controlled and complete mobilization of adrenal gland. The specimen was entrapped

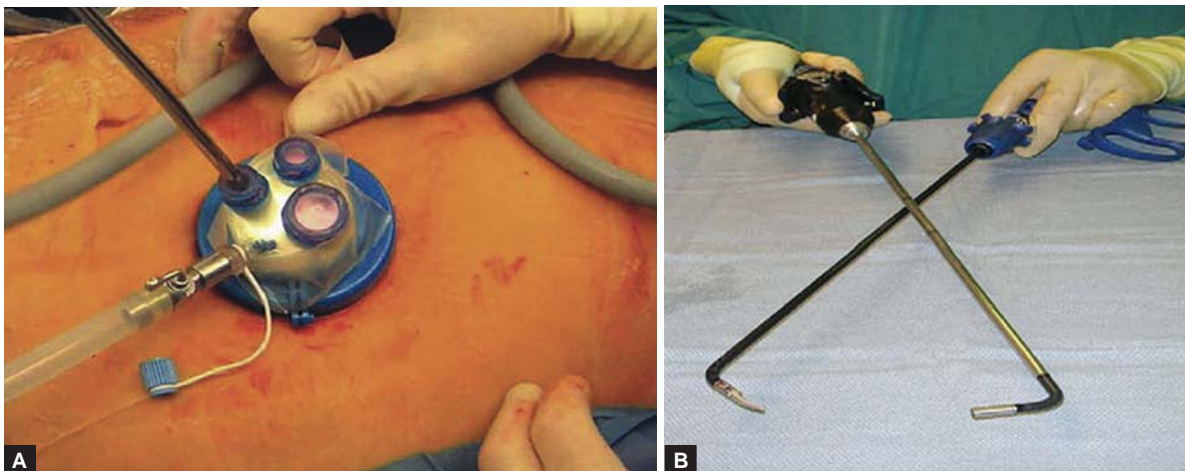
and retrieved through a thoracic port. The diaphragm was suture repaired with intracorporeal knot tying and chest tube was placed. The outcomes are—(1) No perioperative complications (2) Operating time was 2.5 to 6.5 hours (3) Blood loss was 50 to 500 cc.¹¹

Single Access Retroperitoneal Adrenalectomy

Single access laparoscopic surgery is becomes a new trend in minimally invasive surgery. This surgical access is need articulating or bent instrumentation insert to adjacent trocar in same incision to allow triangulation intracorporeally during surgery (Figs 4A and B). Now development of new laparoscopic access ports allowing several instruments to be inserted through different cannulae of a single port.^{12,13}

Hirano et al report technique of single incision retroperitoneoscopic adrenalectomy. The patient was placed in lateral decubitus position with slight flexion. A 4.5 cm skin incision was performed below the twelfth rib in the midaxillary line. Balloon dilataion combined with finger dissection were used to create working space in retroperitoneal. A rectoscope tube, 4 cm diameter, was inserted for camera and working instrument to perform adrenalectomy port without carbon dioxide insufflations. This operation was successful in 98.1%. The average duration of surgery was 203 minutes, and the mean estimated blood loss was 252 cc. Postoperative major complications, including fulminant hepatitis and pulmonary thrombosis, were observed in two patients (3.7%).¹⁴

Walz et al report outcome of single-access retroperitoneoscopic adrenalectomy (SARA) in 47 patients with benign adrenal tumor. SARA results are need long operative time, decrease postoperative pain when compare with traditional retroperitoneoscopic three-port approach.



Figs 4A and B: Single port with three working channel and articulated instrument for single access laparoscopic surgery¹³

But overall complication and length of hospital stay are not different.¹⁵

Natural Orifice Transluminal Endoscopic Surgery (NOTES) for Adrenalectomy

The concept of NOTES is “incisionless surgery”. This technique access by transgastric or, transvagina or transcolonic approach to access peritoneal cavity. That can allows perform intra-abdominal surgery without surgical scar.

In present role of NOTES for adrenalectomy are only reports in many porcine or cadaveric models. Transvaginal retroperitoneal adrenalectomy in porcine model is performing by made a 1 cm posterolateral colpotomy. The retroperitoneal tunnel was created using carbon dioxide. Dissection by movement of gastroscope up to superior pole of kidney to allowed access of adrenal gland. The vascular pedicle was identified and controlled by clips or endoloop. NOTES transvaginal retroperitoneal may be option for humans in future. But further experiments and better practice surgical skill are needed.^{16,17}

Bilateral Adrenalectomy

The most common indication for bilateral adrenalectomy is Cushing’s syndrome. This procedure was performed by lateral transperitoneal approach. The larger tumor or the more difficult side should be performed first, then change patient position to opposite side and redraped.^{3,7}

Mikhail et al report comparison of outcome between laparoscopic bilateral adrenalectomy with open surgery. The results of laparoscopic procedure are—(1) Need more operative time (295.2 vs 236.8 minutes) (2) Less intraoperative blood loss (100 vs 500 cc.) (3) Short hospital stay in laparoscopic surgery group (3 vs 8.5 days).¹⁸

Complication of Laparoscopic Adrenalectomy

Intraoperative complication

1. **Hemorrhage:** Adrenal vein are directly into IVC on the right side and directly to left renal vein on the left. If avulsion injury occur during dissection of adrenal vein may be cause of massive hemorrhage. Prevention of this complication by meticulous dissection of adrenal vein.
2. **Adjacent organ injury**
 - **Liver:** Liver laceration of liver retractor may be cause of bleeding. This condition can be managed by argon plasma coagulation and hemostasis agent (such as methyl cellulose).

- **Spleen:** Splenic injury occurs during left adrenalectomy. This condition can be managed by argon plasma coagulation and hemostasis agent. If this is not control bleeding, splenorrhaphy or splenectomy may be necessary.
- **Pancreas:** If pancreatic injury occurs at tail of pancreas, distal pancreatectomy is a surgical option. If there is uncertainty of pancreatic injury management by leaving of closed suction drainage and total parenteral nutrition.
- **Visceral organ:** Small bowel, colonic injury may occur during laparoscopic adrenalectomy. If this complication cannot repair by laparoscopic procedure, conversion to open surgery may be an option.

Postoperative Complication

1. Hypokalemia can occur in the immediate period after adrenalectomy in patient with primary hypoaldosteronism. Potassium replacement is requiring if this condition still persistent replacement of mineralocorticoid with fludrocortisone is essential.
2. Hypotension secondary to α blockade can occur after adrenalectomy in case of pheochromocytoma. Close monitoring of blood pressure in postoperative period still necessary.
3. Complication after prolong steroid supplement after adrenalectomy such as increased risk of fracture secondary to osteoporosis, hyperglycemia, and poor wound healing.

During learning period of laparoscopic adrenalectomy, surgeon should select a case of unilateral, small adenomas without comorbid disease to avoid perioperative complication.¹⁹

Postoperative Care

After completion of operation nasogastric was removed. Carefully monitoring of blood pressure, fluid-electrolyte balance as mentioned in postoperative complication. Oral intake can start on first operative day and take off urinary catheter. Postoperative pain is control by parenteral narcotics in the first 24 hours. Then oral analgesic drug start after first operative day. If the patient was uneventfully, they can discharge from hospital within 48 hours after surgery. Recovery time of patient is about 10 to 14 days after surgery.

Benefit Outcome Compare with Open Surgery

In present, many of literature showing benefits outcome of laparoscopic adrenalectomy above conventional open surgery, include decrease blood loss during surgery,

Table 2: Comparison outcome between laparoscopic adrenalectomy and open surgery²⁰

	Open group (n = 35)	Laparoscopic group (n = 5)	P value
Mean operation time (min)	154 (38)	175 (66)	NS
Mean blood loss (mL)	270 (181)	78 (108)	< 0.0001
Mean specimen size (mm)	28 (15)	31 (14)	NS
Postoperative length of hospital stays (days)	26 (17)	12 (6)	0.004
Petients with SIRS (%)	18 (51.4)	11 (31.4)	NS
Mean duration of SIRS (days)	1.9 (1.0)	1.2 (0.4)	0.04
Letest postoperative day SIRS diagnosed	1.9 (2.6)	0.7 (1.3)	NS

Note: NS—not statistically significant; SIRS—systemic inflammatory response syndrome; Data in parentheses are standard deviations, unless otherwise noted.

decrease postoperative pain, shorter length of hospital stay (Table 2). This is causing laparoscopic adrenalectomy become a “gold standard” for surgical management of benign adrenal lesions.^{20,21}

CONCLUSION

Laparoscopic adrenalectomy is a safe and effective surgical technique for management for adrenal lesions. This minimally invasive approach is providing benefit over open surgery. Adequate patient selection with meticulous surgical technique is a key to good patient outcome.

REFERENCES

- Melman L, Matthews BD. Current trends in laparoscopic solid organ surgery: Spleen, adrenal, pancreas, and liver. *Surg Clin North Am* 2008;88(5):1033-46.
- Lin DD, Loughlin KR. Diagnosis and management of surgical adrenal diseases. *Urology* 2005;66(3):476-83.
- Wang DS, Terashi T. Laparoscopic adrenalectomy. *Urol Clin North Am* 2008;35(3):351-63.
- Chelouche D, Sagie B, Keidar A. Laparoscopic adrenalectomy, indications, technique, complications and follow-up. *IMAJ* 2003; (5):101-04.
- G Guazzani, A Ceataei, F Montrisi. Laparoscopic treatment of adrenal diseases: 10 years on. *BJU International* 2004;9(3): 221-27.
- Castillo O, Vitagliano G, Fernando P. Laparoscopic adrenalectomy for adrenal masses: Does size matter. *Urology* 2008; (71):1138-41.
- Mellon J, Sethi A, Sundaram C. Laparoscopic adrenalectomy: Surgical techniques. *Urol* 2008;(24):583-89.
- Kai rys J. Anterior (transabdominal) laparoscopic adrenalectomy. *Operative techniques in general surgery* 2007;9(3):104-12.
- Rubinstein M, Gill IS, Aron M. Prospective, randomized comparison of transperitoneal versus retroperitoneal laparoscopic adrenalectomy. *J Urol* 2005;174(2):442-45.
- Suzuki K, Kageyama S, Hiranao Y. Comparison in three surgical approaches to laparoscopic adrenalectomy: A nonrandomized background match analysis. *J Urol* 2001;166(2):443-38.
- Gill IS, Meraney AM, Thomas J AC. Thoracoscopic transdiaphragmatic adrenalectomy: The initial experience. *J Urol* 2001;165(6 Pt 1):1875-81.
- Raman J, Cadeddu J, Rao P. Single-incision laparoscopic surgery: Initial urological experience and comparison with natural-orifice transluminal endoscopic surgery. *B J U International* 2008; 101:1493-96.
- Irwin B, Rao P, Stein R. Laparoendoscopic Single Site Surgery in Urology. *Urol Clin N Am* 2009;36:223-35.
- Hirano D, Minei S, Yamaguchi K. Retroperitoneoscopic adrenalectomy for adrenal tumors via a single Large Port Journal of Endourology. 2005;19(7):788-92.
- Walz MK, Groeben H, Alesina PF. Single-Access Retroperitoneoscopic adrenalectomy (SARA) Versus Conventional Retroperitoneoscopic Adrenalectomy (CORA): A Case-Control Study. *World J Surg* 2010;6.
- Silvana P, Pierre A, Mitsuhiro A. Adrenalectomy using natural orifice transluminal endoscopic surgery (NOTES): A transvaginal retroperitoneal approach. *Surg Oncol* 2009;18(2):131-37.
- Zacharopoulou C, Nassif J, Allemann P. Exploration of the retroperitoneum using the transvaginal natural orifice transluminal endoscopic surgery technique. *J Minim Invasive Gynecol* 2009; 16(2):198-203.
- Mikhail AA, Tolhurst SR, Orvieto MA. Open versus laparoscopic simultaneous bilateral adrenalectomy. *Urology* 2006;67:693-96.
- Chan J, Meneghetti A, Meloche R. Prospective comparison of early and late experience with laparoscopic adrenalectomy. *The American Journal of Surgery* 191(2006):682-68.
- Mutoh M, Takeyama K, Nishiyama N. Systemic inflammatory response syndrome in open versus laparoscopic adrenalectomy. *Urology* 2004;64(3):422-25.
- Kwan TL, Lam CM, Yuen AW, Lo CY. Adrenalectomy in Hong Kong: A critical review of adoption of laparoscopic approach. *Am J Surg* 2007;194(2):153-58.