

Hysteroscopic Sterilization

Bharathi Rajanna

Consultant, Department of Gynecology and Laparoscopy Surgery, Kempanna Nursing Home, Bengaluru, Karnataka, India

Abstract

Female sterilization is the most widely accepted contraception in the world today. From a practical perspective, gynecologists are at constant drive to provide effective, safe, least discomfort/pain and economical contraception to the couple. With the advent of hysteroscopic surgery innovation in the form of better optics, endoscopes, camera, equipment, and insufflation machines revolutionized the surgery. This review will discuss the evolution of different hysteroscopic sterilization methods, including the past, present and upcoming devices. However, concerns remain about the absolute irreversibility of the method of sterilization. Researchers have failed to find solution to meet all the criteria. But this route obviates surgical incision and requires local anesthesia or intravenous sedation. The safety, tolerability and efficacy of hysteroscopically placed device are discussed in depth. This article will certainly help the clinicians to keep abreast of latest advances in contraception and practice in broader perspective despite the availability of limited literature.

Keywords: Transcervical sterilization, Micro-insert device, Hysterosalpingogram (HSG).

INTRODUCTION

Blind attempts of electrocautery of uterotubal junction were reported as early as 1878. In 1916 Cooper and in 1927 Schroeder suggested direct visualization of tubal ostia and attempted hysteroscopic sterilization by diathermy. Some plugs were applied which expelled. All methods were withheld as private industry was not willing to spend money. Almost 30 years later re-exploration to occlude fallopian tube was undertaken with the advent of technology. Dr Rafael Valle et al introduced STOP intratubal device made up of stainless steel and coil amalgamate of steel and platinum. Upon deployment, it expands and anchors to fallopian tube. Inside the device, Dacron was used to permit tissue growth and occlude the tubes. The women indicated for hysterectomy at later date were picked for study design.

Historically, researchers have based their effects around one of the following strategies:

- Mechanical and occlusive devices or plugs
- Injection of tissue sclerosants or adhesives
- Diathermy.

PAST METHODS

Electrocautery

An electrode is passed into the intramural portion of the tube under hysteroscopic guidance, and coagulatory current is applied for several seconds. Authors reported patency rates as high as 20%. Poor effective rates, thermal injury, and uterine perforation made this technique unsafe in current use.

ND:YAG Laser

Laser is delivered through a long, flexible quartz fiber. Thermal injury to the depth of 5 mm is noted. The procedure was not cost-effective and trial was terminated due to high patency rate of 74%.

Chemical Method

Quinacrine is a drug with multitude of applications. Its main effects are antiprotozoal, antirheumatic, and sclerosing agent. This unique property of sclerosis was employed by Zipper et al to induce scar tissue at uterotubal junction to create block. In earlier studies (Chile), the quinacrine was delivered as slurry with dilution of 125 mg/ml and 250 mg/ml, three deaths were reported due to sudden absorption through endometrial capillaries. Later modified 7 pellets of 36 mg of quinacrine are placed into the uterus using a tube similar to Cu-T inserter in 2 to 3 doses one month apart in the proliferative phase of menstrual cycle. Quinacrine is a mutagen. It acts by chelation of DNA forming quinacrine DNA complex.

It is generally well tolerated and can be associated with cramping pain. Small number of women had salpingitis 3%, menstrual disorder 2.7% and dysmenorrhea 2%.

Pellets offered a cumulative pregnancy rate of 4.6%. Ten years of Vietnam study revealed a pregnancy rate of 12%. The most attractive part of quinacrine sterilization was cost effectiveness. No randomized controlled trials have been reported to date and there is controversy over its use.

CURRENT METHODS

Essure Micro-insert

It is the first transvaginal approach approved by FDA in 2002 for intertubal sterilization technique (Fig. 1). The Essure micro-insert is wound-down configuration in 4 cm long nickel-titanium(nitinol) alloy outer coil in which the polyethylene terephthate (pet fibers) is inserted to



Fig. 1: Expanded essure device. The essure micro-insert expands to a diameter of 1.5 to 2 mm depending on the diameter and shape of the surrounding fallopian tube

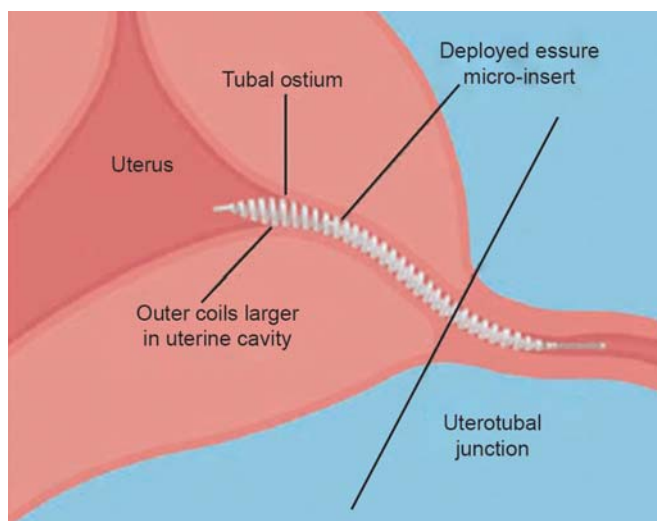


Fig. 2: Diagram of the UTJ. The micro-insert should span the UTJ, defined as the portion of fallopian tube just as it exits the uterus. In this location, the coils span the intramural and proximal isthmic portions of the fallopian tube. The device is placed far enough into the tube to prevent expulsion during uterine contractions during menses, but still has a portion trailing into the uterine cavity. The outer diameter of the coils that trail into the uterus is larger than that of the coils in the fallopian tube, which helps anchor the device. The UTJ is most consistently the narrowest portion of the fallopian tube, which further aids in anchoring the device

intramural part of fallopian tube under hysteroscope guidance (Fig. 2). It attracts macrophages, mononuclear cells, fibroblasts, foreign body giant cells, and plasma cells immediately (Figs 3A to C). The inflammatory response peaks between 2 and 3 weeks and lasts approximately 10 weeks. Induced fibrous reaction blocks the tube, which is irreversible. Hence, alternative contraception is advisable for three months. It is preferably advised in proliferative period or 6 weeks postnatal or post-termination allows enhanced visualization of tubal ostia and optimizes the success rate.

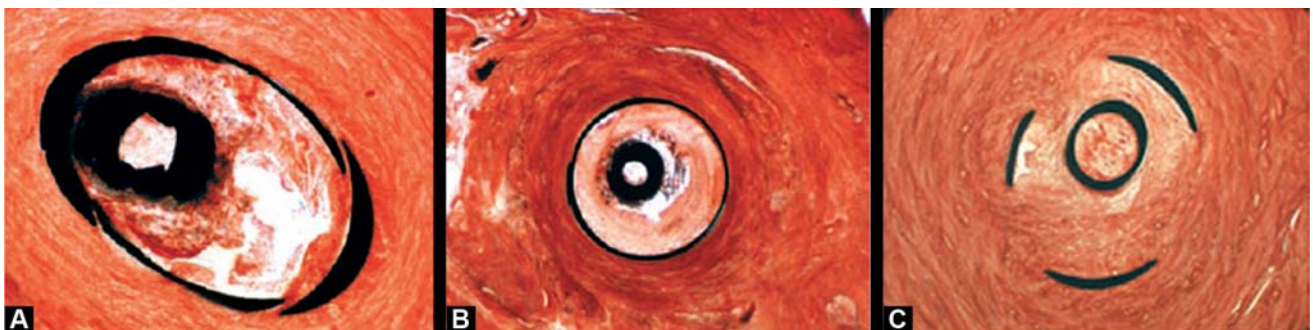
It is recommended to women who have completed their families and desire permanent sterilization. It is also excellent choice for women with high risk of general anesthesia, intraoperative complication, adhesions and bleeding. Women with an intracavity lesion, congenital anomaly, fibroids, infection, uterine synechiae, cervical cancer, cervical stenosis and scarring of uterus or cervix may not be eligible for essure as visualization of tubal ostia is compromised. Pregnancy test is essential on the day of surgery to exclude luteal phase of pregnancy if contraception not practised.

Patient Counseling

Patient's consent is taken which briefs the name of the surgery, procedure, benefits, risks of both sterilization and hysteroscopy, and alternative methods. The implications of anesthesia are also discussed and supported with information leaflet. Although the procedure is simple, nurse or assistant can reiterate in lay terms the procedure on the day of surgery. Patient is put to ease as much as possible. Patient is instructed to empty her bladder.

Procedure

The procedure is performed under intravenous conscious sedation (midazolam/fentanyl) or local paracervical block. The uterovaginal plexes are predominantly located lateral



Figs 3A to C: Histologic findings after essure placement. (A) At 1 week, fibrosis and acute inflammatory cells can be seen infiltrating the device.(B) Four weeks after placement, both acute and chronic inflammatory cells are present and fibrosis is beginning to occlude the lumen. (C) At 10 weeks, dense fibrosis is filling the tubal lumen

and posterior to the cervix. The cardinal ligament transit nerve at 3 and 9 o'clock position. Uterosacral at 5 and 7 o'clock position. Injection of 1% lignocaine 3 to 5 ml is recommended at 4 and 8 or 5 and 7 to maximize the anesthesia while paracervical block is performed. Each step is kept informed. A nonsteroidal anti-inflammatory suppository may help to alleviate her uterine cramps.

The OT is set with basic instruments which includes hysteroscope and diagnostic sheath, a sheath to permit passage of ancillary instruments, distension media, lighting system, and duck-billed speculum, a single-toothed tenaculum, dilators stand by and a paracervical kit (Fig. 4).

The procedure begins with the patient in the lithotomy stirrups. The vulva and perineal areas are sterilely prepped with the iodine based solution and then sterile drapes are placed over the legs and abdomen. A pelvic examination is performed to determine the size of uterus and its orientation. The cervix is identified. The hysteroscope is introduced and findings are explained to the women observing the view. A sterile speculum is placed on posterior vaginal wall.

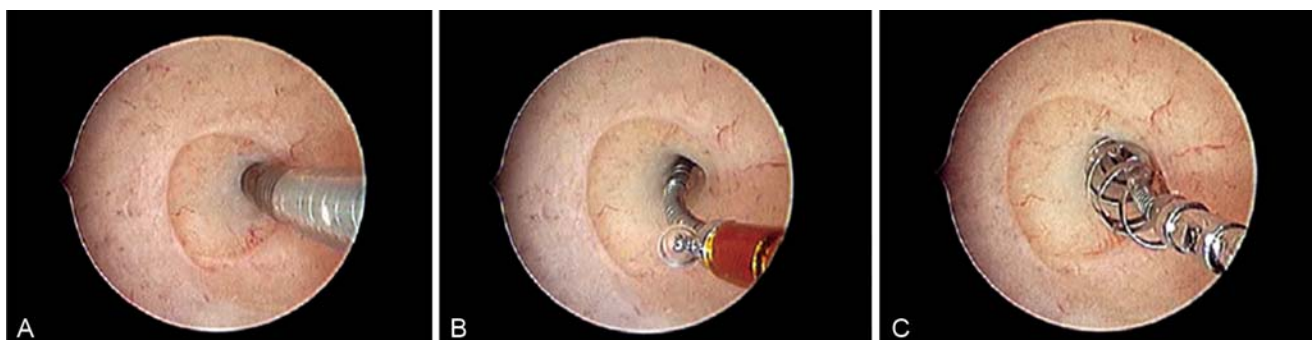
The micro-inserts are placed using essure delivery system through a 5 mm hysteroscope 12 to 30 degrees, which allows cannulation of fallopian tube, as it helps in forward view. With a continuous flow system, the hysteroscope is placed under direct visualization through the cervix prior to dilatation. Normal saline is used during placement of hysteroscope to aid visualization. An initial



Fig. 4: Essure micro-insert in wound-down configuration. The essure micro-insert, when attached to the delivery wire in a wound-down configuration, is 4 cm in length and 0.8 mm in diameter

attempt to pass the hysteroscope may be made without the use of tenaculum. If needed, cervical dilatation is performed. Normal saline is used at body temperature and introduced under gravity. Pressure bags may be used to maintain uterine distension. Panoramic view of uterine cavity is taken, ostia identified. Easier one is taken up first, which will help prevent the endometrium from becoming edematous and obscuring the view.

The essure delivery system is passed through introducer and down the working channel with tubal ostia in view. The system is advanced into the proximal fallopian tube with constant gentle forward pressure, which helps to prevent tubal spasm (Figs 5A to C). When the black mark is at ostia, the unit is deployed and handle of delivery device is stabilized against the hysteroscope. The technique involves the thumb on essure handle, which is rotated at one click/sec retracting the delivery catheter and exposing the wound-down. Approximately 1 cm of insert is visible in uterine cavity, i.e. small notch on wound-down insert and orange catheter is out and confirms proper placement. Then, button on the handle is depressed enabling the thumb to rotate. If arrest of rotation and no further withdrawal of orange catheter occurs, the procedure is complete and allows insert to expand approximately 10 cm. With a counter clockwise rotation, the delivery system is withdrawn from the catheter. After the procedure, 3 to 8 outer coils should be visible in uterine cavity. If 18 or more, consider removal of the device. The same procedure is repeated on contralateral side. The mean procedure time is 9 to 13 minutes. Proper placement of the device can be confirmed by X-ray at 11 o'clock and 1 o'clock position or ultrasound. Patency of the tube can be ascertained by HSG after three months. Postoperatively women are advised analgesics for pain and to abstain from sex for 10 days to avoid infection. The women are informed



Figs 5A to C: Steps for correct placement of the micro-insert. (A) When the black marker on the delivery catheter is at the ostia, the insert is in the ideal position spanning the intramural and proximal isthmic segments of the fallopian tube. (B) After retracting the delivery catheter and exposing the wound-down micro-insert, the orange attachment to the delivery catheter can be identified. To confirm proper placement, the small notch in the wound-down insert should be located just outside the tubal ostium before completing the deployment of the device. (C) Ideally, three to eight expanded outer coils should be trailing in the endometrial cavity. Here four coils are seen

of alternative contraception for 12 weeks. The women are discharged on the same day with follow-up date.

STUDY SUMMARY

Phase 1 trial revealed that 85% had successful placement, 98% had satisfactory rate and bilateral block demonstrated. In retrospective study from 2002 to 2008 in Netherlands, 10 unwanted pregnancies occurred which could be due to expulsion of device (2.9%), perforation (1%). Other reasons could be due to inadequate interpretation of HSG, noncompliance of physician or defaulted follow-up. After modification of device by innovating hydrophilic coating and improved flexibility, the success of cannulation was 98%. Phase 2 trial revealed 96% correct device placement. One patient expelled the device and in other device was placed in myoma. In phase 3 trial, 11 were declined due to uterine polyp, blocked ostia and cervical stenosis.

RESULTS

First study of safety was established in 2001. Over 50,000 procedures have been formed worldwide with 12,000 in Europe, where 600 surgeons were trained in the technique. Recently accepted FDA data indicates 99.7% effectiveness with usage over 5 years.

Adverse Effects

No method is 100% effective. There is a possibility of ectopic pregnancy. Postprocedural pain (1-3%) resolved in one to three days. Mild vaginal bleeding lasted up to one week. Perforation (1%) could be due to support catheter, which was later abandoned. A case of pyosalpinx noted could be attributed to migration of device. The risk of pregnancy can be reduced by strict follow-up. The theoretical risk of interference with IVF pregnancy. Progressive encapsulation is unlikely to interfere with embryo transfer. The risks of hysteroscopy should not be forgotten. The major drawback with the device is that first generation ablative techniques are not possible.

Hysteroscopy complications include cervical laceration with tenaculum forceps. Uterine perforation can be encountered with forceful dilatation, false passage; bleeding can occur if hysteroscope is advanced blindly or forcibly into the uterine cavity. Infection is rare if necessary precaution of disinfection is undertaken prior to surgery.

Complication of distention media is of concern in prolonged hysteroscopic surgeries. In sterilization surgery, fluids containing electrolytes when used are less likely to

cause serious problem. It is wise to keep intrauterine pressure below 100 mm Hg. Hypercarbia, acidosis and air embolism may be encountered if carbon dioxide is used in office hysteroscopy.

Local anesthesia occasionally may cause allergic reaction. The most common complications are due to intravasation.

DEVICE IN DEVELOPMENT

Adiana Complete System

It is a two stage procedure. In the first instance the intramural part is treated with radiofrequency energy (Fig. 6). The second step is the placement of porous silicone nonbiodegradable matrix, a size of grain is inserted into the tubal lumen. The implant provokes a fibrous reaction and occludes the tube over the period of week.

Procedure involves a flow hysteroscope, the 5F catheter is placed in 6F working channel. A black mark on catheter assures correct placement. Later, radiofrequency generator

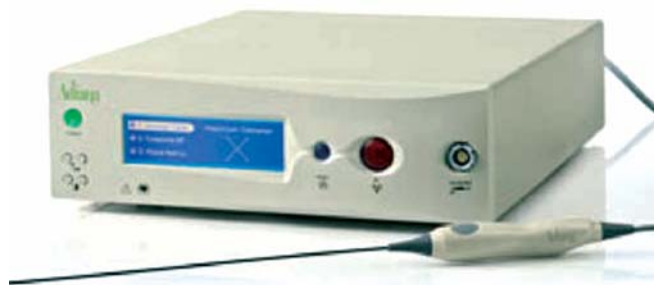

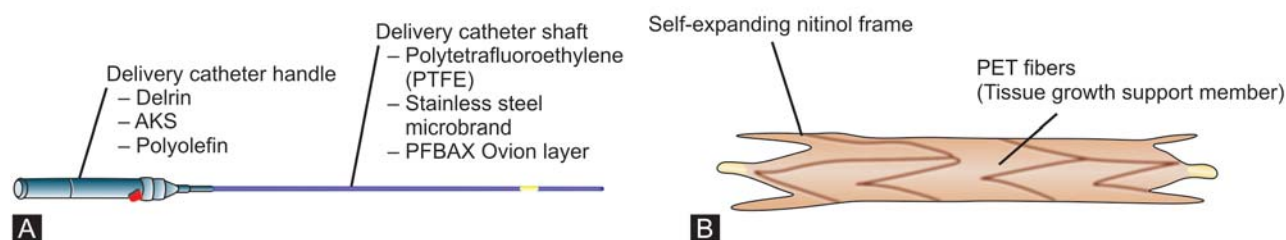
Fig. 6: The Adiana system

is activated at tubal ostia. The sensors give feedback when heated and later the matrix is released from the tip of the delivery system. Proximal 12 mm of tube is cannulated. The concept is to allow the growth of healthy vascularized tissue in the porous matrix. The mean procedure time is 12 minutes. There was no procedure related adverse event. Women are asked to continue contraception for 12 weeks. HSG at this point confirms success.

The EASE trial (evaluation of Adiana system) was completed in 2005. It was stated, 612 women were treated with an 95% bilateral insertion rate.

Ovion Eclipse

This system was designed to negate the shortcoming of Essure implant, such as endometrial ablation technique and potential need of IVF pregnancy (Figs 7A and B). To accommodate this criteria, the device was shortened by



Figs 7A and B: The Ovion System: (A) The Ovion system is 1 mm in outer diameter and can be placed through 3F working channels found in small rigid or flexible hysteroscopes. (B) The micro-insert is made up of a self-expanding nitinol frame embedded with PET fibers, which support tissue ingrowth

2 cm. It is permanent contraceptive device consisting of expandable metal tube containing an inner matrix that induces fibrosis and blockage of the intramural part of tube. FDA approval has not yet sought. The micro-insert is composed of self-expanding nitinol frame embedded with PET fibres. No portion of device trail to uterine cavity. Ovion system is 1 mm in outer diameter and can be placed through 3F working channel found in small rigid or flexible hysteroscopes. Both micro-inserts are loaded simultaneously so they could be deployed in succession. The ovion device can be loaded to flexible hysteroscope as office use. It is easier, faster and could have potential benefit of IVF or endometrial ablation.

Intratubal Ligation Device(USA)

The occlusion is achieved by ligation of intravaginal portion of tubal epithelium by an elastomeric band which leads to scar formation and creates permanent damage. This is under phase 1 trial.

SUMMARY

After 100 years of seeking safe and effective methods for female sterilization that avoid entry into the abdomen, transcervical sterilization is today's reality. Essure appears to be equal or superior to laparoscopic sterilization. It offers benefits of an office procedure under local anesthesia. It is cost-effective and better resource utilization. Hysteroscopic sterilization is alternative in women with severe cardiopulmonary disease, obesity or a history of prior abdominal or pelvic surgery where laparoscopy is contraindicated. Adequate audit and women counseling is essential. Future insight to develop reversible device is challenging.

Points to Remember

- Method of tubal occlusion using electrocautery or ND: YAG laser is abandoned.

- Transcervical methods. Essure is safe and effective. No major adverse events are reported. Strict inclusion criteria and follow-up is essential to optimize the outcome. Alternative contraception practice is mandatory for improved success rate. HSG is advocated after 12 weeks to assess the outcome.
- In the Adiana method, the procedure is safe and well tolerated. Cost data is not yet known.
- Quinacrine is studied in poorer nations where medical technology is less. It is a mutagen. It is implicated as a potential carcinogen although not established. It is cost effective.

ACKNOWLEDGMENT

I thank Professor Dr RK Mishra without whose exceptional and admirable guidance I would not have gone through this DMAS course and wonderful training which carve a niche in my career and professional development.

BIBLIOGRAPHY

1. Cooper JM, Carignan CS, Cher D, Kerin JF. Selective Tubal Occlusion Procedure 2000 Investigators Group. Microinsert nonincisional hysteroscopic sterilization. *Obstet Gynecol.* 2003;102(1):59-67.
2. Cooper JM. New approaches to hysteroscopic sterilization. *Contemp Ob Gyn* 2003;48:8-20.
3. Essure (package insert). San Carlos, CA: Conceptus Inc.; 2002.
4. Estridge TD, Feldman DS. Quantification of vascular ingrowth into Dacron velour. *J Biomater Appl* 1991;6(2):57-169.
5. Kerin JF, Carignan CS, Cher D. The safety and effectiveness of a new hysteroscopic method for permanent birth control: Results of the first Essure pbc clinical study. *Aust NZJ Obstet Gynaecol* 2001;41(4):364-70.
6. Kerin JF, Cooper JM, Price T, et al. Hysteroscopic sterilization using a microinsert device: Results of amulticentre phase II study. *Hum Reprod* 2003;18:1223-30.
7. Kerin JF, Munday DN, Ritossa MG, Pesce A, Rosen D. Essure hysteroscopic sterilization: Results based on utilizing a new coil catheter delivery system. *J Am Assoc Gynecol Laparosc* 2004;11(3):388-93.
8. MacKay AP, Kieke BA (Jr), Koonin LM, Beattie K. Tubal sterilization in the United States 1994- 1996. *Fam Plann Perspect.* 2001;33(4):161-65.

9. New developments Advances in hysteroscopic sterilisation. The Obstetrician and Gynaecologist 10.1576/toag.8.2.103.27229 www.rcog.org.uk/togonline 2006;8:103-06.
10. Valle RF, Carignan CS, Wright TC. STOP Prehysterectomy Investigation Group. Tissue response to the STOP microcoil transcervical permanent contraceptive device: Results from a prehysterectomy study. Fertil Steril 2001;76(5):974-80.
11. Valle RF, van Herendael BJ. New indications for hysteroscopy: Sterilization. In: Van Herendael BJ, Valle R, Bettochi S (Eds). Ambulatory Hysteroscopy:Diagnosis and Treatment. Chipping Norton, Oxfordshire, UK: Bladon Medical Publishing; 2004: 143-51.
12. Veersema S, Vleugels MP, Moolenaar LM, Janssen CA, Brölmann HA. Unintended pregnancies after Essure sterilization in the Netherlands. Fertil Steril. Jan 2010;93(1):35-88. Epub 2008 Nov 21.
13. Westhoff C, Davis A. Tubal sterilization: Focus on the US experience. Fertil Steril. 2000;73(5):913-22.