

# Laparoscopic Cholecystectomy: Fundus First or Fundus Last—Which and Why?

Motassim Barham

Member, Jordanian Association of Surgeons, Fellow, The Global Open University in Laparoscopic Surgery, Member, World Association of Laparoscopic Surgery, General and Laparoscopic Surgeon, Amman, Jordan

## ABSTRACT

Biliary tract injury represents the most serious and potentially life-threatening cholecystectomy complication. It is important to identify the structure of Calot's triangle during isolation of cystic duct to decrease this injury. Cystic duct isolation is the first dangerous technique in laparoscopic cholecystectomy. Retrograde (fundus first) dissection is frequently used in open cholecystectomy and although feasible in laparoscopic cholecystectomy, it has not been widely practiced as the antegrade conventional one. This article is presented to show that retrograde method appears to be a safe procedure and does not compromise the conventional one. It should be tried if obscure anatomy should occur without proceeding to irreparable hemorrhage or biliary injury. If these do occur, conversion is always a viable choice and should not be deemed a failure. However, retrograde dissection remains to have its error trap that is mostly leading to vasculobiliary injuries as well as the drawback of retained GB stones tendency.

**Abbreviations:** OC: Open cholecystectomy, LC: Laparoscopic cholecystectomy, RLC: Retrograde laparoscopic cholecystectomy, CLC: Conventional laparoscopic cholecystectomy, GB: Gallbladder, CBD: Common bile duct, CHD: Common hepatic duct, IOC: Intraoperative cholangiography, ERCP: Endoscopic retrograde cholangiopancreatography.

**Keywords:** Fundus-first, Fundus-down, Retrograde, Antegrade, Conventional, Laparoscopic cholecystectomy.

## INTRODUCTION

Iatrogenic biliary injuries have increased in incidence in the first decade with the introduction of LC. The incidence of major biliary injury is 0.25 to 0.74% and of minor injury is 0.28 to 1.7%.<sup>1</sup> Although a number of factors have been identified as high risk and a number of technical steps have been emphasized to avoid these injuries, the incidence of CBD injury has reached at least double the rate observed with OC. Cholecystectomy is the most frequently performed abdominal operation and the most serious complication associated with this procedure is accidental injury to CBD (0.3-0.4%).<sup>2</sup> Preventable technical errors have traditionally been thought to occur in one or more of the three situations:

- When the operator attempts to clip or ligate a bleeding cystic artery and CHD,
- When too much traction has been exerted on GB, so that CBD has tented up into an elbow which was either tied off with ligature or clipped,
- When anatomic anomalies were not recognized and the wrong structure is divided.

The use of the safest surgical technique (not the fastest) available, such as the critical view technique of Strasberg et al with the circumferential dissection of GB at the infundibulum to mimic RLC technique of the open era and not clipping or cutting any structure before unequivocal identification of the structure are mandatory components of the safe LC.<sup>3</sup>

The cause of the injury is not always clearly identifiable. In more than half of the cases, the injury occurs during

maneuvers to isolate the cystic duct or to free GB from CBD. These maneuvers may be more difficult and consequently more dangerous when there is significant inflammation as may be seen in acute cholecystitis or in case of obesity, cirrhosis with portal hypertension, previous surgery with peritoneal adhesions or anatomic variations of the hepatic pedicle. This article is presented to investigate the place of RLC showing the advantages and disadvantages and comparing it with CLC via many different parameters, especially biliary tract injury.

## AIMS AND OBJECTIVES

The aim of this study is to compare the effectiveness and safety among many other parameters assessed of RLC (up-down) vs CLC (down-up). The following parameters were evaluated:

- Patient selection methods
- Operative techniques
- Operative time
- Incidence of biliary injury
- Complications
- Rate of conversion
- Hospital stay and cost effectiveness
- Learning curve.

## MATERIALS AND METHODS

A literature search was performed by using Google and Online Springer Library facilities available at World

Laparoscopy Hospital (WLH). Selected papers were screened for further references. Criteria for selection of literature were methods of analysis (statistical or nonstatistical) and the institution where the study was done (specialized one for laparoscopic surgery). Priority was taken to select the newest comparative studies from well-known scientific highly specialized journals. Number of cases were not considered as a criteria since the procedure itself is not universally undertaken as CLC.

A prospective record of all LCs carried out by an experienced laparoscopic surgeon following his appointment in Bristol in 2004, was examined. RLC was resorted to when difficulties were encountered with exposure and/or dissection of Calot's triangle. A conclusion recommended that this technique does have a place and should be in the armamentarium of the laparoscopic surgeon.<sup>4</sup>

### PATIENT SELECTION METHODS

In the background of the comparative results of the study which was carried out at Nerima General Hospital, Tokyo, Japan,<sup>5</sup> RLC showed satisfactory results in terms of both safety and reliability in patients with severe inflammatory disease.

A prospective record of all LCs carried out in Bristol, in 2004, was examined.<sup>4</sup> RLC was resorted to when difficulties were encountered with exposure and/or dissection of Calot's triangle. RLC was attempted successfully in 11 out of 1,041 patients. The age ranged from 28 to 80 years (mean 61) and there were seven males. Indications were: fibrous, contracted GB (7), Mirizzi syndrome (2) and severe kyphosis (2). Histopathology showed chronic cholecystitis (7), xanthogranulomatous cholecystitis (3) and acute necrotizing cholecystitis (1).

### OPERATIVE TECHNIQUES

RLC procedure is as follows: First, the cystic duct and artery are exposed at the junction of the ampulla. The cystic duct is clipped, and the artery is divided. Removal of the GB is then started from the fundus to cystic duct downwards. After the GB has been dissected from the liver bed, the cystic duct is double-clipped and divided (Fig. 1).<sup>6</sup>

In conventional OC, the fundus-down approach is a more common procedure than the approach in the reverse direction. The easy and safe contrivance for LC with taping of the cystic duct temporarily with Teflon tape followed by resection of the GB with the fundus-down approach was performed. The tape was used for pulling down the cystic duct, and Calot's triangle was easily visible. The cystic duct was cut off only after the confirmation of no CBD injury.<sup>7</sup>

### OPERATIVE TIME

A study in which LC was carried out in 173 patients, RLC was performed in 81; the mean operating time was

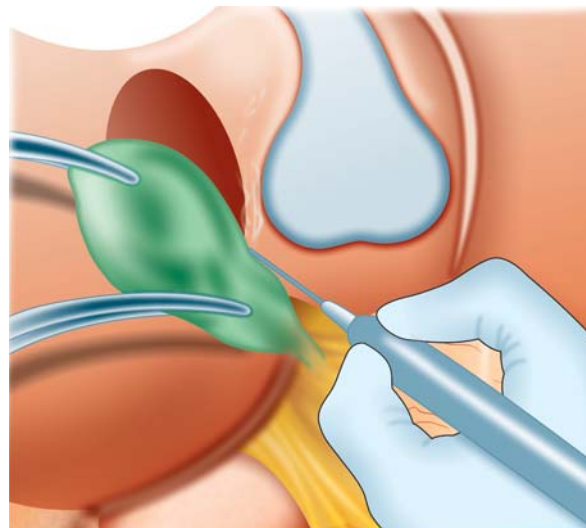


Fig. 1: RLC technique commencing from the fundus downwards (Ref. [www.themgcarshop.com/.../cholecystectomy.jpg](http://www.themgcarshop.com/.../cholecystectomy.jpg))

23 minutes shorter in RLC than in the usual LC because IOC was used much less often.<sup>6</sup>

Regarding the study contributed by Shing-Moo Huang and Kuang-Ming Hsiao,<sup>8</sup> the operation time was similar in the RLC and CLC groups.

In the study of Tuveri M et al<sup>9</sup> the median operating time for the RLC was 65 minutes (range 40-170).

### INCIDENCE OF BILIARY INJURY

RLC approach provides better visualization of the GB, cystic duct and CBD with less chance of CBD injury, due to clear identification of the ductal system, without the need for IOC.<sup>6</sup>

The easy and safe contrivance for LC with taping of the cystic duct followed by resection of the GB with the fundus-down approach, performed for 500 patients in which the cystic duct was cut-off only after the confirmation of no CBD injury was reported.<sup>7</sup> In the conclusion, the authors memorial comment was: "Thanks to this tape procedure, there was no CBD injury in our 500 cases. We recommend this tape ligation of the cystic duct with the RLC approach to decrease the incidence of CBD injury".

Some surgeons use RLC techniques routinely when performing LC and claim to have lower incidence of CBD injury than that of conventional techniques. The reason was that it adopted an operative strategy similar to OC proceeding from the fundus towards the cystic duct and cystic artery. RLC seemed to lower the CBD injury rate from 6.5 to 0%.<sup>8</sup>

A case study was reported whereas an anomaly of the extrahepatic biliary system is found in which the CHD was found to enter the GB whereas the cystic duct drained the whole biliary system into the duodenum.<sup>10</sup> Rarity of this configuration led to transection of the CHD during LC in most cases. In this case study, dissection of the GB starting from the fundus will allow timely discovery of such an

anomaly. Maintenance of continuity between the CHD and cystic common biliary duct by preserving part of the GB permits easy repair on a T-tube.

About 250 biliary injuries in a study,<sup>11</sup> many biliary misidentification injuries occur due to error traps method that work well in most circumstances but which are apt to certain conditions. The most common cause of misidentification results from the 'infundibular technique' error trap. This problem is usually associated with severe inflammation which hides the cystic duct and obliterates Calot's triangle making the CHD appear to be part of GB wall. Another error trap—RLC has been associated with injuries in which the vascular component has been even more serious than the biliary one. These injuries result in hepatic infarction requiring liver resection, possibly including transplantation. As opposed to CLC error trap, the fundus-down error trap usually occurs at OC after conversion. Knowledge of these error traps and their avoidance can help to reduce the incidence of biliary injuries (Fig. 2).

The cystic duct may be hidden in some patients having LC, especially in the presence of inflammation. This may lead to the deceptive appearance of a false infundibulum that misleads the surgeon into identifying the CBD as the cystic duct. Biliary injury is more likely when cystic duct identification is made by relying solely on the appearance of the junction of the cystic duct with the infundibulum, and this technique should be abandoned.<sup>12</sup>

## COMPLICATIONS

A study in which LC was carried out in 173 patients, RLC was performed in 81; the result of the study reported that RLCs were performed without severe complications, either immediate or late.<sup>2</sup>

Around 129 consecutive LCs were carried out and cases of RLC and CLC in a severe inflammatory and

noninflammatory groups were comparatively evaluated. The incidences of major postoperative complications were 0% in RLC cases and 17% in CLC cases in the severe inflammatory group.<sup>5</sup>

In another study,<sup>8</sup> the complication rate was lower in RLC group patients (3% vs 22.6%). Complications included CBD injuries, urinary tract infection and wound infection in CLC group patients, but only wound infection in RLC group patients.

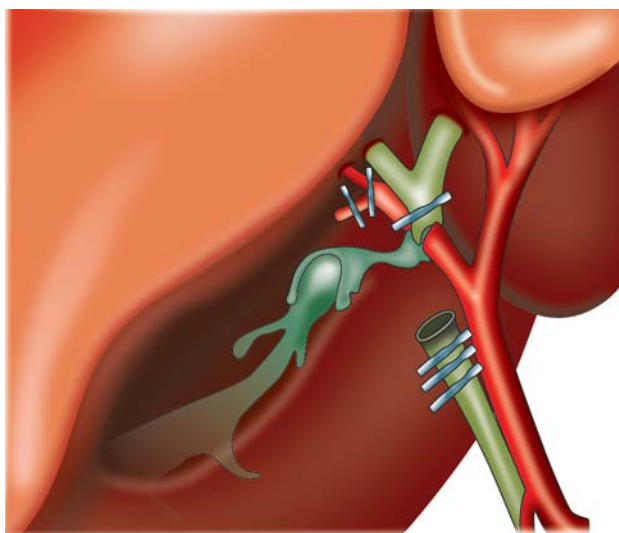
In conclusion of a study done by Tuveri M et al, RLC remains a safe option when dealing with patients with difficult anatomy at the Calot's triangle but its adoption needs a good surgical judgment.

Referring to another study,<sup>13</sup> RLC technique provides an alternative to CLC technique in patients at high risk for conversion or CBD injury. It reports the complication of a retained CBD stone after utilizing this technique. IOC was not performed due to the concern for causing CBD injury in a patient with significant periductal inflammation and no risk factors for CBD stones. Following discharge, the patient developed jaundice 3 days later and returned for evaluation. He required ERCP for removal of a CBD stone. It should now be recognized that there is a risk of displacing a gallstone into the CBD in utilizing RLC technique. This report highlights the importance of IOC when using this technique, even in patients considered to be at low risk for having CBD stones. If IOC is considered hazardous, then intraoperative ultrasound should be the modality of choice.

## RATE OF CONVERSION

Nerima General Hospital, Tokyo, Japan, study has a very clear answer in this field.<sup>5</sup> The rates of conversion to laparotomy were 0% in RLC cases and 33% in CLC cases in the severe inflammatory group.

Contracted GB is known to result from long-standing chronic cholecystitis, in which rigid fibrosis of areolar tissue makes cystic duct and cystic artery structures relatively more fragile and vulnerable to injury during Calot's triangle dissections. It might be the fibrotic rigidity nature of pericholecystic areolar tissue in patients with contracted GB that contributes to the high incidence of obscure anatomy in triangle of Calot, intraoperative hemorrhage and CBD injury encountered during CLC. From reports in a study,<sup>8</sup> contracted GB is the leading cause of conversion from LC to OC due to obscure anatomy or increased risk for intraoperative hemorrhage from GB bed. The conversion rate was markedly lower in the RLC group patients. The reasons for conversions, included CBD injuries, intraoperative hemorrhage and obscured anatomy. So, this is the cause for decreasing the rate of conversion in RLC group from 18.75 to 2.08%.<sup>14</sup>



**Fig. 2:** Most common error traps which occur during performance of CLC and RLC. (Ref. catalog.nucleusinc.com/imagescooked/1783W.jpg)

## HOSPITAL STAY AND COST EFFECTIVENESS

Mean of 2.2 days was the postoperative stay with no delayed sequela in a prospective study.<sup>4</sup> Regarding another study, RLC had shorter postoperative hospital stays by an average of 2 days when compared with CLC.<sup>8</sup>

## LEARNING CURVE

RLC can reduce the time of surgery and is an easier technique to perform. Therefore, it can be proposed as the standard procedure and not only be used for difficult LCs.<sup>15</sup>

## DISCUSSION

A great deal continues to be written about CBD injuries in LC, which serves to underscore the seriousness of the complication and the perception that it can and should be avoided. The current rate of major CBD injury in LC has stabilized at 0.1 to 0.6%, and series with no major CBD injuries have been reported; while many believe that the rate of major CBD injury in OC is lower than in LC, controversy remains. A host of factors has been associated with CBD injury, including surgeon experience, patient age, male sex and acute cholecystitis, though the effect that acute cholecystitis has on injury rates remains controversial. CBD injuries, which occur with LC, frequently involve complete disruption and excision of ducts and may be associated with hepatic vascular injuries. Since, major CBD injuries with LC are most frequently due to duct misidentification, techniques for prevention and/or recognition focus primarily on careful anatomic definition to ensure the 'critical view' prior to dividing any structures. The Society of American Gastrointestinal and Endoscopic Surgeons (SAGES) first offered guidelines for the clinical application of LC as a safe and effective treatment for most patients with symptomatic gallstones in May 1990. These guidelines have periodically been updated, and the last guidelines, in November 2002, expanded to include all laparoscopic biliary tract surgeries, keeping in mind the safety and effectiveness of the procedures. The CLC technique for dissection of GB from the liver bed as described in the guidelines is to start from the GB infundibulum and work superiorly using electrocautery to remove GB from the bed. The technique of RLC has also been advocated, particularly in cases with significant inflammation. The standard technique works well and, with no compelling data to use the alternative technique, the choice is left to the surgeon.<sup>16</sup>

LC from fundus downward is desirable when exposure of the cystic duct is difficult and hazardous. First, the cystic duct and artery are exposed and clipped, and the artery is divided. Then removal of the GB is started from fundus downward. After GB is dissected from the liver bed, the cystic duct is double clipped and divided. This approach

affords better visualization of the cystic duct and CBD with less chance of CBD injury. Many studies were reported without immediate or late complications.<sup>17</sup> The facility to retract the liver and carry out RLC extends techniques developed for OC into the laparoscopic arena. It offers the surgeon the safety and versatility during LC that it confers during OC.<sup>18</sup>

## CONCLUSIONS AND RECOMMENDATIONS

RLC appears to be a safe procedure and does not compromise the CLC method. After reviewing all data, however, I would like to recommend the following algorithm regarding laparoscopic management of GB diseases. Firstly, the surgeon should try CLC, as the technique is most familiar and comfortable to most surgeons. Secondly, if obscure anatomy should occur without proceeding to irreparable hemorrhage or CBD injury, the surgeon should resort to RLC on site. Usually, this will solve the problem. Thirdly, if hemorrhage or CBD injury do occur, conversion to OC is always a viable choice and should not be deemed a failure. However, RLC as CLC, remains to have its error trap that is mostly leading to vasculobiliary injuries as well as the drawback of retained GB stones tendency which mandates routine IOC.

## REFERENCES

1. Nuzzo G, et al. The risk of biliary ductal injury during LC. *J Chir (Paris)* Nov 2004;141(6):343-53.
2. Sváb J, et al. Prevention, diagnosis and treatment of iatrogenic lesions of biliary tract during LC. *Rozhl Chir* Apr 2005;84(4):176-81.
3. Richard M Vazquez. Common sense and CBD injury: CBD injury revisited *Surg Endosc* 2008;22:1743-45.
4. Kelly MD. Laparoscopic retrograde (fundus first) cholecystectomy. PMID: 20003333 (PubMed-indexed for MEDLINE) PMID: PMC 2801662 Free PMC Article.
5. Uyama I, et al. Laparoscopic retrograde cholecystectomy (from fundus downward) facilitated by lifting the liver bed up to the diaphragm for inflammatory GB. *Surg Laparosc Endosc* Dec 1995;5(6):431-36.
6. Kato K, et al. A new technique for LC-RLC: An analysis of 81 cases. *Endoscopy* May 1996;28(4):356-59.
7. Ichihara T, et al. Tape ligation of cystic duct and fundus-down approach for safety LC: Outcome of 500 patients. *Hepato-gastroenterology* Mar-Apr 2004;51(56):362-64.
8. Shing-Moo Huang, et al. Overcoming the difficulties in laparoscopic management of contracted GB with gallstones: Possible role of fundus-down approach, *Surg Endosc*.
9. Tuveri M, et al. Limits and advantages of fundus-first LC: Lessons learned. *J Laparoendosc Adv Surg Tech A* Feb 2008;18(1):69-75.
10. Moshe Hashmonai, et al. An anomaly of the extrahepatic biliary System. *Arch Surg* 1995;130(6):673-75.
11. Steven M Strasberg. Error traps and vasculo-biliary injury in laparoscopic and OC, *Hepatobiliary Pancreat Surg* 2008;15:284-92.

12. Strasberg SM, et al. The “hidden cystic duct” syndrome and the infundibular technique of LC: The danger of the false infundibulum. *J Am Coll Surg* Dec 2000;191(6): 661-67.
13. Dolan JP, et al. Retained CBD stone as a consequence of a fundus-first LC. *J Laparoendosc Adv Surg Tech A* Jun 2005;15(3):318-21.
14. Gupta A, Agarwal PN, Kant R, Malik V. Evaluation of fundus-first LC. *JSLs* Jul-Sep 2004;8(3):255-58.
15. Neri V, et al. Antegrade dissection in LC, *JSLs* Apr-Jun 2007;11(2):225-28.
16. Wayne Overby D, et al. Sages guidelines for the clinical application of laparoscopic biliary tract surgery, *Surg Endosc* 2010;24:2368-86.
17. Kato K, et al. LC from fundus downward. *Surg Laparosc Endosc* Oct 1994;4(5):373-74.
18. Martin IG, et al. Fundus-first LC, *Surg Endosc* Feb 1995;9(2): 203-06.