

Prophylactic Ureteric Catheterization with Illuminated Ureteric Stent during Difficult Laparoscopic Colorectal Surgeries

Manash Ranjan Sahoo, T Anil Kumar

ABSTRACT

Background: The close proximity of ureters to the colon and rectum, ureteric injury is a potential complication in colorectal surgery. Incidence of iatrogenic ureteric injury ranges from 1 to 10%.

Aim: The aim of this study is to evaluate the operative time, the efficacy in preventing iatrogenic ureteric injuries and the complications associated with prophylactic illuminated ureteric catheterization in the difficult laparoscopic colorectal surgeries.

Materials and methods: Twenty-two patients who underwent difficult laparoscopic colorectal surgery from 2009 to 2011 in Department of General Surgery in SCB Medical College Hospital, Cuttack, were included in the study. The ureteric catheterizations were cystoscopically performed by using number 5 French illuminated ureteric catheter.

Results: The use of ureteric catheters added a mean of 20 minutes to the total surgical procedure time. Postoperative complications oliguria or anuria not seen. Urinary tract infection seen in one patient which makes the incidence of 4.5% in our study. There was no ureteric injury during surgery. Average hospital stay was 6 days. Overall cost did not alter. There were no cases of conversion to laparotomy in our study.

Conclusion: With negligible morbidity, the use of illuminated ureteric stents ensure ureteric safety in complex cases by direct visualization of the ureteric position throughout the dissection, especially in laparoscopic surgeries. Iatrogenic ureteric injuries and conversion to laparotomies are minimized by using illuminated ureteric stent.

Keywords: Laparoscopic, Colorectal surgery, Ureteric injuries, Illuminated ureteric catheters.

How to cite this article: Sahoo MR, Kumar TA. Prophylactic Ureteric Catheterization with Illuminated Ureteric Stent during Difficult Laparoscopic Colorectal Surgeries. *World J Lap Surg* 2012;5(3):113-115.

Source of support: Nil

Conflict of interest: None declared

INTRODUCTION

Proximity of ureters to the colon and rectum, ureteric injury is a potential complication in colorectal surgery, especially in advanced carcinoma, previous surgery, radiation which displaces the ureter, eventually making the identification difficult.

Incidence of iatrogenic ureteic injury ranges from 1 to 10%. Most injuries occur during rectal and sigmoid mobilization.

Ureteric stents can be of great help if ureter identification difficulty is anticipated. The use of illuminated ureteric stents adds another dimension to ensure ureteric safety in complex cases by giving direct visualization of the ureteric position throughout the dissection.¹

AIM

The aim of this study is to evaluate the operative time, the efficacy in preventing iatrogenic ureteric injuries and the complications associated with prophylactic ureteric catheterization with illuminated ureteric stents in the difficult laparoscopic colorectal surgeries.

MATERIALS AND METHODS

Twenty-two patients who underwent difficult laparoscopic colorectal surgery from 2009 to 2011 in Department of General Surgery in SCB Medical College and Hospital, Cuttack, were included in this retrospective study.

All patients who underwent laparoscopic colorectal surgery were assessed. Patient variables that were analyzed included surgical indications, history of prior abdominal surgery, time from induction of anesthesia to surgical incision (preparation time), total operative and total anesthesia times (beginning of stent insertion to completion of surgery) and postoperative morbidity.

All ureteric catheters were tested for illumination before surgery (Fig. 1). All ureteric catheterizations were




Fig. 1: Illuminating ureteric stent

cystoscopically performed by one of the staff urologists using number 5 French ureteric catheters (Fig. 2). The catheters were placed after induction of general endotracheal anesthesia and in the modified supine lithotomy position but prior to the commencement of the laparoscopic colorectal procedure. The catheter which was inside ureter was illuminated after connecting to light source (Fig. 3). All stents were removed in the operating room immediately prior to reversal of anesthesia.

Prophylactic antibiotics were given preoperatively to all the patients; oral neomycin 1 gm two times a day and metronidazole 500 mg three times a day on the day before surgery and intravenous cefuroxime 1 gm at the induction of anesthesia.

RESULTS

In our study, 22 patients who underwent elective laparoscopic colorectal surgery, the most common indication for ureteric catheterization was those who had previous lower abdominal surgery followed by colorectal malignancy and obesity (Table 1).

Among them, catheterization was done bilaterally in 15 patients and unilaterally in seven.

The most common surgery performed was laparoscopic abdominal rectopexy followed by colonic resections (Table 2).

There was no iatrogenic ureteric injury during laparoscopic colorectal surgeries in any of the patients. In our study, there was no morbidity directly related to the ureteric catheters, such as oliguria and anuria. The postoperative urinary tract infection was noted in one patient which accounts for the incidence of 4.5% in our study. So the incidence of urinary tract infection was similar in the catheterized group compared to the colorectal laparoscopic surgeries performed without ureteric catheters which are around 0.6 to 5.5%.

The insertion of preoperative ureteric catheters increases both the length of time in the operating room and that under anesthesia. The overall operative times were increased to an average of 20 ± 5 minutes in the catheterized group.

The hospital stay was on average of 6 days.

Overall cost of the surgery to the patient also did not alter.

There were no cases of conversion of laparoscopic surgery to laparotomy in our study.

Indications for ureteric catheterization in laparoscopic colorectal surgery in our patients is shown in Table 1. Surgeries performed in which ureteric stenting was done is shown in Table 2.

DISCUSSION

Most ureteral injuries are iatrogenic and they arise as potential complications of urological, abdominal or pelvic operations;² these injuries have an overall incidence of 0.3 to 10%. Although the surgical management of ureteral injuries is simple and successful once they are recognized during surgery but these injuries are generally missed in 67 to 89% of all cases.

Table 1: Common indication for ureteric catheterization

Indications	No. of cases	Percentage
Previous abdominal surgery	9	40.90
Obesity	6	27.27
Tumors	4	18.18
Crohn's disease	3	13.63

Table 2: Common surgeries performed

Surgery	No. of cases	Percentage
Rectopexy	12	54.4
APR	4	18.18
LAR	3	13.63
Segmental colectomy	3	13.63




Fig. 2: Usage of cystoscope for introduction of ureteric stent

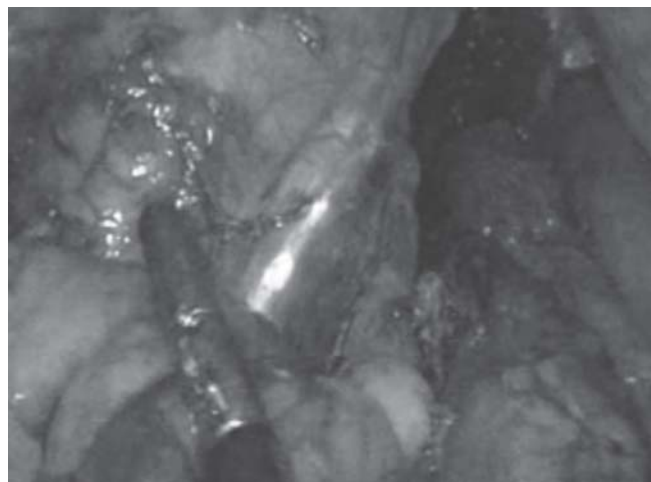

Fig. 3: Intracorporeal view of illuminated ureteric stent

Some surgeons advocate that this practice of preoperative placement of ureteric stents should help avoid ureteric injury,^{1,3,4} while others fear the potential injury during insertion and postoperative urinary complications including oliguria, anuria and urinary tract infection. Moreover, the insertion of preoperative ureteric catheters increases both the length of time in the operating room and that under anesthesia as well as the overall cost of the procedure.

Ureteric stents can be of great help, if ureter identification difficulty is anticipated.⁵ Standard 5F stents placement at the beginning of surgery allows easy identification by palpation. However, this is not 100% reliable. The use of illuminated ureteric stents adds another dimension to ensuring ureteric safety in complex cases by giving direct visualization of the ureteric position throughout the dissection.⁶ Ureteric catheters may be particularly useful during laparoscopic colorectal procedures in which tactile localization is difficult.

Intraoperative complications have included laceration or perforation of the ureter during the stent placement.⁷ Well et al noted a 2.2% intraoperative complication rate in 561 prophylactic ureteric catheterizations, similar to the 2% rate reported by Leff et al.⁸ No iatrogenic injury to ureters were observed in our study.

Pandya et al investigated the conversions in 200 laparoscopic colorectal surgeries to laparotomies in 47 of them for which the indication was nonidentification of ureters.⁹ In another study by Huscher et al there were 21 conversions out of 200 for nonvisualization of ureters. In our study, since the ureters were identified in all the patients there was no conversion of laparoscopic surgery to laparotomy. So, this is an advantage in reducing the number of conversions.

CONCLUSION

To conclude, prophylactic placement of illuminated ureteric catheters can be of great help in identifying the ureters especially in difficult colorectal surgeries and can be performed with minimal morbidity to the patient.^{3,4} The

indications being the inflammatory bowel diseases, previous abdominal or pelvic surgeries, previous exposure to radiation, obesity and colorectal malignancies. Due to the intraoperative identification of ureters, the iatrogenic injury due to surgery and also the conversion rate to laparotomies is also minimized. Hence, use of prophylactic illuminated ureteric catheters is justified.

REFERENCES

1. Tsujinaka S, Wexner SD, Dasilva G, Sands DR. Prophylactic ureteric catheters in laparoscopic colorectal surgery. *Tech Coloproctol* 2008;12:45-50.
2. Agachan F, Joo JS, Weiss EG, Wexner SD. Intraoperative laparoscopic complications. *Dis Colon and Rectum* 1996;39: S14-19.
3. Bothwell WN, Bleicher RJ, Dent TL. Prophylactic ureteral catheterization in colon surgery. *Dis Colon Rectum* 1994;37: 330-34.
4. Kyzer S, Gordon PH. The prophylactic use of ureteral catheters during colorectal operations. *Am Surg* 1994;60:212-26.
5. Nam YS, Steven D, Wexner. Clinical value of prophylactic ureteral stent indwelling during laparoscopic colorectal surgery. *J Korean Med Sci* 2002;17:633-35.
6. Phipps JH, Tyrell NJ. Transilluminating ureteric stents for preventing operative ureteric damage. *Br J Obstet Gynaecol* 1992;99:81.
7. Sheikh FA, Khubchandani IT. Prophylactic ureteric catheters in colon surgery—how safe are they? Report of three cases. *Dis Colon Rectum* 1990;33:508-10.
8. Leff EL, Groff W, Rubin RJ, Eisenstat TE, Salavati EP. Use of ureteral catheters in colonic and rectal surgery. *Dis Colon Rectum* 1982;25:457-60.
9. Pandya S, Murray JJ, Collier JA, Rusin LC. Laparoscopic colectomy: Indications of conversion to laparotomy. *Arch Surg* 1999;134:471-75.

ABOUT THE AUTHORS

Manash Ranjan Sahoo (Corresponding Author)

Associate Professor, Department of Surgery, SCB Medical College Cuttack, Odisha, India, Phone: 06712414034, 09937025779 e-mail: manash67@gmail.com

T Anil Kumar

Postgraduate Student, Department of Surgery, SCB Medical College Cuttack, Odisha, India