

## CASE REPORT

# Primary Pancreatic Leiomyosarcoma: Laparoscopic Distal Pancreatosplenectomy

<sup>1</sup>Jitendra H Mistry, <sup>2</sup>Alankar Gupta, <sup>3</sup>Harshad Soni, <sup>4</sup>Atul Shah, <sup>5</sup>KS Patel, <sup>6</sup>Sanjiv Haribhakti

## ABSTRACT

Leiomyosarcoma of the pancreas is an extremely rare mesenchymal tumor, less than 50 cases have been reported till now. It accounts for 0.1% of pancreatic malignancy. Prognosis of this tumor is very poor, fewer are in resectable state. Surgical resection is the best possible option if feasible. We are reporting a case of leiomyosarcoma of pancreas underwent laparoscopic distal pancreatectomy.

**Keywords:** Laparoscopic distal pancreatectomy, Pancreatectomy, Pancreatic leiomyosarcoma, Mesenchymal tumor.

**How to cite this article:** Mistry JH, Gupta A, Soni H, Shah A, Patel KS, Haribhakti S. Primary Pancreatic Leiomyosarcoma: Laparoscopic Distal Pancreatectomy. *World J Lap Surg* 2014;7(2):101-102.

**Source of support:** Nil

**Conflict of interest:** None

## INTRODUCTION

Leiomyosarcoma of pancreas is an extremely rare mesenchymal tumor, less than 50 cases have been reported till now.<sup>1</sup> It accounts for 0.1% of pancreatic malignancy.<sup>2</sup> Prognosis of this tumor is very poor,<sup>3</sup> fewer are in resectable state. Surgical resection is the best possible option if feasible. We are reporting a case of leiomyosarcoma of pancreas underwent laparoscopic distal pancreatectomy.

## CASE REPORT

A 78-year-old gentleman visited our institution with complaint of pain at left upper quadrant of abdomen for 2 years with significant weight loss of 10 kg over a period of last 6 months and occasional vomiting. Examination revealed deep tenderness in left hypochondrium, no palpable mass or any other findings noted. Further evaluation in form of

contrast enhanced computed tomography (Fig. 1A) of abdomen revealed heterogeneously enhancing soft tissue lesion in distal body and tail of pancreas with solid and cystic components. Splenic vessels were encased within the tumor. Fat planes with surrounding organs were preserved. He underwent laparoscopic distal pancreatectomy, the specimen was retrieved within the Endobag from the Pfannenstiel incision (Figs 1B and C). The procedure took 177 minutes with around 100 cc of blood loss. Postoperative recovery was uneventful and was discharged on postoperative day 6. Histopathological examination of specimen revealed intermediate grade leiomyosarcoma. All the margins and lymphnodes were free of tumor and there was no lymphovascular involvement (Figs 2A to C). Immunohistochemistry examination showed tumor cells positive for smooth muscle actin (SMA) and h-Caldesmon. Now with 6 months of follow-up, patient is doing well without any recurrence or complications.

## DISCUSSION

Mesenchymal tumor of pancreas are extremely rare, as of now less than 50 cases of pancreatic leiomyosarcoma have been reported in literature,<sup>1</sup> many of them had metastatic tumor. Literature suggests that it usually occurs in patients over 50 years of age,<sup>4</sup> as it was in our case. Origin of these mesenchymal tumor is usually pancreatic duct or blood vessels within the pancreas.<sup>5</sup> These tumors more commonly arise in the body and tail of the pancreas<sup>5</sup> which was seen in our patient also. It usually metastasize via hematogenous route and common site of metastasis are lung, liver, brain and spine.<sup>1</sup> Surgery is the preferred treatment for pancreatic leiomyosarcoma which offers the best survival. There are very few cases of laparoscopic distal pancreatectomy reported for leiomyosarcoma in literature. Due to the magnification of vision we feel that oncological clearance is better with the laparoscopic approach. We did not find any difficulty while laparoscopic resection. Literature support laparoscopic distal pancreatectomy over open distal pancreatectomy for benign and low grade malignant tumors but the experience for high grade malignant is limited and needs long-term data.<sup>6</sup> Histopathological examination revealed pancreatic leiomyosarcoma. Most leiomyosarcomas are positive for SMA, desmin, caldesmon and vimentin.<sup>1</sup> In our case, the tumor was positive for SMA and h-Caldesmon.

<sup>1</sup>Consultant HPB and GI Oncosurgeon, <sup>2</sup>DNB Trainee

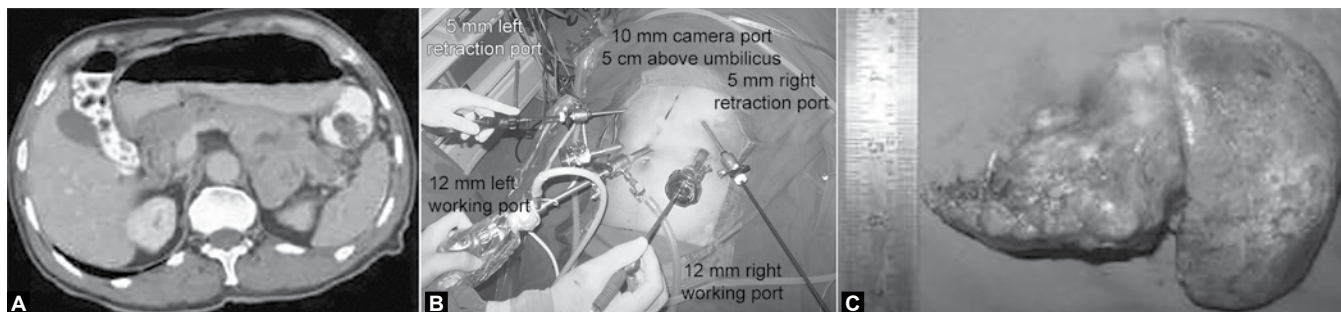
<sup>3</sup>Consultant GI and Laparoscopic Surgeon

<sup>4,5</sup>Consultant GI Surgeon, <sup>6</sup>Chairman

<sup>1</sup>Department of Surgical Gastroenterology, Baroda Laparoscopic Hospital, Vadodara, Gujarat, India

<sup>2-6</sup>Kaizen Hospital, Institute of Gastroenterology and Research Centre, Ahmedabad, Gujarat, India

**Corresponding Author:** Jitendra H Mistry, Consultant HPB and GI Oncosurgeon, Department of Surgical Gastroenterology Baroda Laparoscopic Hospital, Vadodara, Gujarat, India, e-mail: jittlap@gmail.com



**Figs 1A to C:** (A) Axial section CT scan of abdomen showing heterogeneously enhancing lesion in body and tail of pancreas with cystic components, (B) port placements and (C) specimen of distal pancreatectomy



**Figs 2A to C:** (A) H&E staining, (B) bizarre spindle cells and (C) h-Caldesmon

## CONCLUSION

Pancreatic leiomyosarcoma is very rare tumor with poor prognosis. Although, it is too early to recommend but laparoscopic resection of this tumor is feasible.

## REFERENCES

1. Riddle ND, Quigley BC, Browarsky I, Bui MM. Leiomyosarcoma arising in the pancreatic duct: a case report and review of the literature. *Case Report in Medicine*. Article ID 252364;2010: 1-4.
2. Hur YH, Kim HH, Park EK, Seoung JS, Kim JW, Jeong YY, Lee JH, Koh YS, Kim JC, Kim HJ, Cho CK. Primary leiomyosarcoma of the pancreas. *J Korean Surg Soc* 2011;81:s69-73.
3. American Cancer Society: facts and figures. Atlanta, GA; 2002.
4. Dimicoli S, Feugier P, Delaby P, et al. Granulocyte sarcoma of the pancreas without extrapancreatic involvement. *Presse Medicale* 2002;31(22):1024-1026.
5. Aihara H, Kawamura YJ, Toyama N, Mori Y, Konishi F, Yamada S. A small leiomyosarcoma of the pancreas treated by local excision. *HPB* 2002;4(3):145-148.
6. Jusoh AC, Ammori BJ. Laparoscopic versus open distal pancreatectomy: a systematic review of comparative studies. *Surg Endosc* 2012;26(4):904-913.