

# Percutaneous Transabdominal External Looped Needle for Peritoneal Closure in Laparoscopic Transabdominal Preperitoneal Inguinal Hernia Repair

<sup>1</sup>Ahmed E Lasheen, <sup>2</sup>AbdelRhman Sarhan, <sup>3</sup>Ayman Salem, <sup>4</sup>Tark Shiref

## ABSTRACT

**Introduction:** Transabdominal preperitoneal (TAPP) hernioplasty is a common procedure for groin hernia repair. The peritoneal closure after mesh placement is recommended to avoid mesh exposure to the viscera with the risk of adhesions and bowel incarceration into peritoneal defects. This study offers a novel technique for peritoneal closure by using external looped needle.

**Materials and methods:** During the period from April 2013 through August 2015, during laparoscopic inguinal hernia repair in 117 patients, the peritoneal closure was achieved by percutaneous transabdominal external looped needle. The needle was passed directly through the abdominal wall to close the peritoneal flaps using Vicryl no. 0. The mean follow-up period was 28 months.

**Results:** The age of this patients' group ranged from 20 to 66 years (mean age 47 years). The mean time to put one stitch was 1.8 minutes. No recurrence, pain, intestinal adhesion, obstruction, mesh bulging, or infection was recorded in this patients' group during the period of follow-up.

**Conclusion:** Our technique for peritoneal closure during laparoscopic inguinal hernia repair (TAPP) is effective, safe, and easy.

**Keywords:** Laparoscopic hernia repair, Looped needle, Peritoneal closure.

**How to cite this article:** Lasheen AE, Sarhan AR, Salem A, Shiref T. Percutaneous Transabdominal External Looped Needle for Peritoneal Closure in Laparoscopic Transabdominal Preperitoneal Inguinal Hernia Repair. *World J Lap Surg* 2016;9(2):58-62.

**Source of support:** Nil

**Conflict of interest:** None

## INTRODUCTION

Corbitt<sup>1</sup> first reported the technique of laparoscopic herniorrhaphy. Subsequently, transabdominal preperitoneal (TAPP) approach and totally extraperitoneal (TEP)

approach have become the most commonly used approaches. Transabdominal preperitoneal is an approved and common surgical procedure for groin hernia repair in adults, especially for bilateral and recurrent inguinal hernias after open repairs.<sup>2</sup> The procedure is performed by dissection of the preperitoneal space and a mesh repairs the hernia defect. The closure of the peritoneum after mesh placement must be performed uninterrupted and completely to avoid adhesion of viscera to the mesh and intestinal obstructions by bowel herniation through peritoneal defects into the preperitoneal space.<sup>3</sup> Incomplete peritoneal closure or its breakdown in laparoscopic preperitoneal hernia repair increases the risk of bowel obstruction. The optimal peritoneal closure method in TAPP remains debatable.<sup>4</sup> Here, we presented a novel procedure to close the peritoneal flaps during TAPP repair.

## MATERIALS AND METHODS

This study was done from April 2013 through August 2015 in General and Laparoscopic Surgery Department, Zagazig University Hospital, Egypt. One hundred seventeen patients were included in this article. This research was discussed and approved by the ethical committee of Zagazig University on January 2013. All information about the procedure were discussed with all the patients, and a written consent was taken from the patients for inclusion of their data in this study. The age of the patients ranged from 20 to 66 years (mean age, 49 years).

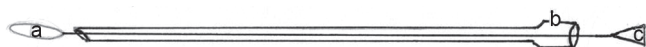## Surgical Technique

The TAPP procedure was performed in this patients' group under general anesthesia. As usual, the peritoneum was incised superiorly (3–4 cm) above the hernia defects. This incision extended from the medial umbilical ligament to the anterior superior iliac spine laterally. Then dissection of the hernia sac and complete exposure of the preperitoneal space were completed. The optimal mesh size was prepared to cover all myopectineal orifices, with an overlap of at least 3 to 5 cm from the margin of hernia defect(s) in all directions.<sup>5</sup> A suitable mesh (polypropylene mesh) goes to the preperitoneal space, where it was fixed

<sup>1-4</sup>General Surgeon

<sup>1-4</sup>Department of General and Laparoscopic Surgery, Faculty of Medicine, Zagazig University, Zagazig, Sharkia, Egypt

**Corresponding Author:** Ayman Salem, General Surgeon Department of General and Laparoscopic Surgery, Faculty of Medicine, Zagazig University, Zagazig, Sharkia, Egypt, e-mail: lasheenahmed@yahoo.com



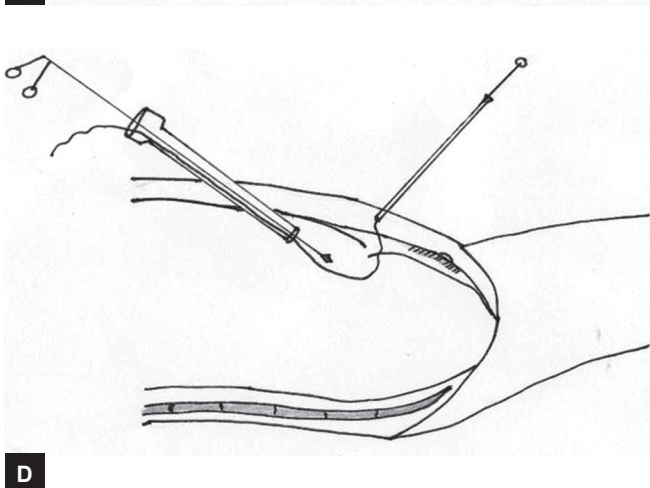
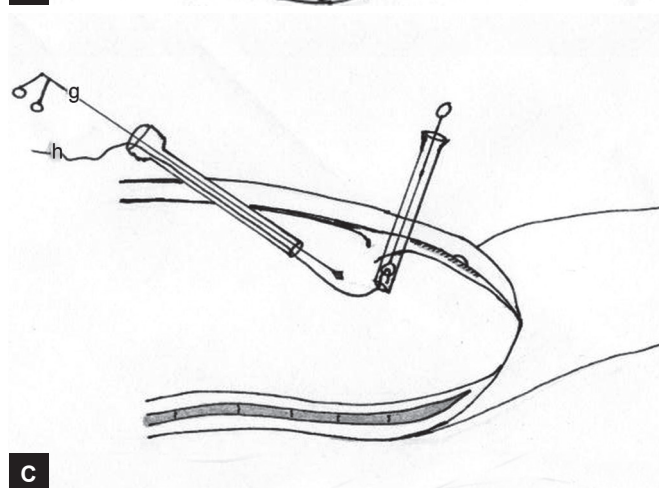
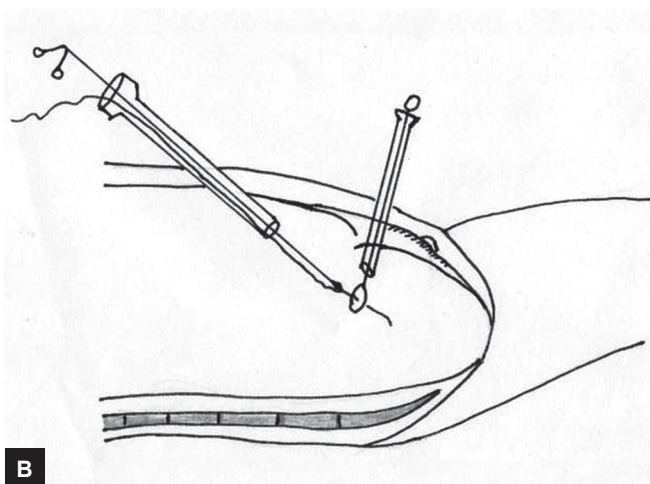
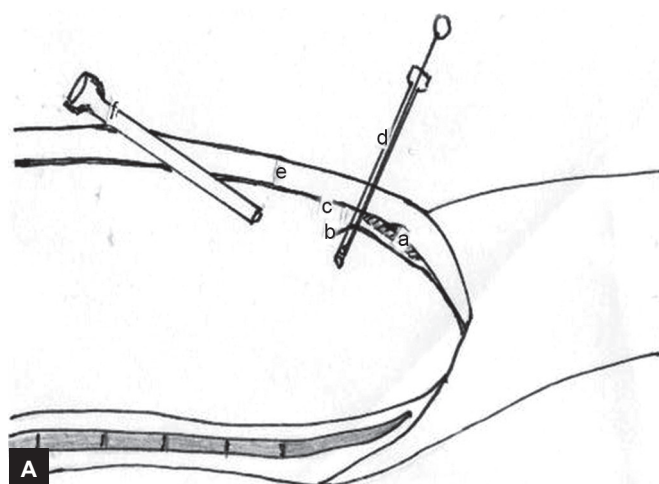
**Figs 1A to C:** (A) Loop at the tip of stent inside the needle; (B) long needle; and (C) metal stent inside the needle. This diagram of looped needle and our technique needs two-looped needles

in its position using Glubran 2 (Gem SRL, Viareggio, Italy). The peritoneum was closed using Vicryl no. 0 by helping external looped needle through anterior abdominal wall. The looped needle was prepared by the corresponding author, using long needle (15–20 cm) and inside it loop, which can be pushed or pulled through the needle sheath to hold or release the thread (Figs 1 A to C). The looped needle passes directly from the anterior abdominal wall to the lower peritoneal flap. Then, the inside loop was pushed to come out from the needle tip. One end of Vicryl no. 0 was passed through working port to put into the loop by laparoscopic forceps. The loop was pulled to hold Vicryl end inside the needle. The needle with Vicryl and loop inside it is withdrawn for some distance and redirected by pushing to pass through the inner

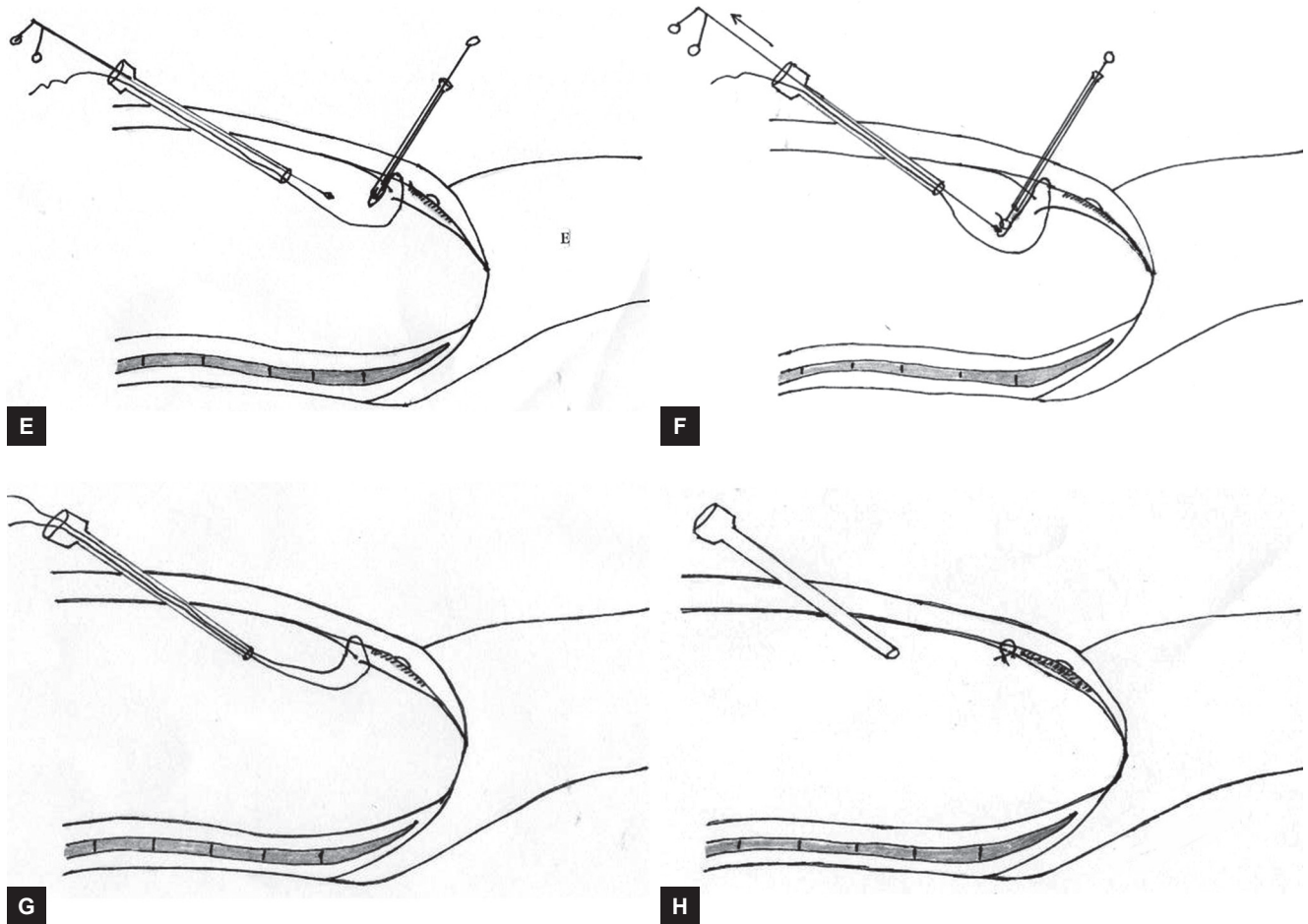
layer of abdominal wall and upper peritoneal flap. The loop was pushed to release the Vicryl end from needle tip. The Vicryl end was holed by laparoscopic forceps to bring it outside the abdominal cavity through the same working port. The suture was tied extracorporeal or intracorporeal (Figs 2A to H). Multiple sutures were put until good peritoneal closure was achieved (Figs 3A to C). The pneumoperitoneum was emptied under direct viewing with a laparoscope, and external pressure was applied to the inguinal region. The follow-up period ranged from 3 to 32 months (mean 28 months). The intra and postoperative complications were recorded.

## RESULTS

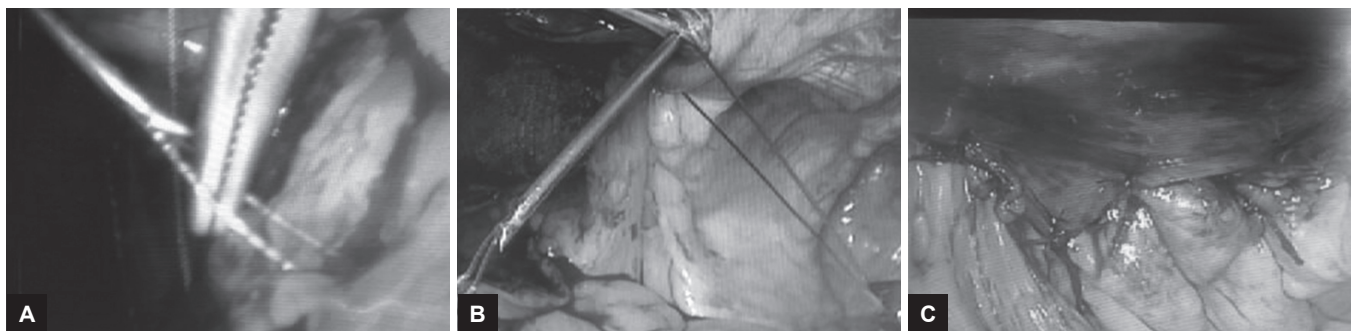
The mean age was 49.3 years (21–63 years), mean body mass index (BMI) was 24.5 (18.1–30.2), and mean operative time was 100 minutes (90–120 minutes). The mean time to put one suture by this technique was 1.8 minutes (1.5–3 minutes). The mean number of sutures to achieve good peritoneal closure was seven sutures (5–9 sutures).



**Figs 2A to D:** (A) The looped needle passes directly from abdominal wall to abdominal cavity, then through the lower peritoneal flap; (B) the stent and loop push through the needle to appear through the abdominal cavity. Then, the end of Vicryl no. 0 put inside the loop by using laparoscopic forceps; (C) the stent and the loop are withdrawn to hold the Vicryl end inside the needle. The needle is withdrawn to retract its tip at inner layer of anterior abdominal wall; and (D) Redirected and pushing of needle with Vicryl through inner layer of abdominal wall and upper peritoneal flap was done



**Figs 2E to H:** (E) The needle tip and Vicryl end appeared after passing through the upper peritoneal flap; (F) the suture was pushed through the needle to release the Vicryl end. Then, the Vicryl end was holed by laparoscopic forceps and withdrawn to bring the Vicryl end outside the abdominal cavity from the same working port; (G) one suture was complete, where the Vicryl passed through the lower peritoneal flap, inner layer of anterior abdominal wall, and upper peritoneal flap. The two limbs of suture came out through the working port; and (H) the suture was tied extracorporeally or intracorporeally



**Figs 3A to C:** (A) The looped needle passed through the abdominal wall and lower peritoneal flap. The Vicryl end was inserted inside the loop using laparoscopic forceps; (B) first suture is completed (one limb passes through the lower peritoneal flap, inner layer of anterior abdominal wall, and another limb through the upper peritoneal flap); and (C) nine sutures were needed to achieve good peritoneal closure in this case

The unilateral cases consisted of 77 indirect, 31 direct, 5 bilateral (all indirect), and 4 recurrent unilateral inguinal hernia after open hernia repair. Ninety-six patients (82%) returned to their usual activities in 1 week and 21 patients (17.9%) required up to 2 weeks. Twenty-three patients (19.7%) experienced mild inguinal pain for

3 weeks. The intra-abdominal pressure must be lowered and external pressure was applied to inguinal area during sutures tying to evacuate the gas from the preperitoneal space. No recurrence, chronic pain, intestinal adhesion, obstruction, mesh bulging, or infection was recorded in this patient group during the period of follow-up.



## DISCUSSION

The TAPP procedure has various technical difficulties and new devices have been developed that solve some of these problems.<sup>6</sup> Complete closure of the peritoneum after TAPP repair is an essential step of the operation to avoid on the one hand mesh exposure to the bowel with the risk of adhesion and bowel obstruction and on the other hand bowel incarceration through herniation into the preperitoneal space.<sup>7</sup> Penetrating devices, such as tacks, clips, staples, or strap devices should be avoided for mesh fixation and also for peritoneal closure, because of the risk of nerve injuries and adhesions.<sup>8,9</sup> LeBlanc<sup>10</sup> reported tack hernia as one of the complications after using tacks for mesh fixation or peritoneal closure in laparoscopic hernia repair. The peritoneal incision should be noninvasively approximated, for instance, using an absorbable, whose ends get fixed with absorbable clips.<sup>11</sup> The patients who had the peritoneum closed with a running suture had reduced incidence (from 0.8–0.1%) of small bowel obstruction from herniation through the peritoneal closure.<sup>12</sup> The suturing using intraperitoneal needle and other suturing devices is difficult and needs special port and good experience. Recently, uni- or bidirectional braided, self-anchoring, and knotless sutures are frequently used and offer time-saving work.<sup>6</sup> But, with a risk of cut through the peritoneal flaps can occur, producing gap and internal herniation through the preperitoneal space. Some authors reported small bowel obstruction after using a self-anchoring braided suture for peritoneal closure in TAPP repair.<sup>7</sup> Short stitches are generally recommended and barbed devices seem to be unsuitable for closure of a thin peritoneal layer, because this may lead to laceration and gapping of the peritoneum. Furthermore, grabbing sufficient amounts of peritoneal tissue with tensioning of the thread no more than required for adequate peritoneal closure is recommended to minimize the risk of exposition of the suture material to the viscera and to avoid bare endings of the thread, because the barbs generally have an affinity for bowel ingrowth.<sup>13–15</sup> Also, uncovered parts of the thread can occur due to suture penetration and are conceivable owing to peritoneal rupture can never be absolutely ruled out with the potential risk of severe complications such as a small bowel injury and obstruction.<sup>7</sup> Since 1995, the EndoStitch device (Covidien, USA) has been used for laparoscopic suturing.<sup>16,17</sup> Although the use of this device in TAPP has been reported,<sup>18</sup> it is not commonly used in herniorrhaphy. To date, there have been no suitable devices for peritoneal closure for beginners.<sup>6</sup> Small bowel obstruction after TAPP can be caused by displaced spiral tacks used for peritoneal closure, as reported by Fitzgerald et al,<sup>19</sup> with an incidence

of 0.2 to 0.5%. Additionally, the study by Kapiris et al. reported reduced complaints of persistent inguinal pain as they adopted a stable-free technique for mesh fixation and peritoneal closure.<sup>12</sup> In our technique for peritoneal closure, the suture (Vicryl no. 0) passed through the upper and lower peritoneal flaps with in between part of inner layer of anterior abdominal wall. So, this prevents cut through, or breakdown of peritoneal flaps and obliteration of any gap. The external looped needle was passed through the anterior abdominal wall directly over the peritoneal flaps, so no need of more ports or much instruments. The manipulation of this external looped needle is easy to a beginner laparoscopic surgeon also.

## CONCLUSION

Peritoneal closure by using an external looped needle is effective, easy, and needs no much instrumentations or experiences during TAPP repair of inguinal hernia.

## REFERENCES

1. Corbitt JD Jr. Laparoscopic herniorrhaphy. *Surg Laparosc Endosc* 1991 Mar;1(1):23-25.
2. Mahon D, Decadt B, Rhodes M. Prospective randomized trial of laparoscopic (transabdominal preperitoneal) *vs* open(mesh) repair for bilateral and recurrent inguinal hernia. *Surg Endosc* 2003 Sep;17(9):1386-1390.
3. McKay R. Preperitoneal herniation and bowel obstruction post laparoscopic inguinal hernia repair: case report and review of the literature. *Hernia* 2008 Oct;12(5):535-537.
4. Ross SW, Oommen B, Kim M, Walters AL, Augenstein VA, Heniford BT. Tacks, staples, or suture: method of peritoneal closure in laparoscopic transabdominal preperitoneal inguinal hernia repair effects early quality of life. *Surg Endosc* 2015 Jul;29(7):1686-1693.
5. Lasheen AE, Safwat K, Morsy M, Allam Z, Awad W. Modified transabdominal external needle for mesh size estimation in laparoscopic hernia repair. *Int J Surg* 2014 Oct;12(10):1074-1076.
6. Takayama S, Nakai N, Shiozaki M, Ogawa R, Sakamoto M, Takeyama H. Use of barbed suture for peritoneal closure in transabdominal preperitoneal hernia repair. *World J Gastrointest Surg* 2012 Jul 27;4(7):177-179.
7. Kohler G, Mayer F, Lechner M, Bittner R. Small bowel obstruction after TAPP repair caused by a self anchoring barbed suture device for peritoneal closure: case report and review of the literature. *Hernia* 2015 Jun;19(3):389-394.
8. Tolver MA, Rosenberg J, Juul P, Bisgaard T. Randomized clinical trial of fibrin glue versus tacked fixation in laparoscopic groin hernia repair. *Surg Endosc* 2013 Aug;27(8):2727-2733.
9. Lovisetto F, Zonta S, Rota E, Mazzilli M, Bardone M, Bottero L, Faillace G, Longoni M. Use of human fibrin glue (Tissucol) versus staples for mesh fixation in laparoscopic transabdominal preperitoneal hernioplasty: a prospective, randomized study. *Ann Surg* 2007 Feb;245(2):222-231.

10. LeBlanc KA. Tack hernia: a new entity. *JLS* 2003 Oct-Dec;7(4): 383-387.
11. Bittner R, Leibl BJ, Jager C, Kraft B, Ulrich M, Schwarz J. TAPP – Stuttgart technique and result of a large single center series. *J Minim Access Surg* 2006 Sep;2(3):155-159.
12. Kapisir SA, Brough WA, Royston CM, O'Boyle C, Sedman PC. Laparoscopic transabdominal preperitoneal (TAPP) hernia repair. A 7-year two-center experience in 3017 patients. *Surg Endosc* 2001 Sep;15(9):972-975.
13. Burchett MA, Mattar SG, McKenna DT. Iatrogenic intestinal and mesenteric injuries with small bowel volvulus following use of barbed suture during laparoscopic myomectomy. *J Laparoendosc Adv Surg Tech A* 2013 Jul;23(7):632-634.
14. Buchs NC, Ostermann S, Hauser J, Roche B, Iselin CE, Morel P. Intestinal obstruction following use of laparoscopic barbed suture: a new complication with new material? *Minim Invasive Ther Allied Technol* 2012 Sep;21(5):369-371.
15. Nemecek E, Negrin L, Beran C, Neemecek R, Hollinsky C. The application of the V-Loc closure device for gastrointestinal sutures: a preliminary study. *Surg Endosc* 2013 Oct;27(10):3830-3834.
16. Adams JB, Schulam PG, Moore RG, Partin AW, Kavoussi LR. New laparoscopic suturing device: initial clinical experience. *Urology* 1995 Aug;46(2):242-245.
17. Stringer NH. Laparoscopic myomectomy with the EndoStitch 10-mm laparoscopic suturing device. *J Am Assoc Gynecol Laparosc* 1996 Feb;3(2):299-303.
18. Shatari T, Nozawa K, Mieno K, Kodaira S. A new method of peritoneal closure following laparoscopic herniorrhaphy. *Surg Today* 1998;28(8):866-867.
19. Fitzgerald HL, Orenstein SB, Novitsky YW. Small bowel obstruction owing to displaced spiral tack after laparoscopic TAPP inguinal hernia repair. *Surg Laparosc Endosc Percutan Tech* 2010 Jun;20(3):e132-e135.