

Clipped vs Clipless Laparoscopic Cholecystectomy using the Ultrasonically Activated (Harmonic) Scalpel

¹Mohammed Hamdy Abdelhady, ²Asaad F Salama

ABSTRACT

Introduction: Laparoscopic cholecystectomy (LC) is the “gold standard” in the treatment of symptomatic gallbladder lithiasis. Monopolar hook, i.e., used currently is associated with some complications, such as the risk of thermal injuries and biliary complications. The ultrasonically activated (harmonic) scalpel has been increasingly used for dissection of the gallbladder and for division of vessels and the cystic duct, because it reduces the risk of thermal injuries with encouraging results.

Materials and methods: In this prospective study, 60 patients with gallbladder stones were planned to do LC. Patients were randomly assigned to either group I, including 30 patients who were subjected to traditional LC using cautery and clip applicator, or to group II, including 30 planned for clipless cholecystectomy using harmonic (Ethicon Endosurgery Ultracision Harmonic Scalpel, Generator 300).

Results: Neither minor nor major bile leaks were encountered in either groups. Similarly, no bile-duct injuries were encountered in the present study. The incidence of gallbladder perforation was less in group II. Operative time was significantly shorter in group II ($p=0.032$). Mean hospital stay was significantly less in group II ($p=0.046$). No statistically significant difference was found in the incidence of postoperative complications between both groups.

Conclusion: The harmonic shears are as safe and effective as the commonly used clip and cautery technique in achieving safe closure and division of the cystic duct in the LC. Further, it provides a superior alternative to the currently used high-frequency monopolar technology in terms of shorter operative time and lower incidence of gallbladder perforation.

Keywords: Clipless, Harmonic scalpel, Laparoscopic cholecystectomy.

How to cite this article: Abdelhady MH, Salama AF. Clipped vs Clipless Laparoscopic Cholecystectomy using the Ultrasonically Activated (Harmonic) Scalpel. *World J Lap Surg* 2017;10(1):17-21.

Source of support: Nil

Conflict of interest: None

^{1,2}Surgeon

¹Department of General and Laparoscopic Surgery, Jahra Hospital, Jahra, Kuwait

²Department of Hepatobiliary Surgery, Theodore Bilharz Research Institute, Cairo, Egypt

Corresponding Author: Mohammed Hamdy Abdelhady Surgeon, Department of General and Laparoscopic Surgery Jahra Hospital, Jahra, Kuwait, Phone: +96565589000, e-mail: drhamdysurg@yahoo.com

INTRODUCTION

The surgical management of gallstones has been revolutionized after the advent of laparoscopic cholecystectomy (LC). Laparoscopic cholecystectomy is the optimal treatment for patients with symptomatic cholelithiasis. It has a positive impact on the postoperative quality of the patient's life as well as optimal short- and long-term results.¹

The standard LC is commonly performed by means of specialized instruments. The electro-surgical dissector, hook, spatula, and/or scissors, using high-frequency monopolar electrocautery, have been used in most centers for dissection of gallbladder and adhesions. Metal clips were the most frequently used technique to achieve both cystic duct and artery closure. Alternative techniques for cystic duct closure have included sutures, either extracorporeal or intracorporeal knots. However, these alternatives are technically more difficult and, therefore, were used infrequently.²

Several reports have revealed several injuries and postoperative complications due to the current technology and technique of LC. These include deep tissue damage with possible distant tissue damage by the high-frequency electrocautery involving vascular and biliary structures in the vicinity of the cystic duct and artery, bile leakage due to slippage of the clips, and visceral and solid organ injuries due to frequent instrument exchange, which is sometimes performed without optic guidance.³

The ultrasonically activated (harmonic) scalpel was designed as a safe alternative to electrocautery for the hemostatic dissection of tissue and was introduced into clinical use nearly two decades ago. This innovative method of cutting tissue was based upon the coagulating and cavitation effects provided by a rapidly vibrating blade contacting various tissues.⁴

The resulting decrease in temperatures, smoke, and lateral tissue damage placed the harmonic scalpel in contrast to the effects seen with the more traditional electrocautery. In addition, the elimination of inadvertent, sometimes unrecognized, electrical arcing injuries with their potentially hazardous sequelae supported the role of the harmonic scalpel as a potentially safer instrument for tissue dissection.⁵

The replacement of scissors, dissector, and clips applicator with the harmonic scalpel gives the opportunity

to use a single instrument during the whole surgical procedure, limiting the number of passages through the trocars and consequently, reducing the possibility of causing lesions to the intraabdominal organs.⁶

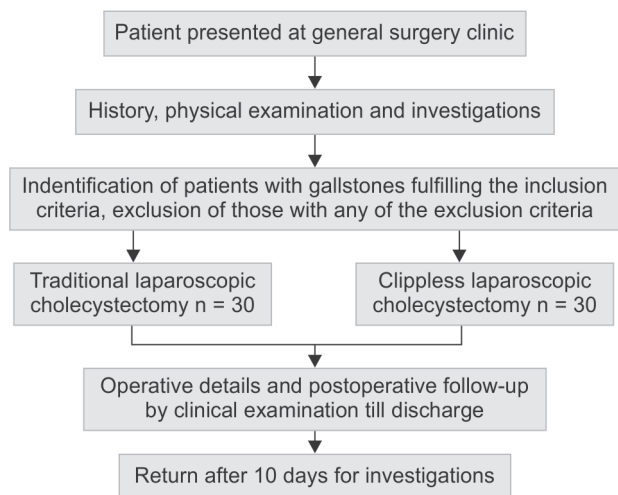
The aim of this work is to compare clipped *vs* clipless cholecystectomy using the ultrasonically activated (harmonic) scalpel as regards safety and feasibility, with the aim of developing possible nonsophisticated harmless technique and has been ethically approved.

MATERIALS AND METHODS

In this 2 years duration of prospective randomized study, 60 patients with gallbladder stones planned to do LC were randomly assigned using the sealed-envelope technique to either group I, including 30 patients who will be subjected to traditional LC using clip applicator, or be compared with group II, including 30 planned clipless cholecystectomy using harmonic (Ethicon Endosurgery Ultracision Harmonic Scalpel, Generator 300).

Patients with symptomatic gallstones disease proved by ultrasound (U/S) were the only selection criterion. Exclusion criteria include contraindication of LC, abnormal laboratory investigations, and unfavorable anatomy intraoperatively.

Study Pathway



Preoperative assessment consisted of history taking, general and local examination. Preoperative investigations include a complete blood count, international normalized ratio, assessment of liver and renal function (ALT, total bilirubin, direct bilirubin, albumin, alkaline phosphatase, serum creatinine), and pelvi-abdominal U/S.

Operative Technique

Group I performed traditional LC. The anesthetized patient was placed supine on the operating table. The

pneumoperitoneum was achieved with a closed (Verres needle) method, via an infraumbilical transverse incision. The peritoneal cavity was carefully insufflated with warmed CO₂ to a pressure of 12 mm Hg. A 30° laparoscope was introduced via the umbilical port and the peritoneal cavity was inspected. The second 10-mm port was inserted under direct vision in the midline in the epigastrium, passing just to the right of the falciform ligament, toward the gallbladder. Two 5-mm ports were introduced, one in the right mid-clavicular and one in the right mid-axillary line, angled toward the gallbladder. Patient was placed in a steep reverse Trendelenburg position with a left down tilt. Any adhesions between the gallbladder and omentum or duodenum were divided, and the gallbladder fundus grasped and retracted toward the patient's right shoulder. A 5-mm grasper was then placed on Hartmann's pouch and, was retracted to the patient's right, opening up the porta hepatis. The anterior and posterior peritoneum over the neck of the gallbladder was then divided with a diathermy hook, and Calot's triangle was carefully dissected. Once the cystic duct and cystic artery are clearly identified, the cystic artery was clipped and divided. The cystic duct was then clipped proximally and distally and then divided. The gallbladder was carefully dissected off the gallbladder bed. Prior to the final disconnection, and using the gallbladder as a retractor, hemostasis of the gallbladder bed was secured and the positions of the clips placed on the cystic duct and the cystic artery were checked. The dissection was then completed and the gallbladder was retrieved via the epigastric port. In case of gallbladder perforation, it was retrieved in a bag, with every effort made to aspirate the bile and recover any spilt stones. The pneumoperitoneum was then released and the ports were removed. The wounds were infiltrated with local anesthetic and closed with skin clips.

Group II performed LC using harmonic ACE shears as single working instrument till skeletonization of both cystic duct and artery (Figs 1 and 2), for closure and division of both the cystic duct and artery, harmonic was set at the power level "2," which is translated into less cutting and more coagulation. First, it was ascertained that there were no microcalculi in the lumen of the cystic duct by moving the jaws of the harmonic ACE shears up and down. Second, the cystic duct was inserted between the jaws at a safe distance from common bile duct to avoid damage to this structure; then the jaws were closed until a click was heard. Third, the harmonic was activated at the power level "2," and during this phase, great care was taken to avoid stretching or rotating cystic duct but rather to keep it still until the gallbladder was detached from the cystic duct (Figs 3 and 4). Fourth, the cutting points of the cystic duct were checked for any bile leakage.

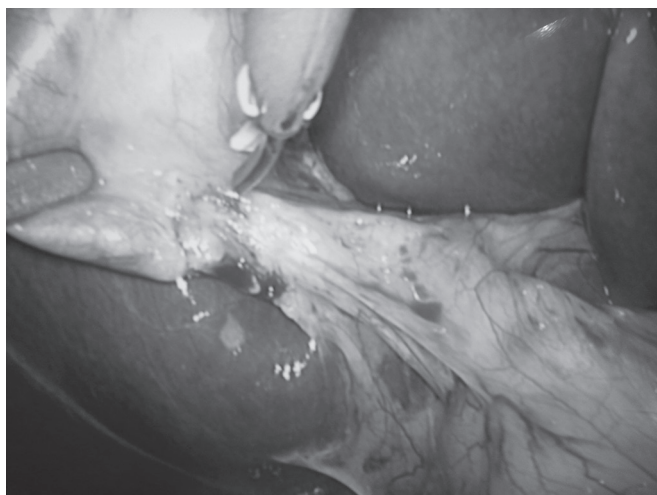


Fig. 1: Dissection of Calot's triangle

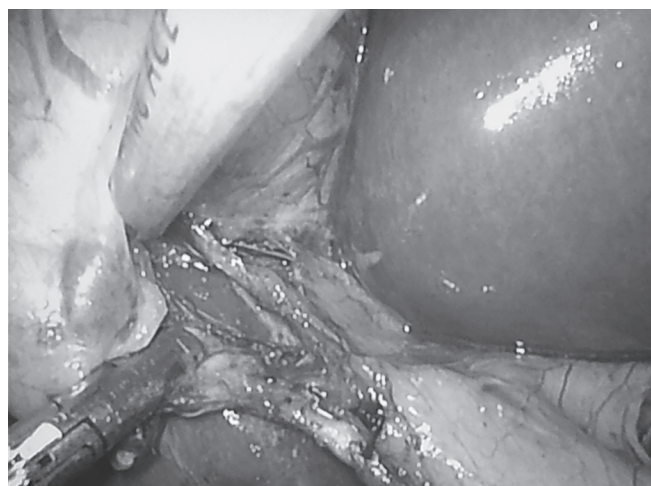


Fig. 2: Skeletonization of cystic duct and artery

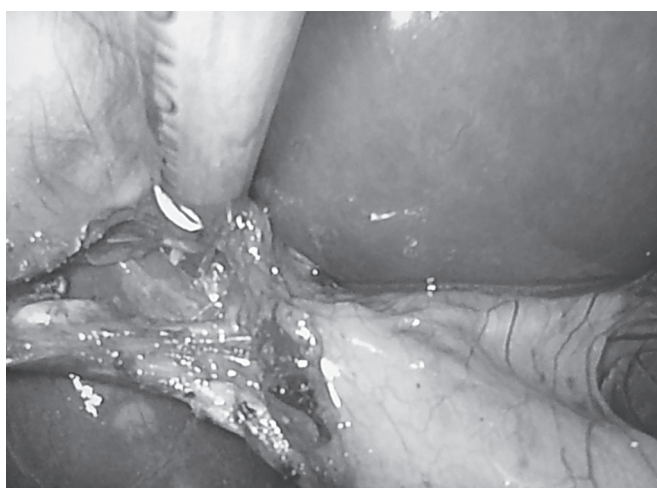

Fig. 3: Coagulation and cutting of cystic artery

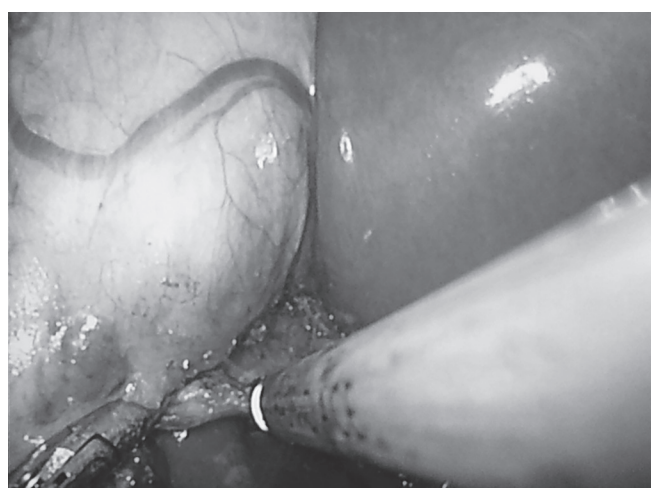

Fig. 4: Coagulation and cutting of cystic duct

Finally, dissection of gallbladder bed and extraction of gallbladder done.

Operative data including the operative time, intraoperative difficulties, and postoperative complications in the form of bile leak and wound infection were recorded.

The postoperative analysis included postoperative follow-up in the form of clinical examination (pulse, temperature, blood pressure, respiratory rate, and abdominal examination) till discharge and postoperative investigations in the form of full blood count, assessment of liver (ALT, total bilirubin, direct bilirubin and alkaline phosphatase), pelvi-abdominal U/S at day 10 with special attention to the presence or absence of any subhepatic collection, hospital stay. Patients were discharged once tolerating oral feeding and clinically free to return at day 10 for laboratory investigations and pelvi-abdominal U/S.

Statistical Analysis

The statistical analysis of data was done by using Excel program for figures and Statistical Package for the Social

Sciences (Inc., Chicago, IL) program, version 17. The description of the data was done in the form of mean \pm SD for quantitative data and frequency and proportion for qualitative data. The analysis of the data was done to test statistical significant difference between groups. For quantitative data, Student's t-test was used to compare between two groups. Chi-square test was used for qualitative data and odds ratio for risk assessment.

RESULTS

This study included 60 patients, 46 females (76.7%) and 14 males (23.3%) with symptomatic gallstone disease, with a mean age of 39 years (19–79 years). Following randomization, patients were assigned to either group I, including 30 patients who was subjected to traditional LC using clip applicator, or be compared with group II, including 30 patients who was subjected to clipless cholecystectomy using harmonic scalpel. No statistically significant difference was found in age, sex, and associated comorbidities between both groups (Table 1).

Table 1: Demographic data, clinical characteristics, and associated comorbidities

	Overall (n=60)	Group I (n=30)	Group II (n=30)	p-value
Age "years"				
Range	[19:79]	[23:58]	[19:79]	0.81
Mean±SD	39±11.6	39.5±10.6	38.8±12.7	
Sex no. of patients (%)				
Female (%)	46 (76.7%)	24 (80%)	22 (73.3%)	0.54
Male (%)	14 (23.3%)	6 (20%)	8 (26.7%)	
<i>D.M.</i>	17 (28.3%)	9 (30%)	8 (26.7%)	0.77
Hypertension	13 (21.7%)	6 (20%)	7 (23.3%)	0.75
Ischemic heart disease	4 (6.7%)	2 (6.7%)	2 (6.7%)	1

Table 2: Operative data

	Group I	Group II	p-value
Operative time			
Range	[38:115]	[28:98]	0.032*
Mean	58.6±19	48.4±16.9	
Operative time without gallbladder perforation			
Range	[38:90]	[28:85]	0.024*
Mean	55.5±14.1	46.6±14.3	
Operative time with gallbladder perforation			
Range	[45:115]	98	0.85
Mean	86.6±36.8	98	
Gallbladder perforation	3 (10%)	1 (3.3%)	0.31

The procedure was completed laparoscopically in both groups. The mean operative time in group I was significantly longer than group II with mean (58.6 vs 48.4 min) (p = 0.032). The incidence of gallbladder perforation is higher in group I than group II (20 vs 6.66%), (p = 0.31). Gallbladder perforation has been found to lengthen the operative time in both studied groups (p = 0.85) (Table 2).

Neither minor nor major bile leaks were encountered in either group. Similarly, no bile-duct injuries were encountered in the present study. Wound infection was same in groups I and II (3.3%) of no statistical significance (Table 3).

Early discharge on "day 1" occurred in 27 patients in group II (90%) vs 21 in group I (70%), postoperative discharge on day 2 was higher in group I than in group II [8 (26.7%) vs 3 (10%)], delayed discharge of more than 2 days was only for one patient in group I [1 (3.3%) (p-value = 0.13)]. The mean hospital stay in group II (1.1±0.30) is less than that in group I (1.33±0.54) with statistical significance (p-value = 0.046) (Table 4).

Three months after the procedure, all patients were doing well with uneventful follow-up.

DISCUSSION

Several studies have confirmed the effectiveness and safety of the use of the ultrasonically activated scalpel for

Table 3: Postoperative complications

	Overall (n=60)	Group I (n=30)	Group II (n=30)	p-value
Biliary leak	0	0	0	
Wound infection	2 (3.3%)	1 (3.3%)	1 (3.3%)	1

Table 4: Hospital stay

	Overall (n=60)	Group I (n=30)	Group II (n=30)	p-value
1 day	48 (80%)	21 (70%)	27 (90%)	0.13
2 days	11 (18.3%)	8 (26.7%)	3 (10%)	
More than 2 days	1 (1.7%)	1 (3.3%)	0	
Mean±SD	1.21±0.45	1.33±0.54	1.1±0.30	0.046*

dissection of the gallbladder, but only a few authors^{3-5,7,9,10} have examined its efficacy in the closure of the cystic artery and duct. In 1999, the use of ultrasonically activated shears for both dissection and closure-division of the cystic duct and artery was first reported.⁸

In our study, the use of the harmonic shear was associated with lower incidence of gallbladder perforation, compared with traditional method. Operative time was prolonged in operations complicated by gallbladder perforation in both groups as stone spillage and bile loss leads to obstruction of laparoscopic visual field and frequent exchange in instruments.

Operative time was shorter in group II than group I. This has many potential advantages, including reducing the overall anesthetic time and increasing the number of cases that can be done on an average operative list. Similar finding was reported by Khan et al⁹ and Gelmini et al.¹⁰

In our study, neither minor nor major bile leaks were encountered in either groups, and this could be explained partially by small number of patients in each group, although similar findings were reported by Tebala³ and Bessa et al.⁵

In the present study, as well as in the Westervelt,⁴ Tebala,³ and Khan et al⁹ studies, the harmonic shears were applied to only one site on the cystic duct where sealing and division were achieved with no bile leaks from the cystic duct stump encountered in any of the three studies. It is our belief that a double application of the harmonic shears to the cystic duct is unnecessary and may be an unsafe practice.

The greater cost of the harmonic scalpel, when compared with the cost of an electrocautery probe, has been regarded as a potential disadvantage. Although this difference is significant at the present time, however, we feel that LC, using the harmonic scalpel, is cost-effective when considering that we use fewer overall instruments and are able to carry out more procedures on an average list as a result of the shorter operative time.

The overall hospital stay in group II is less than group I, similar to the Janssen et al¹¹ study which reported

that the harmonic scalpel was associated with shorter operative times, fewer overnight hospital stay, and lower pain scores.

CONCLUSION

The harmonic scalpel is as safe and effective as the commonly used clip and cautery technique in achieving safe closure and division of the cystic duct in the LC. Further, it provides a superior alternative to the currently used high-frequency monopolar technology in terms of shorter operative time and lower incidence of gallbladder perforation.

REFERENCES

1. Lichten JB, Reid JJ, Zahalsky MP, Friedman RL. Laparoscopic cholecystectomy in the new millennium. *Surg Endosc* 2001 Aug;15(8):867-872.
2. Rohatgi A, Widdison AL. An audit of cystic duct closure in laparoscopic cholecystectomies. *Surg Endosc* 2006 Jun;20(6):875-877.
3. Tebala GD. Three-port laparoscopic cholecystectomy by harmonic dissection without cystic duct and artery clipping. *Am J Surg* 2006 May;191(5):718-720.
4. Westervelt J. Clipless cholecystectomy: broadening the role of the harmonic scalpel. *JLS* 2004 Jul-Sep;8(3):283-285.
5. Bessa SS, Al-Fayoumi TA, Katri KM, Awad AT. Clipless laparoscopic cholecystectomy by ultrasonic dissection. *J Laparoendosc Adv Surg Tech A* 2008 Aug;18(4):593-598.
6. Ramos AC, Ramos MG, Galvao Neto MP, et al. Total clipless cholecystectomy by means of harmonic sealing. *Arq Bras Cir Dig* 2015;28(1):53-56.
7. Hüscher CG, Lirici MM, Di Paola M, Crafa F, Napolitano C, Mereu A, Recher A, Corradi A, Amini M. Laparoscopic cholecystectomy by ultrasonic dissection without cystic duct and artery ligation. *Surg Endosc* 2003 Mar;17(3):442-451.
8. Hüscher CG, Lirici MM, Anastasi A, Sansonetti A, Amini M. Laparoscopic cholecystectomy by harmonic dissection. *Surg Endosc* 1999 Dec;13(12):1256-1257.
9. Khan JS, Qureshi U, Fatima Z, Hassan H, Khan MM, Iqbal M. Clipless laparoscopic cholecystectomy by ultrasonic. *Ann Pak Inst Med Sci* 2012;8(4):229-231.
10. Gelmini R, Franzoni C, Zona S, Andreotti A, Saviano M. Laparoscopic cholecystectomy with harmonic scalpel. *JLS* 2010 Jan-Mar;14(1):14-19.
11. Janssen IM, Swank DJ, Boonstra O, Knipscheer BC, Klinkenbijn JH, van Goor H. Randomized clinical trial of ultrasonic versus electrocautery dissection of the gallbladder in laparoscopic cholecystectomy. *Br J Surg* 2003 Jul;90(7):799-803.