

Laparoscopic Cerclage in Pregnant and Nonpregnant Uterus: Emerging Need to change Conventional Management Approach

Oluwole E Ayegbusi

ABSTRACT

Cervical incompetence/insufficiency occurs in 0.1 to 1% of all pregnancies, and, traditionally, management involves transvaginal cervical cerclage. In some situations, however, such as in extremely short cervix following cone biopsy, congenital absent cervix, and in cases where transvaginal cerclage fails or is technically impossible, transabdominal approach via laparotomy is usually done. Recent data suggest that these methods should be reviewed in light of the advantages seen in the developments of minimal access surgical techniques.

This article, therefore, compares both approaches (conventional and laparoscopy) and, in particular, discusses the use of laparoscopy in the management of cervical incompetence/insufficiency both in pregnant and nonpregnant uterus.

Keywords: Cerclage, Cervical insufficiency, Laparoscopy.

How to cite this article: Ayegbusi OE. Laparoscopic Cerclage in Pregnant and Nonpregnant Uterus: Emerging Need to change Conventional Management Approach. *World J Lap Surg* 2017;10(1):35-39.

Source of support: Nil

Conflict of interest: None

INTRODUCTION

The joy of motherhood is to be able to achieve spontaneous pregnancy and, most importantly, carry such pregnancy to term and deliver a healthy baby. One of the factors that prevents such expected natural cycle is frequent midtrimester miscarriages, which sometimes is due to cervical insufficiency.

It is seen in almost 1% of all pregnancies, with a high recurrence rate of 30%, and mainly results in abortion or premature delivery in the second and third trimester respectively.¹⁻³

Cervical incompetence/insufficiency can be described as the inability to endure a pregnancy till term due to a functional or structural defect of the cervix.¹⁻³ Most of the affected women have a classic history of acute, painless

cervical dilatation followed by premature rupture or prolapse of the membranes⁴ without any warning signs, such as low abdominal discomfort. This can be very traumatic to most women, with majority usually saying, "Doctor, how do I know is coming."

Various surgical techniques and approaches have been used to prolong pregnancy and improve perinatal outcome. The surgical treatment, cervical cerclage, was first described in 1955 by Lash and Lash and later by Shirodkar.⁴⁻⁶ Most cerclage operations for cervical incompetence are performed transvaginally¹ and are usually done around 14 weeks.

The current most frequently used and most simple technique of transvaginal cerclage, a purse string suture around the body of the cervix, was described in 1957 by McDonald.^{1,6,7}

Cerclage can be performed both in the pregnant and the nonpregnant state. In some conditions, such as an extremely short, deformed, or absent cervix, the vaginal approach does not allow placement of the cerclage, and, hence, transabdominal cerclage via laparotomy is usually employed. The first transabdominal cerclage by laparotomy was reported in 1965 by Benson et al^{1,5,8}; subsequently, transabdominal cerclage by laparotomy has since been done for cases that cannot be performed via transvaginal approach with improved outcomes.

The following are some of the indications for transabdominal cerclage: Congenitally short or absent cervix, extensively amputated cervix, marked scarring of the cervix, deeply notched multiple cervical defects, penetrating lacerations of the fornix, subacute cervicitis, wide or extensive cervical conization, cervicovaginal fistulas, and one or more previous transvaginal cerclage failures.^{1,4} The contraindications for transabdominal cerclage are bulging membranes, ruptured membranes, intrauterine infections, vaginal blood loss, intrauterine fetal death, labor, and life-threatening maternal condition. The obvious disadvantage of this approach is that a laparotomy is required for the placement of the band and for delivery¹; this could be done twice with attending complications. It was these realities and others that led to the first successful cases of laparoscopic transabdominal cerclage, which were published in 1998.^{9,10} Evidence now abounds in recent years with successful reports about treating cervical insufficiency

Senior Registrar

Department of Obstetrics and Gynaecology, Obafemi Awolowo University Teaching Hospitals, Ile-Ife, Osun State, Nigeria

Corresponding Author: Oluwole E Ayegbusi, Senior Registrar
Department of Obstetrics and Gynaecology, Obafemi Awolowo University, Teaching Hospitals, Ile-Ife, Osun State, Nigeria
Phone: +234805757812, e-mail: folaturabbny@gmail.com

with cerclage placed via laparoscopy both in pregnant and nonpregnant phases.^{5, 11-13}

The objectives of this review are to:

- Ascertain the advantages of laparoscopic cerclage over conventional laparotomy cerclage;
- Review the safety of laparoscopic cerclage over conventional laparotomy cerclage;
- Briefly describe the procedure of laparoscopic transabdominal cerclage.

MATERIALS AND METHODS

Searches in the literature on laparoscopic cervical cerclage were conducted via PubMed, Google Scholar, EMBASE, Medline, and Cochrane library database. No language restriction was applied to the searches.

Procedure of Laparoscopic Cerclage

Laparoscopic transabdominal cerclage is commonly performed in a nonpregnant state.

Preparation

Under general anesthesia, the patient is placed in dorsal lithotomy position. After inserting a Foley catheter in the urinary bladder and a uterine manipulator (for patients that are not pregnant), a subumbilical incision for the laparoscope is made by using the closed Verres technique. Two more trocars at the right and left lower abdominal quadrants are placed, after insufflating with appropriate CO₂ gas. *Step 1:* Development of the paravesical and vesicouterine spaces.

For the nonpregnant uterus, a solution with vasopressin (VasopressineR 20 Units/1 mL, American Regent Inc., Shirley, New York, diluted in 50 cc 0.9% NaCl) is injected under the peritoneum of the uterovesical reflection and lateral of the lower uterus. This facilitates the bloodless separation of the bladder from the cervix.

Step 2: Creation of windows in the broad ligament

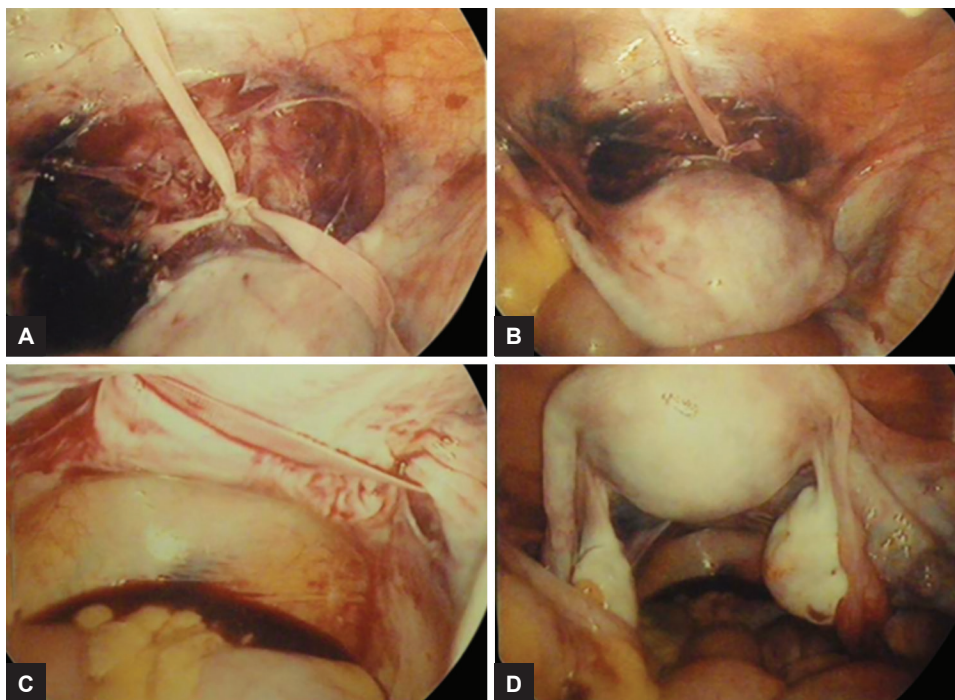
Subsequently, branches of the uterine artery and vein are identified, so that the cardinal ligament can be perforated from anterior to posterior by a straight atraumatic clamp in an avascular area on the median side of the uterine vessels on both sites. The instrument is guided in such a way that the perforation at the posterior side is medially located from the uterosacral ligament.

Step 3: Placement of suture material through the broad ligament windows.

A polyester tape (5 mm width MersileneR, Ethicon, Johnson and Johnson), the needles removed, is passed into the pelvis and pulled through the holes with both free ends of the tape at the anterior side. Because the windows are medially located from the uterosacral ligament on both sides and a small purchase of cervical tissue is taken, there is no need for further anchoring of the suture on the uterus. Therefore, the needles are redundant and can be removed.

Step 4: Securing the cerclage by knots

Finally, three knots are made in the tape at the anterior side of the uterus resulting in a tension-free loop around the cervix above the insertion of the uterosacral ligament (Figs 1A to D).



Figs 1A to D: The cerclage can be seen passing on the posterior side of the cervix, medially of the uterosacral ligaments with the knot on the anterior side

RESULTS

All the cases of patients available within the limit of the search engines that underwent laparoscopic cerclage between 2008 and 2015 were reviewed. This in total involves pregnant and nonpregnant patients – of 403 patients of various indications, 88 (21.8%) were pregnant when the procedure was done, while 315 (78.2%) were not pregnant.

The results are shown in Table 1.¹⁵⁻²⁵ The number of patients that were treated each year ranges from 1 to 101, with majority of the cases done before pregnancy, and, in all, reveals very minimal intraoperative complications which were seen in only three cases – 2009, 2013, and 2014, with intraoperative complications of 10.7, 4.5, and 1.6% respectively; others did not record any form of complications. There were no severe complications like infection, severe hemorrhage, and injury of peripheral organs.

The mean gestational ages at delivery were grossly normal, ranging between 35 and 38 weeks except for only one of the cases that was reported by Murray et al, in 2011, with the delivery at 28 weeks. It was only one case, and the cerclage was done before pregnancy.

The survival rate at birth ranges between 75 and 100%.

All the surgeries were successful without assistance or converting to laparotomy.

DISCUSSION

Cervical incompetence has been traditionally treated with transvaginal cerclage over the years, and this has been the treatment of choice for the last 50 years.^{3,14}

In the majority of patients in whom cervical cerclage is indicated, it can be achieved through transvaginal procedure. In this case, the suture can be removed at 37 weeks, and a vaginal delivery can be aimed for, if there is no contraindication to vaginal delivery.

The transabdominal approach of cerclage in general (laparotomy and laparoscopy) is essential for adequate therapy in a selected population of women. This includes those individuals in whom a satisfactory transvaginal cerclage is not technically feasible – a congenital short or absent cervix, an extensively amputated cervix, marked scarring of the cervix, and multiple deep cervical defects, and also a previously failed vaginal cerclage has been regarded as a good indication for transabdominal cerclage.

The choice of transabdominal cerclage now depends on so many factors: The expertise and availability of technical knowhow, the institutional norms, evident cumulative fetal survival rate, ranging from 75 to 100%, favorable gestational age at delivery, and the current and consistent successful transabdominal laparoscopic cerclage that has been reported over the last three decades,

Table 1: Results of laparoscopic cervical cerclage done between 2009 and 2015

<i>Cerclage by laparoscopy</i>	<i>Patient no.</i>	<i>Time of surgery</i>	<i>Pregnant no.</i>	<i>Intraoperative complication rate (%)</i>	<i>Average gestational age at birth</i>	<i>Survival rate at birth (%)</i>
Liddell and Lo ¹⁵	11	Before pregnancy	10	0	ND	100
Whittle et al ¹⁶	65	34 before pregnancy 31 during pregnancy	67	10.7	35.8	80
Fechner et al ¹⁷	1	During pregnancy	1	0	37	100
Carter et al ¹⁸	12	7 before pregnancy 5 during pregnancy	12	0	ND	75
Pereira et al ¹⁹	1	Before pregnancy	2	0	38	100
Palacio et al ²⁰	2	Before pregnancy	ND	0	ND	ND
Murray et al ²¹	1	Before pregnancy	1	ND	28	100
DaCosta et al ²²	3	Before pregnancy	2	0	37	100
Riiskjaer et al ¹²	52	Before pregnancy	45	0	37.4	83.3
El-Nashar et al ²³	4	During pregnancy	4	ND	37.3	100
Salmeen and Parer ²⁴	66	Before pregnancy	36	4.5	37.2	90
Ades et al ²⁵	64	61 before pregnancy 3 during pregnancy	35	1.6	35.8	95.8
Shin et al ³	1	During pregnancy	1	0	35	100
Luo et al ¹¹	19	Before pregnancy	15	0	38.4	90
Chen et al ⁴	101	58 before pregnancy 43 during pregnancy	93	0	38.2	95

ND: No data

with minimal complications. There is an increasing need to start giving consideration to transabdominal laparoscopic cerclage.

The laparoscopic approach has further advantages of obviating the need for a laparotomy, reducing the abdominal wall trauma and the recovery time, with short hospital stay, avoiding repeated laparotomy, and indirectly reducing *de novo* postoperative adhesion formation; this aspect cannot be overemphasized, which most obstetricians detest.

Finally, laparoscopic procedures, especially gasless ones,¹ appear to be safe for both the mother and fetus. The procedure also avoids the risk of ascending lower genital tract infections, which are occasionally seen in transvaginal cerclage and could result in abortions or preterm delivery as the case may be.

CONCLUSION

In patients that are indicated, laparoscopic approach to cervical cerclage placement is an effective and safe adjunct to the treatment of cervical insufficiency, as evident by the obstetric outcomes. Also, laparoscopic cerclage may also be a superior method in terms of surgical outcomes, as suggested by several studies.

However, there is still need for more studies and, especially, considering fetal outcomes of laparoscopic cerclage and laparotomy cerclage with transvaginal cerclage, there is a need to do more in terms of increasing expertise in order to reduce complications to the barest minimum. It may be advisable to consider laparoscopic transabdominal cerclage before pregnancy, i.e., as an interval procedure.

Apart from those stated above, the following questions may, therefore, need answers in future studies:

- Should cerclage placed via laparoscopy be done before or after pregnancy?
- Will there be an effect on fertilization if laparoscopic cerclage is done before pregnancy?

ACKNOWLEDGMENT

The author appreciates the authors of all the papers reviewed as acknowledged in the references. The author is particularly grateful to the entire staff of World Laparoscopy Hospital, Gurgaon, India, under the leadership of a wonderful teacher, Professor RK Mishra.

REFERENCES

1. Gallot D, Savary D, Laurichesse H, Bournazeau JA, Amblard J, Lémery D. Experience with three cases of laparoscopic transabdominal cervico-isthmic cerclage and two subsequent pregnancies. *BJOG* 2003 Jul;110(7):696-700.
2. ACOG Practice Bulletin No.142: Cerclage for the management of cervical insufficiency. *Obstet Gynecol* 2014 Feb;123(2 Pt 1):372-379.
3. Shin JE, Kim MJ, Kim GW, Lee DW, Lee MK, Kim SJ. Laparoscopic transabdominal cervical cerclage: case report of a woman without exocervix at 11 weeks gestation. *Obstet Gynecol Sci* 2014 May;57(3):232-235.
4. Chen Y, Liu H, Gu J, Yao S. Therapeutic effect and safety of laparoscopic cervical cerclage for treatment of cervical insufficiency in first trimester or non-pregnant phase. *Int J Clin Exp Med* 2015 May;8(5):7710-7718.
5. Marilien G, Yves J, Jérôme C. Laparoscopic transabdominal cerclage. *Surg Sci* 2013 Apr;4(4):231-235.
6. Shirodkar VN. A new method of operative treatment for habitual abortion in the second trimester of pregnancy. *Antiseptic* 1955;52(2):299-300.
7. McDonald IA. Suture of the Cervix for inevitable miscarriage. *J Obstet Gynaecol Br Emp* 1957 Jun;64(3):346-350.
8. Benson RC, Durfee RB. Transabdominal cervicouterine cerclage during pregnancy for the treatment of cervical incompetency. *Obstet Gynecol* 1965 Feb;25(2):145-155.
9. Scibetta JJ, Sanko SR, Phipps WR. Laparoscopic transabdominal cervicoisthmic cerclage. *Fertil Steril* 1998 Jan;69(1):161-163.
10. Lesser KB, Childers JM, Surwit EA. Transabdominal cerclage: a laparoscopic approach. *Obstet Gynecol* 1998 May;91(5 pt 2):855-856.
11. Luo L, Chen SQ, Jiang HY, Niu G, Wang Q, Yao SZ. Successful treatment of cervical incompetence using a modified laparoscopic cervical cerclage technique: a cohort study. *Eur J Obstet Gynecol Reprod Biol* 2014 Aug;179:125-129.
12. Riiskjaer M, Petersen OB, Uldbjerg N, Hvidman L, Helmig RB, Forman A. Feasibility and clinical effects of laparoscopic abdominal cerclage: an observational study. *Acta Obstet Gynecol Scand* 2012 Nov;91(11):1314-1318.
13. Nicolet G, Cohen M, Begue L, Reyftmann L, Boulot P, Déchaud H. Laparoscopic cervico-isthmic cerclage evaluation. *Gynecol Obstet Fertil* 2009 Apr;37(4):294-299.
14. Harger JH. Cerclage and cervical insufficiency: an evidence-based analysis. *Obstet Gynecol* 2002 Dec;100(6):1313-1327.
15. Liddell HS, Lo C. Laparoscopic cervical cerclage: a series in women with a history of second trimester miscarriage. *J Minim Invasive Gynecol* 2008;15:342-345.
16. Whittle WL, Singh SS, Allen L, Glaude L, Thomas J, Windrim R, Leyland N. Laparoscopic cervico-isthmic cerclage: surgical technique and obstetric outcomes. *Am J Obstet Gynecol* 2009;201:364.e361-364.e367.
17. Fechner AJ, Alvarez M, Smith DH, Al-Khan A. Robotic-assisted laparoscopic cerclage in a pregnant patient. *Am J Obstet Gynecol* 2009;200:e10-e11.
18. Carter JF, Soper DE, Goetzl LM, Van Dorsten JP. Abdominal cerclage for the treatment of recurrent cervical insufficiency: laparoscopy or laparotomy? *Am J Obstet Gynecol* 2009;201:111.e111-111.e114.
19. Pereira L, Cotter A, Gómez R, et al. Expectant management compared with physical examination indicated cerclage (EM-PEC) in selected women with a dilated cervix at 14(0/7)-25(6/7) weeks: results from the EM-PEC international cohort study. *Am J Obstet Gynecol* 2007;197:483.e1-483.e8.
20. Palacio M, Cobo T, Bosch J, et al. Cervical length and gestational age at admission as predictors of intra amniotic inflammation

- in preterm labor with intact Membranes. *Ultrasound Obstet Gynecol* 2009;34:441-447.
21. Murray A, Hutton J. Successful tubal blastocyst transfer after laparoscopic cervical cerclage: caesarean delivery of a live very low-birth-weight infant and later hysterectomy for uterine rupture. *Fertility and Sterility* 2011 October;96(4): 895-897.
 22. DaCosta V, Wynter S, Harriott J, Christie L, Frederick J, Frederick-Johnston S. Laparoscopic Cervicoisthmic Cerclage for the Treatment of Cervical Incompetence, Case Reports. *West Indian Med J* 2011;60(5):590-593.
 23. El-Nashar SA, Paraiso MF, Rodewald K, Muir T, Abdelhafez F, Lazebnik N, Bedaiwy MA. Laparoscopic cervicoisthmic cerclage: technique and systematic review of the literature. *Gynecol Obstet Invest* 2012;75:1-8.
 24. Salmeen KE, Parer JT. Preconceptional laparoscopic Abdominal cerclage: a multicental cohort study. *AMJ Obstet Gynecol* 2013 Apr;208(4):335-336.
 25. Ades A, May J, Cade TJ, Umstad MP. Laparoscopic trans-abdominal cervical cerclage: a 6-year experience. *Aust NZJ Obstet Gynaecol* 2014;54:117-120.