

Two-port Mini vs Conventional Four-port vs Single-incision Laparoscopic Cholecystectomy: An Update with Review of Literature

¹Mohammad O Tabrez, ²Rajneesh K Mishra, ³Jatinder S Chowhan

ABSTRACT

Introduction: Laparoscopic cholecystectomy (LC) is the gold standard for the removal of gallbladder stones. In an attempt to reduce the invasiveness of the procedure, surgeons have done various modifications like reduction of port size and/or number, which is used in conventional LC. The main objective of this review is to compare the two-port mini LC with other techniques of LC like conventional four-port laparoscopic surgery or single-incision laparoscopic cholecystectomy (SILC) in elective laparoscopic cholecystectomy and determine the outcome of two-port mini LC.

Material and methods: Literature review was performed on newly minimal invasive approach for LC, two-port cholecystectomy, variations in size and port of cholecystectomy and their advantages over one another, and SILC. The search was performed using the search engines like Google, PubMed.

Results: Postoperative pain was significantly low in the two-port group. The overall analgesia requirements and return to daily activity were significantly lower in two-port group. The cosmesis score of the two-port group was better than four-port group or SILC. However, the length of hospital stay and complications was similar between the two-port and four-port LC, but it differs in SILC.

Conclusion: Two-port mini LC resulted in reduced pain, need for analgesia, and improved cosmesis without increasing the operative time and complication rates compared with that in four-port LC or SILC. Hence, two-port mini LC can be tried firstly and can be converted to additional four-port LC when necessary.

Keywords: Cholecystectomy, Laparoscopic cholecystectomy, Lapchole, Mini-laparoscopy, Review, Single-incision laparoscopic cholecystectomy, Two-port laparoscopy.

How to cite this article: Tabrez MO, Mishra RK, Chowhan JS. Two-port Mini vs Conventional Four-port vs Single-incision Laparoscopic Cholecystectomy: An Update with Review of Literature. *World J Lap Surg* 2017;10(3):95-97.

¹Consultant, ^{2,3}Senior Consultant

¹Department of Laparoscopic and Robotic Surgery, Rahmania Medical Centre, Motihari, Bihar, India

^{2,3}Department of Laparoscopic and Robotic Surgery, World Laparoscopy Hospital, Gurugram, Haryana, India

Corresponding Author: Mohammad O Tabrez, Consultant Department of Laparoscopic and Robotic Surgery, Rahmania Medical Centre, Motihari, Bihar, India, Phone: +917070990616 e-mail: tabrezomar@gmail.com

Source of support: Nil

Conflict of interest: None

INTRODUCTION

Laparoscopic cholecystectomy is now the gold standard for the removal of gallbladder.¹ The main advantages of laparoscopic surgery include better cosmetic results, decreased postoperative pain, and faster functional recovery.¹ Various innovations in the techniques of LC like natural transluminal endoscopic surgery,² single-incision laparoscopic surgery (SILS),³⁻⁵ two-port,⁶ and three-port⁷ laparoscopic surgeries have been applied for removal of gallbladder as a step forward to even lesser invasive procedures than the conventional four-port surgery. These different newer techniques represent the advent of essentially scarless, more pain-free, better cosmesis, and early return of function for the patient with benefit to one another.

The evolution of surgery of gallbladder from Langenbuch's first cholecystectomy with a hospital stay of 6 weeks into a day-care specialty following the introduction of LC is indeed fascinating.⁸

In conventional four-port LC, one 10-mm optical port is placed in umbilical area and other 10-mm port is to be placed in the epigastrium to the left of the falciform ligament with two additional 5-mm ports in the right upper abdomen two finger breadths below the costal margin in midclavicular line and anterior/midaxillary line at the level or just below the umbilicus. Dissection of the gallbladder is performed by the standard technique by first grasping and lifting the fundus, followed by dissection of the cystic duct and artery. Once the "critical view" of these structures was obtained, these were clipped and divided. The gallbladder is then removed from its bed using electrocautery and retrieved through the epigastric port.

FOREWORD TO LITERATURE REVIEW

Four-port LC

Four-port laparoscopic surgery is also called as conventional laparoscopic surgery (CLC) for cholecystectomy performed with fourth port; 10-mm ports are placed at

umbilicus and epigastrium and 5-mm ports are placed at right midclavicular below subcostal margin and anterior/midaxillary line at level of umbilicus (Fig. 1). The main advantages of laparoscopic surgery include better cosmetic results, decreased postoperative pain, faster functional recovery, and less complications as compared with the open surgery.

Two-port Mini LC

In two-port laparoscopic surgery, one 10-mm port is placed at umbilical area and one 5-mm epigastric port is placed to the left of the falciform ligament. One special 2.3-mm alligator graspers (Stryker Corporation, USA) (Fig. 2) is used transabdominally for grasping the Hartmann pouch of the gallbladder for its retraction and manipulation respectively. Using the standard Maryland laparoscopic instrument, the cystic duct and artery are dissected as in the four-port technique. For clipping the cystic duct and artery, a 5-mm clip applicator was used with 200-mm clips. In case of wider cystic duct, single hand suturing of the duct was done with 2/0 silk. The structures are divided and dissection proceeded by reversing the laparoscope and dissecting instruments to their original sites. Gallbladder specimen is retrieved through the umbilical port by railroad technique or using 5-mm 30° scope through the epigastric port and 10-mm jaw forceps from the umbilical port.

In two-port mini LC when compared with SILC, surgery becomes much easier due to restoration of triangulation, and learning curve becomes shorter; however, it causes minimal violation of anterior abdomen due to less number of port and sizes leading to lesser postoperative pain and less cosmesis when compared with SILC or four-port LC.⁹ With the newer techniques, the need for more sophisticated instruments escalates the cost of

surgery and limits the use of these minimally invasive techniques to a few centers. Two-port mini LC scores over the conventional techniques as it requires minimal new instruments and can be performed at all laparoscopic centers without any new cost inputs and simultaneously to achieve the goal of minimal access surgery.

Operative time varies with different studies as few require less and few more than the conventional technique.¹⁰⁻¹⁴ The operative difficulty is based on the status of gallbladder, adhesions around the gallbladder fossa, Calot's triangle, and cystic duct anatomy. The conversion rates from two-port mini LC to four-port LC and open cholecystectomy in many studies are in the range of 23 to 38%.^{13,15,16} The main reasons for conversions are difficult anatomy due to dense inflammation from cholecystitis, common bile duct injury, and instrument failure. A planned two-port surgery must be given up in the event of such difficult anatomy on initial diagnostic exploration to proceed further with conversion.^{17,18}

Single-incision Laparoscopic Cholecystectomy or Single-port Access

It proposes a single site port placement, and it is in or around umbilicus using a special port devices. This usually requires a larger skin incision of 20 mm. However, the technique is more demanding as dissection becomes more difficult due to clashing of instruments, loss of normal triangulation, restricted vision, and depth of dissection. A special large port, angulated instruments, and scopes are needed for better dissection (Fig. 3). All these factors lead to a steeper learning curve and increase the risk of large scar due to 20-mm port than conventional port or two-port LC. It increases the postoperative pain as compared with SILC due to larger port size, and also there is increased wound-related complications including hernia formation.⁴

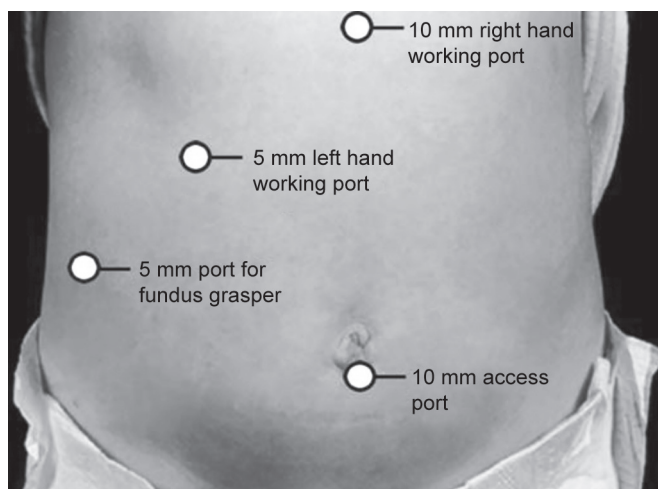


Fig. 1: Port placement in CLC



Fig. 2: Mini alligator for two-port LC




Fig. 3: SILS port and technique of insertion of SILS port

CONCLUSION

In our conclusion, LC can be performed with two-port technique in properly selected cases and optimize the benefits of minimal access surgeries. Two-port mini LC resulted in reduced pain, need for analgesia, and improved cosmesis without increasing the operative time and complication rates compared with that in four-port LC or SILC. Hence, two-port mini LC can be tried firstly and can be continued with addition of fourth port if necessary.

REFERENCES

1. Soper NJ, Barteau JA, Clayman RV. Comparison of early postoperative results for laparoscopic vs standard open cholecystectomy. *Surg Gynecol Obstet* 1992 Feb;174(2):114-118.
2. de la Fuente SG, Demaria EJ, Reynolds JD, Portenier DD, Pryor AD. New developments in surgery: Natural Transluminal Endoscopic Surgery (NOTES). *Arch Surg* 2007 Mar;142(3):295-297.
3. Curcillo PG 2nd, Wu AS, Podolsky ER, Graybeal C, Katkhouda N, Saenz A, Dunham R, Fendley S, Neff M, Copper C, et al. SPATM cholecystectomy: a multi-institutional report. *Surg Endosc* 2010 Aug;24(8):1854-1860.
4. Navarra G, Pozza E, Occhionorelli S, Carcoforo P, Donini I. One-wound laparoscopic cholecystectomy. *Br J Surg* 1997 May;84(5):695-697.
5. Kalloo A, Singh V, Jagannath S. Flexible transgastric peritoneoscopy a novel approach to diagnostic and therapeutic interventions in the peritoneal cavity. *Gastrointest Endosc* 2004 Jul;60(1):114-117.
6. Mori T, Ikeda Y, Okamoto K, Sakata K, Ideguchi K, Nakagawa K, Yasumitsu T. A new technique for two-trocar laparoscopic cholecystectomy. *Surg Endosc* 2002 Apr;16(4):589-591.
7. Slim K, Pezet D, Stencl J Jr, Lechner C, Le Roux S, Lointier P, Chipponi J. Laparoscopic cholecystectomy: an original three-trocar technique. *World J Surg* 1995 May-Jun;19(3):394-397.
8. NIH Consensus Conference: Gallstones and laparoscopic cholecystectomy. *JAMA* 1993 Feb;269(8):1018-1024.
9. Poon CM, Chan KW, Lee DW, Chan KC, Ko CW, Cheung HY, Lee KW. Two-port versus four-port laparoscopic cholecystectomy. *Surg Endosc* 2003 Oct;17(10):1624-1626.
10. Ramachandran CS, Arora V. Two-port laparoscopic cholecystectomy: an innovative new method for gallbladder removal. *J Laparoendosc Adv Surg Tech A* 1998 Oct;8(5):303-308.
11. Bisgaard T, Klarskov B, Trap R, Kehlet H, Rosenburg J. Micro-laparoscopic vs conventional laparoscopic cholecystectomy: a prospective randomized double-blind trial. *Surg Endosc* 2002 Mar;16(3):458-464.
12. Schwenk W, Neudecker J, Mall J, Bohm B, Muller JM. Prospective randomized blinded trial of pulmonary function, pain, and cosmetic results after laparoscopic vs. microlaparoscopic cholecystectomy. *Surg Endosc* 2000 Apr;14(4):345-348.
13. Look M, Chew SP, Tan YC, Liew SE, Cheong DM, Tan JC, Wee SB, Teh CH, Low CH. Post-operative pain in needle-scope versus conventional laparoscopic cholecystectomy: a prospective randomised trial. *J R Coll Surg Edinb* 2001 Jun;46(3):138-142.
14. Lomanto D, De Angelis L, Ceci V, Dalsasso G, So J, Frat-taroli FM, Muthiah R, Speranza V. Two-trocar laparoscopic cholecystectomy: A reproducible technique. *Surg Laparosc Endosc Percutan Tech* 2001 Aug;11(4):248-251.
15. Alponat A, Cubukcu A, Gonullu N, Canturk Z, Ozbay O. Is minisite cholecystectomy less traumatic? Prospective randomized study comparing minisite and conventional laparoscopic cholecystectomies. *World J Surg* 2002 Dec;26(12):1437-1440.
16. Sarli L, Iusco D, Gobbi S, Porrini C, Ferro C, Roncoroni L. Randomized clinical trial of laparoscopic cholecystectomy performed with mini-instruments. *Br J Surg* 2003;90:1345-1348.
17. Novitsky YW, Kercher KW, Czerniach DR, Kaban GK, Khera S, Gallagher-Dorval KA, Callery MP, Litwin DE, Kelly JJ. Advantages of mini-laparoscopic vs conventional laparoscopic cholecystectomy. *Arch Surg* 2005 Dec;140(12):1178-1183.
18. Lai EC, Fok M, Chan AS. Needloscopic cholecystectomy: prospective study of 150 patients. *Hong Kong Med J* 2003 Aug;9(4):238-242.