

Achalasia Cardia: Revisited

¹Balachandran Premkumar, ²Subhankar Paul

ABSTRACT

Introduction: Achalasia cardia is a very common esophageal motility disorder affecting a large population worldwide including the Indian subcontinent. The diagnosis of the condition is equally important as the treatment ranges from medicines to botulinum injection, to pneumatic dilatation and surgery. This study gives an overview of achalasia cardia and the modalities to diagnose and treat the condition.

Keywords: Achalasia cardia, Cardiospasm, Esophageal achalasia, Esophageal peristalsis.

How to cite this article: Premkumar B, Paul S. Achalasia Cardia: Revisited. World J Lap Surg 2017;10(3):112-116.

Source of support: Nil

Conflict of interest: None

INTRODUCTION

Achalasia cardia is an esophageal motility disorder in which the smooth muscle layer of the esophagus loses normal peristalsis and the lower esophageal sphincter (LES) fails to relax properly in response to swallowing (Fig. 1).¹⁻³

SYMPTOMS

The main symptoms of achalasia are dysphagia (difficulty in swallowing) and regurgitation of undigested food.⁴ Dysphagia tends to become progressively worse over time to involve both fluids and solids. Some achalasia patients also experience weight loss, coughing when lying in a horizontal position, and chest pain which may be perceived as heart burn. The chest pain experienced, also known as cardiospasm and noncardiac chest pain (NCCP), can often be mistaken for a heart attack.⁵ It can be very painful in some sufferers. The food and liquid, including saliva, are retained in the esophagus and may cause aspiration.⁶

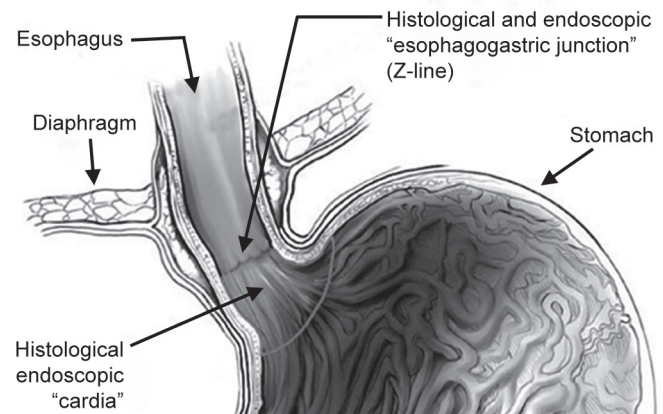


Fig. 1: Lower esophageal sphincter

DIFFERENTIAL DIAGNOSIS

A few other conditions may mimic the symptoms of achalasia cardia,⁷ such as

- Gastroesophageal reflux disease (GERD),
- Hiatus hernia, and
- Psychosomatic disorders.

INVESTIGATIONS

Specific tests for achalasia are barium swallow and esophageal manometry. In addition, endoscopy, with or without endoscopic ultrasound, may be done to rule out the possibility of cancer.⁴

Barium Swallow

The classical "Bird's beak" or "Rat's tail" appearance may be seen. An air-fluid margin is often seen over the barium column due to the lack of peristalsis.⁸

A 5-minute timed barium swallow can provide a useful benchmark to measure the effectiveness of treatment.⁹ It also shows aperistaltic contractions, increased intraesophageal pressure, and failure of relaxation of the LES (Fig. 2).¹⁰

Esophageal Manometry

Because of its sensitivity, manometry is considered the key test for establishing the diagnosis.¹¹ Manometry reveals failure of the LES to relax with swallowing and lack of functional peristalsis in the smooth muscle of esophagus (Graph 1).¹²

¹Consultant, ²Registrar

^{1,2}Department of General Surgery, Apollo Hospitals, Chennai Tamil Nadu, India

Corresponding Author: Balachandran Premkumar, Consultant Department of General Surgery, Apollo Hospitals, Chennai, Tamil Nadu, India, e-mail: drbpk@hotmail.com

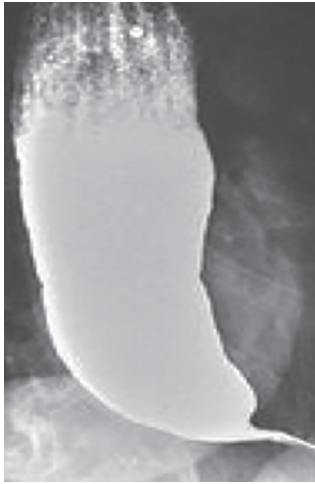

Fig. 2: Bird's beak appearance

Endoscopy

The internal tissue of the esophagus in achalasia cardia, generally, appears normal in endoscopy, although a “pop” may be observed as the scope is passed through the non-relaxing LES with some difficulty, and food debris may be found above the LES.

Biopsy

Biopsy from the esophagus shows hypertrophied musculature and absence of certain nerve cells of the myenteric plexus, a network of nerve fibers that controls esophageal peristalsis.

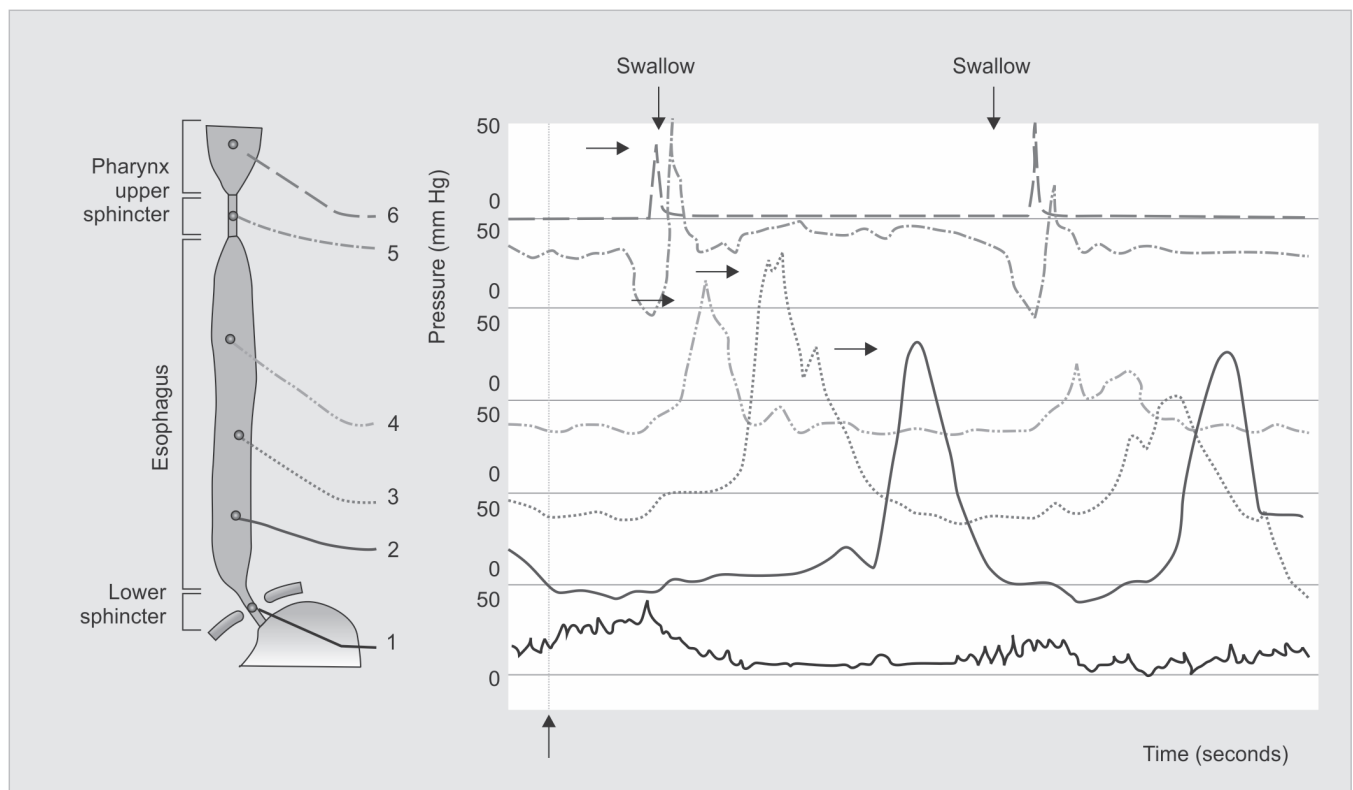
MANAGEMENT

Medications

- Drugs that reduce LES pressure are useful at early stages. These include calcium channel blockers, such as nifedipine and nitrates, such as isosorbide dinitrate and nitroglycerin.¹³ Sublingual nifedipine significantly improves outcomes in 75% of people with mild or moderate disease.¹⁴ However, many patients experience unpleasant side effects, such as headache and swollen feet, and these drugs often stop helping after several months.⁴
- Botulinum toxin (Botox) may be injected into the LES to paralyze the muscles holding it shut. The effect is only temporary and lasts about 6 months. Botox injections cause scarring in the sphincter which may increase the difficulty of later Heller myotomy.¹⁵ This therapy is only recommended for patients who cannot risk surgery, such as elderly persons in poor health.¹⁶

Pneumatic Dilatation

- Pneumatic dilatation is most effective in the long term, in patients over the age of 40; the benefits tend to be shorter lived in younger patients.¹⁷ It may need to be repeated with larger balloons for maximum effectiveness.¹⁸ Also in balloon pneumatic dilatation, a small risk of a perforation requires immediate surgical repair. Pneumatic dilatation causes some scarring



Graph 1: Manometry reading

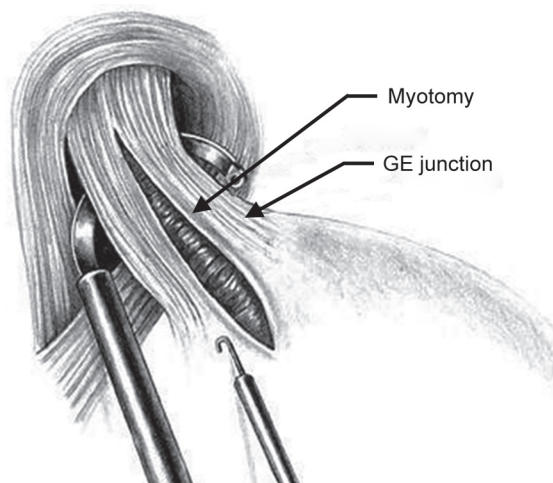


Fig. 3: Laparoscopic cardiomyotomy²⁵

which may increase the difficulty of Heller myotomy if the surgery is needed later.¹⁵ There have been reports of GERD after pneumatic dilatation in some patients.¹⁹

SURGERY

Surgical myotomy (Heller's myotomy) provides greater benefit than either botulinum toxin or dilatation in those who fail medical management.^{20,21} Heller's myotomy helps 90% of achalasia patients.²² The myotomy is a lengthwise cut along the esophagus, starting above the LES and extending down onto the stomach a little way leaving the inner mucosal layer intact. Laparoscopic management of achalasia leads to short-term results comparable to those of the well-established conventional open technique. Heller's myotomy for achalasia performed laparoscopically offers patients significant benefits compared with open surgery. In view of the less severe surgical trauma and lower hospital cost, the laparoscopic approach is preferable.²³ A partial fundoplication or "wrap" is generally added in order to prevent excessive reflux (Fig. 3).^{24,25}

LAPAROSCOPIC CARDIOMYOTOMY

Surgical Issues

In view of the concern of postoperative reflux as well as the relative ease of performing an antireflux procedure, a fundoplication procedure is added to most laparoscopic Heller's myotomies.²⁴ However, the issue of what type of fundoplication should be performed is controversial.²⁶ Anterior fundoplication and the Toupet posterior fundoplication are the two commonly employed antireflux procedures used in conjunction with a laparoscopic esophagomyotomy.

Proponents of the Toupet procedure argue that it prevents reapproximation of the myotomy and may be better than an anterior fundoplication in preventing postoperative GERD, whereas the advocates of the anterior fundoplication

procedure argue that it is easy to perform and can be used to protect the esophagus following myotomy.²⁷

Additionally, it has been suggested that the retro-esophageal dissection required for a Toupet procedure may increase the incidence of postoperative dysphagia. Despite the controversy, laparoscopic Heller's myotomy is most often accompanied by an anterior fundoplication.

Laparoscopic Heller's myotomy with anterior fundoplication significantly relieves the symptoms of achalasia without causing the symptoms of GERD and results in excellent overall patient satisfaction.^{28,29}

Laparoscopic Heller-Dor operation has the advantages of reduced compromise of the cardiopulmonary function, with less disruption of the supporting structures (phreno-esophageal membrane) of the antireflux mechanism, requiring simpler general anesthesia and providing excellent exposure permitting an easy fundoplication, less pain and reduced morbidity, shorter hospitalization, and faster convalescence.^{23,28}

Robotics in Achalasia

Robot-assisted laparoscopic Heller's myotomy was demonstrated to be safe and effective in reducing basal LES pressure and dysphagia. Several studies support the feasibility of the use of this system in performing a delicate laparoscopic surgical procedure. The use of a robotic system was experienced as being highly supportive in manipulation and visualization by the surgical team involved.³⁰

Per-oral Endoscopic Myotomy

Per-oral endoscopic myotomy is a new technique of performing esophageal myotomy at the LES.³¹ In this technique, an endoscope is passed into the esophagus and an opening is made in the esophageal mucosa a few centimeters above the LES to create a tunnel within the wall of the esophagus (between the inner lining of the esophagus and the outer muscle layer of the esophagus). The endoscope is then advanced into the tunnel, and the circular muscle of the esophagus is cut using an electrocautery device that is passed through the endoscope. Per-oral endoscopic myotomy is considered an effective approach for the treatment of achalasia, which improves esophageal emptying and lowers LES pressure, and thereby relieves the symptoms of achalasia. However, only limited centers and expert endoscopists are performing the procedure right now and further trials and long-term follow-up is required.

FOLLOW-UP

Even after successful treatment of achalasia, swallowing may still deteriorate over time.³² Therefore, the esophagus

should be checked every year or two with a timed barium swallow because some may need pneumatic dilatations, a repeat myotomy, or even esophagectomy after many years. In addition, some physicians recommend pH testing and endoscopy to check for reflux damage, which may lead to Barrett's esophagus or a stricture if untreated.¹

LIFESTYLE CHANGES

The treatment of achalasia cardia demands a host of lifestyle changes that improve the outcome as well as quality of life if followed as routine habit. Achalasia patients may require to eat meals slowly, chew the food very well, drink adequate water with meals, and avoid eating dinner immediately before going to bed. Emptying of the esophagus by gravity is promoted by raising the head end of the bed or sleeping with a wedge pillow. After surgery or pneumatic dilatation, proton pump inhibitors can help prevent reflux damage by inhibiting gastric acid secretion; and foods that can aggravate reflux, including ketchup, citrus, chocolate, mint, alcohol, and caffeine, are better avoided.³³

CONCLUSION

The understanding of the pathophysiology of achalasia cardia is important to initiate treatment, and the failure of the medical treatment calls for a definitive surgical treatment for the same. The success of the treatment also depends on patient compliance and lifestyle changes with appropriate follow-up.

REFERENCES

- Richter JE. Achalasia – an update. *J Neurogastroenterol Motil* 2010 Jul;16(3):232-242.
- Abdi S, Forotan M, Nikzamir A, Zomorody S, Jahani-Sherafat S. The early efficacy of Heller myotomy in the treatment of Iranian patients with achalasia. *Gastroenterol Hepatol Bed Bench* 2016 Winter;9(1):30-35.
- Fregnani JH, Macea JR, Barros MD, Liquidato BM, Macea MI, Alves AL, Pereira CS, Pinto AC, de Carvalho MF, Carillo J. Cardia: at the end of the day, what is it? *Int J Morphol* 2007 Jun;25(2):375-380.
- Pohl D, Tutuian R. Achalasia: an overview of diagnosis and treatment. *J Gastrointestinal Liver Dis* 2007 Sep;16(3):297-303.
- Dekel R, Martinez-Hawthorne SD, Guillen RJ, Fass R. Evaluation of symptom index in identifying gastroesophageal reflux disease-related noncardiac chest pain. *J Clin Gastroenterol* 2004 Jan;38(1):24-29.
- Palmer JB, Drennan JC, Baba M. Evaluation and treatment of swallowing impairments. *Am Fam Physician* 2000 Apr;61(8):2453-2462.
- Ates F, Vaezi MF. The pathogenesis and management of achalasia: current status and future directions. *Gut Liver* 2017 Jul;9(4):449-463.
- Spieß AE, Kahrilas PJ. Treating achalasia from whalebone to laparoscope. *JAMA* 1998 Aug;280(7):638-642.
- de Oliveira JM, Birgisson S, Doinoff C, Einstein D, Herts B, Davros W, Obuchowski N, Koehler RE, Richter J, Baker ME. Timed barium swallow: a simple technique for evaluating esophageal emptying in patients with achalasia. *AJR Am J Roentgenol* 1997 Aug;169(2):473-479.
- Farrokhi F, Vaezi MF. Idiopathic (primary) achalasia. *Orphanet J Rare Dis* 2007 Sep;2:38.
- Kessing BF, Smout AJ, Bredenoord AJ. Clinical applications of esophageal impedance monitoring and high-resolution manometry. *Curr Gastroenterol Rep* 2012 Jun;14(3):197-205.
- Gold, BD. Achalasia. *Clinical Advisor*. Available from: <http://www.clinicaladvisor.com/pediatrics/achalasia/article/624740/>.
- Gelfond M, Rozen P, Gilat T. Isosorbide dinitrate and nifedipine treatment of achalasia: a clinical, manometric and radionuclide evaluation. *Gastroenterology* 1982 Nov;83(5):963-969.
- Bortolotti M, Coccia G, Brunelli F, Sarti P, Mazza M, Bagnato F, Barbara L. Isosorbide dinitrate or nifedipine: which is preferable in the medical therapy of achalasia? *Ital J Gastroenterol* 1994 Oct-Nov;26(8):379-382.
- Smith CD, Stival A, Howell DL, Swafford V. Endoscopic therapy for achalasia before Heller myotomy results in worse outcomes than Heller myotomy alone. *Ann Surg* 2006 May;243(5):579-584, discussion 584-586.
- Dughera L, Battaglia E, Maggio D, Cassolino P, Mioli PR, Morelli A, Emanuelli G, Bassotti G. Botulinum toxin treatment of oesophageal achalasia in the old old and oldest old: a 1-year follow-up study. *Drugs Aging* 2005 Sep;22(9):779-783.
- Gideon RM, Castell DO, Yarze J. Prospective randomized comparison of pneumatic dilatation technique in patients with idiopathic achalasia. *Dig Dis Sci* 1999 Sep;44(9):1853-1857.
- Chuah S-K, Wu K-L, Hu T-H, Tai W-C, Changchien C-S. Endoscope-guided pneumatic dilation for treatment of esophageal achalasia. *World J Gastroenterol* 2010 Jan;16(4):411-417.
- Eckardt VF, Kanzler G, Westermeier T. Complications and their impact after pneumatic dilation for achalasia: prospective long-term follow-up study. *Gastrointest Endosc* 1997 May;45(5):349-353.
- Wang L, Li YM, Li L. Meta-analysis of randomized and controlled treatment trials for achalasia. *Dig Dis Sci* 2009 Nov;54(11):2303-2311.
- Campos GM, Vittinghoff E, Rabl C, Takata M, Gadenstätter M, Lin F, Ciovica R. Endoscopic and surgical treatments for achalasia: a systematic review and meta-analysis. *Ann Surg* 2009 Jan;249(1):45-57.
- Rosemurgy A, Villadolid D, Thometz D, Kalipersad C, Rakita S, Albrink M, Johnson M, Boyce W. Laparoscopic Heller myotomy provides durable relief from achalasia and salvages failures after botox or dilation. *Ann Surg* 2005 May;241(5):725-733, discussion 733-735.
- Ancona E, Anselmino M, Zaninotto G, Costantini M, Rossi M, Bonavina L, Boccu C, Buin F, Peracchia A. Esophageal achalasia: laparoscopic *versus* conventional open Heller-Dor operation. *Am J Surg* 1995 Sep;170(3):265-270.
- Yamamura MS, Gilster JC, Myers BS, Deveney CW, Sheppard BC. Laparoscopic Heller myotomy and anterior fundoplication for achalasia results in a high degree of patient satisfaction. *Arch Surg* 2000 Aug;135(8):902-906.
- Katada N, Sakuramoto S, Kobayashi N, Futawatari N, Kuroyama S, Kikuchi S, Watanabe M. Laparoscopic Heller myotomy with Toupet fundoplication for achalasia

- straightens the esophagus and relieves dysphagia. *Am J Surg* 2006 Jul;192(1):1-8.
26. Rossetti G, Bruscianno L, Amato G, Maffettone V, Napolitano V, Russo G, Izzo D, Russo F, Pizza F, Genio GD, et al. A total fundoplication is not an obstacle to esophageal emptying after Heller myotomy for achalasia: results of a long-term follow up. *Ann Surg* 2005 Apr;241(4):614-621.
 27. Roberts KE, Duffy AJ, Bell RL. Controversies in the treatment of gastroesophageal reflux and achalasia. *World J Gastroenterol* 2006 May;12(20):3155-3161.
 28. Khajanchee YS, Kanneganti S, Leatherwood AE, Hansen PD, Swanström LL. Laparoscopic Heller myotomy with Toupet fundoplication. *Arch Surg* 2005 Sep;140(9):827-834.
 29. Richards WO, Torquati A, Holzman MD, Khaitan L, Byrne D, Lutfi R, Sharp KW. Heller myotomy versus Heller myotomy with Dor fundoplication for achalasia. *Ann Surg* 2004 Sep;240(3):405-415.
 30. Horgan S, Galvani C, Gorodner MV, Omelanczuck P, Elli F, Moser F, Durand L, Caracoche M, Nefa J, Bustos S, et al. Robotic-assisted Heller myotomy *versus* laparoscopic Heller myotomy for the treatment of esophageal. *J Gastrointest Surg* 2005 Nov;9(8):1020-1030.
 31. Ling TS, Guo HM, Yang T, Peng CY, Zou XP, Shi RH. Effectiveness of peroral endoscopic myotomy in the treatment of achalasia: a pilot trial in Chinese Han population with a minimum of one-year follow-up. *J Dig Dis* 2014 Jul;15(7):352-358.
 32. Dughera L, Chiaverina M, Cacciotella L, Cisarò F. Management of achalasia. *Clin Exp Gastroenterol* 2011 Feb;4:33-41.
 33. Leeuwenburgh I, Scholten P, Caljé TJ, Vaessen RJ, Tilanus HW, Hansen BE, Kuipers EJ. Barrett's esophagus and esophageal adenocarcinoma are common after treatment for achalasia. *Dig Dis Sci* 2013 Jan;58(1):244-252.