

# Laparoscopy in Cesarean Scar Pregnancy

R Meenakshi Menon

## ABSTRACT

**Introduction:** With the increase in rates of cesarean deliveries, complications in subsequent pregnancies like placenta accreta/percreta, uterine rupture, and cesarean scar ectopic pregnancy are on the rise. Cesarean scar pregnancy (CSP) accounts for about 2 to 4% of all ectopic pregnancies. Improvement in diagnostic techniques and advancement in transvaginal ultrasound and advent of minimal access surgery has contributed to early detection and timely management of CSP.

**Objective:** This article aims to review different treatment modalities of CSP and hence to compare efficacy of laparoscopy with other management techniques.

**Materials and methods:** Case series, retrospective cohort studies, and articles were reviewed which included studies from PubMed, MEDLINE, Cochrane library, and EMBASE. The main outcome was successful first-line treatment. Complications during treatment were listed as bleeding more than 1 L, blood transfusion, hysterectomy, and laparotomy.

**Results:** Successful treatment and reduced complications were noted with laparoscopy as compared with medical management.

**Conclusion:** Interventional than medical approach is preferred in management of CSP. Laparoscopic surgery helps in removal of ectopic tissue in cesarean scar with simultaneous repair of the defect under adequate visualization.

**Keywords:** Cesarean scar pregnancy, Ectopic pregnancy, Laparoscopy.

**How to cite this article:** Menon RM. Laparoscopy in Cesarean Scar Pregnancy. *World J Lap Surg* 2017;10(3):135-138.

**Source of support:** Nil

**Conflict of interest:** None

## INTRODUCTION

National Family Health Survey 2014 to 2015 reveals that rate of cesarean surgery has doubled over the last decade from 8.5% in 2005 to 17.2% in 2015. Thus, complications like CSP have also been on the rise. Incidence of CSP has been reported to be 1 in 1,800 to 1 in 2,200 pregnancies. With the advent of transvaginal ultrasonography, early

detection is possible, mean gestational age at diagnosis being  $7.5 \pm 2.5$  weeks with interval between last cesarean section and CSP being 6 months to 12 years.<sup>1</sup>

Cesarean scar pregnancy has been hypothesized to occur from an early invasion of myometrium which occurs through a microscopic tract in the cesarean scar tissue.<sup>2</sup>

Two types of CSP have been explained: Endogenic or type I and exogenic or type II. Endogenic CSP progresses toward cervicoisthmic space, or uterine cavity could progress to viability but with high risk of bleeding from placental site.

Type II progresses toward bladder or abdominal cavity with deep invasion of scar defect. Type II usually complicates with uterine rupture or bleeding early in pregnancy.<sup>3</sup>

Ultrasound plays a pivotal role in diagnosis. Cesarean scar pregnancy (Fig. 1) is characterized by certain ultrasound findings<sup>4</sup>:

- Empty uterus and cervical canal
- Gestational Sac located in anterior uterine wall (part of isthmus) with diminished or absent myometrium between gestational sac and bladder and discontinuity in anterior wall of uterus adjacent to gestational sac
- Circular blood flow surrounding the sac on Doppler.

Aborting gestation and cervical pregnancy are easily mistaken for a CSP.

Early diagnosis with high index of suspicion and timely management depending on the availability, skill of surgeon, and severity of symptoms are of prime importance.

The treatment options available and reviewed are

- Dilation and curettage (D&C) and excision of trophoblastic tissue using laparoscopy or laparotomy
- Local or systemic methotrexate (MTX)

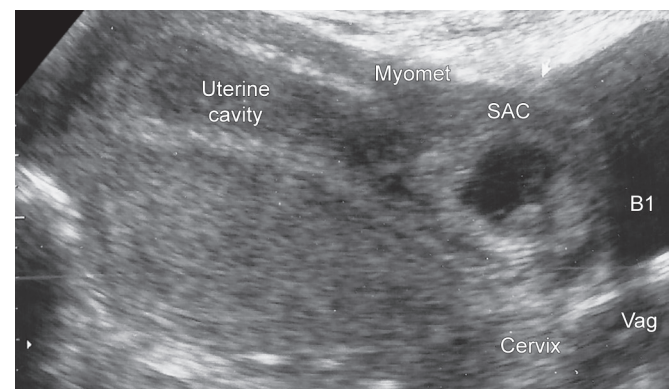


Fig. 1: Ultrasonographic view of a scar ectopic

Senior Resident

Department of Obstetrics and Gynecology, St. John's Medical College Hospital, Bengaluru, Karnataka, India

**Corresponding Author:** R Meenakshi Menon, 1069, Poorna Shree, Sector 7, HSR Layout, Bengaluru 560102, Karnataka India, Phone: +919746758373, e-mail: rmeenamenon@gmail.com

- Bilateral internal iliac artery ligation and dilation and extraction under laparoscopic guidance
- Selective uterine artery embolization (UAE) + D&C and MTX
- Transvaginal resection
- Hysteroscopy

A systematic review of the above management options was done by Petersen et al<sup>5</sup> focusing on efficacy and complications related with each method in 2,037 cases, where it was found that laparoscopy had 97.1% success rate with no severe complications. Rest of the management options had a variable success rate. Least success was seen with expectant management of 41.5% with a complication of 53.7%. Maximum success was noted with high-intensity focused ultrasound (HIFU) ablation of 100% with no complications, but only 16 cases were studied as compared with 69 cases who underwent laparoscopy.

Majority of the reviewed articles in this study were case reports, which was a major limitation in providing conclusions. Also, there was no consensus on individualizing treatment strategy based on type of CSP or thickness of intervening myometrium.<sup>5</sup>

Successful laparoscopic resection of CSP was first reported by Lee et al.<sup>6</sup>

### OPERATIVE PROCEDURE

In the review done by Birch Petersen et al,<sup>5</sup> laparoscopy was done under general anesthesia where CSP with

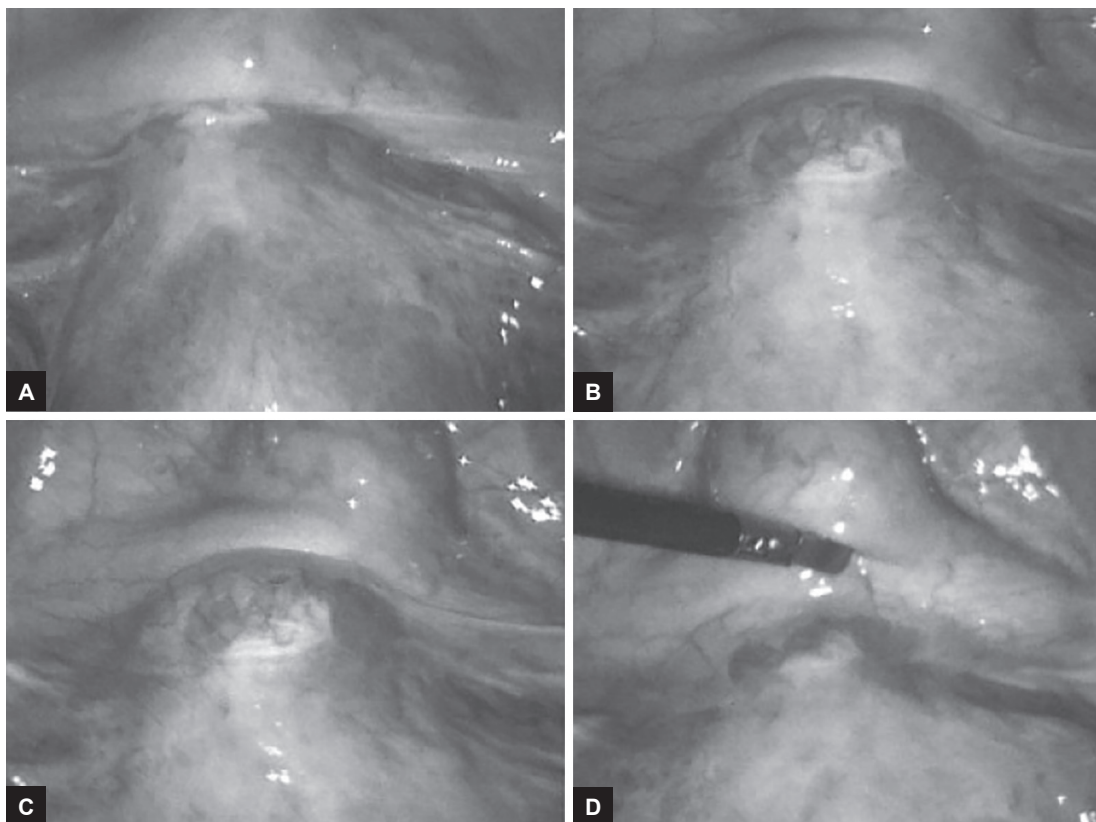
progression toward the bladder is seen. Bladder is dissected down, and excision of uterine scar is done with repair of defect in uterus.

Laparoscopic management is done by local injection of vasopressin followed by an incision over the bulge after reflecting the bladder, thereafter enucleating the sac and retrieval in an endobag. The uterine incision is sutured. Bipolar is used for hemostasis. Some surgeons also make a bilateral uterine artery ligation at the start of surgery to minimize blood loss (Fig. 2).<sup>7</sup>

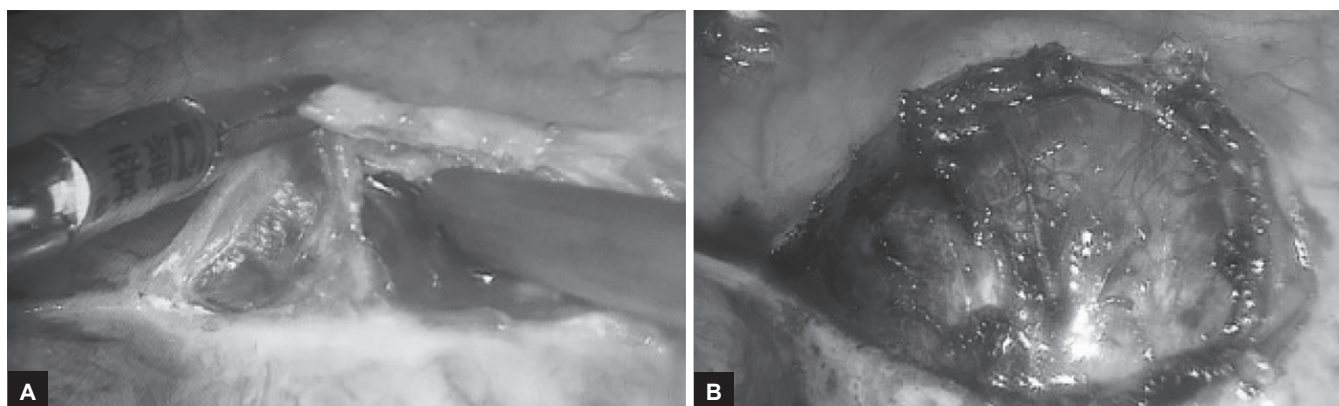
### ALTERNATIVES

Hysteroscopy was also considered an option, but additional treatment was required in 17% of cases. Hysteroscopic management of CSP has benefits over local and systemic MTX with normalization of  $\beta$ -human chorionic gonadotropin level more rapidly and decrease in follow-up time according to a retrospective cohort study conducted by Deans and Abott<sup>8</sup> in Sydney (Fig. 3).

In a study done by Pan and Liu,<sup>9</sup> hysteroscopy under laparoscopic guidance was preferred in cases with myometrial thickness less than 3 mm to avoid the risk of uterine perforation and bladder injury. Also, additional advantage of performing a laparoscopy concomitantly helps in resection and repair in case of perforation of scar site (Table 1 and Fig. 4).<sup>10</sup>



Figs 2A to D: Laparoscopic view of cesarean scar pregnancy



Figs 3A and B: Incision on the bulge

Table 1: Treatment modalities in Cesarean scar pregnancy

Method of treatment	Cases (n)	Success rate (%)	Severe complication rate (%)
Expectant management	41	41.5	53.7
Systemic MTX	339	75.2	13
Needle aspiration + MTX/KCl	148	84.5	13.5
Hysteroscopy	95	83.2	3.2
Selective UAE without MTX	295	93.6	3.4
UAE + D&C + hysteroscopy	85	95.4	1.2
UAE + MTX	427	68.6	2.8
Local + systemic MTX	34	76.5	2.3
Local MTX	74	64.9	4.1
Transvaginal resection	118	99.2	0.9
D&C	243	48.1	21
Laparoscopy	69	97.1	0
Repeated HIFU ablation	16	100	0
HIFU + hysteroscopic suction curettage	53	100	0




Fig. 4: Uterine scar repair by endo-suturing after enucleation of sac

According to a literature review by Fuchs et al,<sup>11</sup> the laparoscopic approach in management of CSP is safe and effective with minimal blood loss. It also gives an excellent visualization of the pathology at hand and permits a good reconstruction of the lower uterine

segment, which is very important for future pregnancy outcomes.

Medical management leaves the scar behind which can predispose to recurrence and also requires strict adherence to monitoring by ultrasound and hormone profile.<sup>12</sup>

Laparoscopy helps to confirm the diagnosis, removal of scar ectopic under better visualization, repair of defect, as well as preservation of reproductive capacity.<sup>13</sup> Use of vasopressin intraoperatively and suturing can minimize chances of hemorrhage and allow safe removal of ectopic with multilayer closure of uterine defect.<sup>14</sup>

Based on a review of literature by Api et al,<sup>15</sup> they concluded that laparoscopy has an edge over hysteroscopy with respect to repair of cesarean scar defect as it increases uterine wall thickness when compared with repair by hysteroscopic approach which does not help in reducing the potential risk of scar dehiscence or rupture in subsequent pregnancies.

In a case report published by Mahgoub et al<sup>16</sup> from a study conducted in Starsbourg, France, enucleation of ectopic mass was done with isthmocoele treatment with no complications, intraoperative blood loss of less than 100 mL, and discharge of patient on day 3.

## DISCUSSION

From the studies reviewed, treatment of CSP should be individualized with choice of management based on preventing severe complications and conservation of fertility. With facilities for laparoscopy readily available, it should be considered as a good option for management of CSP. In centers where facilities and skills are there, HIFU is also an effective alternative but limited by availability.

Limitation in this area is that many of the reviewed articles are case reports. Well-designed multicentric randomized controlled trials are required before any conclusion is made regarding best method of management. Until then, evidence-based treatment is followed with individualization of cases also taking into account surgeon's skills

and severity of patient symptoms. From the literature reviewed, laparoscopy is indeed an effective modality of treatment of CSP as it allows removal of ectopic mass *in toto* under visualization along with adequate repair of the defect which is particularly of importance in preserving subsequent reproductive capacity.

## CONCLUSION

Interventional approach is preferred in the management of CSP. Laparoscopy offers benefits of removal of ectopic tissue with repair of defect as well as need for a shorter hospital stay and follow-up while preserving fertility. However, case selection and surgical skills have an important role in management.

## ACKNOWLEDGMENT

The Authors would like to thank Prof Dr RK Mishra and Dr JS Chowhan, World Laparoscopy Hospital, Gurgaon, for their guidance in preparing this review article.

## REFERENCES

1. Ash A, Smith A, Maxwell D. Cesarean scar pregnancy. *BJOG* 2007 Mar;114(3):253-263.
2. Godin PA, Bassil S, Donnez J. An ectopic pregnancy developing in a previous caesarian section scar. *Fertil Steril* 1997 Feb;67(2):398-400.
3. Maheux-Lacroix S, Li F, Bujold E, Nesbitt-Hawes E, Deans R, Abbott J. Cesarean scar pregnancies: a systematic review of treatment options. *J Minim Invasive Gynecol* 2017 Sep-Oct;24(6):915-925.
4. Jurkovic D, Hillaby K, Woelfer B, Lawrence A, Salim R, Elson CJ. First-trimester diagnosis and management of pregnancies implanted into the lower uterine segment Cesarean section scar. *Ultrasound Obstet Gynecol* 2003 Mar;21(3):220-227.
5. Birch Petersen K, Hoffmann E, Rifbjerg Larsen C, Svarre Nielsen H. Cesarean scar pregnancy: a systematic review of treatment studies. *Fertil Steril* 2016 Apr;105(4):958-967.
6. Lee CL, Wang CJ, Chao A, Yen CF, Soong YK. Laparoscopic management of an ectopic pregnancy in a previous Cesarean section scar. *Hum Reprod* 1999 May;14(5):1234-1236.
7. Shah NH, Paranjpe S, Shah VN. Scar ectopic pregnancy managed laparoscopically. *JPGO* 2017 Jul;4(7).
8. Deans R, Abbott J. Hysteroscopic management of cesarean scar ectopic pregnancy. *Fertil Steril* 2010 Apr;93(6):1735-1740.
9. Pan Y, Liu MB. The value of hysteroscopic management of cesarean scar pregnancy: a report of 44 cases. *Taiwan J Obstet Gynecol* 2017 Apr;56(2):139-142.
10. Shu X, Lou S, Wang Z, Yao Y. Cesarean scar pregnancy treated by curettage and aspiration guided by laparoscopy. *Ther Clin Risk Manag* 2015 Aug;2015(11):1139-1141.
11. Fuchs N, Manoucheri E, Verbaan M, Einarsson JI. Laparoscopic management of extrauterine pregnancy in caesarean section scar: description of a surgical technique and review of the literature. *BJOG* 2015 Jan;122(1):137-142.
12. Hasegawa J, Ichizuka K, Matsuoka R, Otsuki K, Sekizawa A, Okai T. Limitations of conservative treatment for repeat cesarean scar pregnancy. *Ultrasound Obstet Gynecol* 2005 Mar;25(3):310-311.
13. Ribeiro DM, Ribeiro GM, Cossi P, Santos TP, Freire M. Laparoscopy surgical treatment of caesarean scar ectopic pregnancy (CSEP): case report. *Braz J Video-Sur* 2013 Jul-Sep;6(3):124-129.
14. Ades A, Parghi S. Laparoscopic resection of caesarean scar ectopic pregnancy. *J Minim Invasive Gynecol* 2017 May-Jun;24(4):533-535.
15. Api M, Boza A, Gorgen H, Api O. Should cesarean scar defect be treated laparoscopically? A case report and review of the literature. *J Minim Invasive Gynecol* 2015 Nov-Dec;22(7):1145-1152.
16. Mahgoub S, Gabriele V, Faller E, Langer B, Wattiez A, Lecointre L, Akladios C. Cesarean scar ectopic pregnancy. Laparoscopic resection and total scar dehiscence repair. A case report. *J Minim Invasive Gynecol* 2017;2017:S1553-4650(17)30098-30105.