

# Rouviere's Sulcus and Critical View of Safety: A Guide to prevent Bile Duct Injury during Laparoscopic Cholecystectomy

<sup>1</sup>Malwinder Singh, <sup>2</sup>Atul Jain, <sup>3</sup>Subhajeet Dey, <sup>4</sup>Tanweer Karim, <sup>5</sup>Nabal Mishra, <sup>6</sup>Mansoor Bandey

## ABSTRACT

**Context:** Laparoscopic cholecystectomy is a commonly performed minimal invasive surgery. However, its advantages are somewhat tempered due to risk of injury to bile duct.

**Aims:** The objective of the study is to identify Rouviere's sulcus (RS) and critical view of safety (CVS) before commencement of dissection of Calot's triangle to prevent injury to bile duct.

**Materials and methods:** A series of consecutive 100 patients admitted in the Department of Surgery in our hospital with uncomplicated symptomatic cholelithiasis underwent laparoscopic cholecystectomy identifying RS and CVS and complications (if any) emphasizing bile duct injury.

**Results:** The average duration of surgery after identifying RS and achievement of CVS was 65.30 minutes. There was no incidence of bile duct injury after identification of RS and achievement of CVS.

**Conclusion:** Rouviere's sulcus is an important anatomical landmark for the safe laparoscopic cholecystectomy. Achievement of CVS should be tried in all laparoscopic cholecystectomy.

**Keywords:** Bile duct injury, Critical view of safety, Laparoscopic cholecystectomy, Rouviere's sulcus.

**How to cite this article:** Singh M, Jain A, Dey S, Karim T, Mishra N, Bandey M. Rouviere's Sulcus and Critical View of Safety: A Guide to prevent Bile Duct Injury during Laparoscopic Cholecystectomy. *World J Lap Surg* 2018;11(1):25-28.

**Source of support:** Nil

**Conflict of interest:** None

## INTRODUCTION

Cholelithiasis was first described in 1420 by a Florentine pathologist Antonio Benivenius.<sup>1,2</sup> The first open cholecystectomy was performed by Carl Johann August Langenbuch, a German surgeon, at the Lazarus Krankenhaus on July 15, 1882,<sup>3,4</sup> whereas laparoscopic cholecystectomy was first performed in 1987 by Phillip Mouret.<sup>5,6</sup> His

work led to the respectability of laparoscopic surgery in medical field.

Laparoscopic cholecystectomy is the "gold standard" for surgical treatment of symptomatic gallstones.<sup>3</sup> Minimal invasive surgery holds an important position in today's practice. A large number of surgical procedures are performed laparoscopically worldwide with laparoscopic cholecystectomy being one of the most commonly practiced.

The advantages of laparoscopic cholecystectomy over open surgery are well known.<sup>7</sup> However, along with all the benefits of minimal invasive procedure came the inherent drawbacks of performing surgeries in new and unfamiliar way. The incidence of biliary tract injuries was definitely more as compared with open cholecystectomy.<sup>8</sup> Despite the advancement of laparoscopic cholecystectomy techniques, biliary tract injury still continues to be an important complication today, although the true incidence is unknown. The most common cause of injury to biliary tract is misidentification. The misidentifications are of two main types.

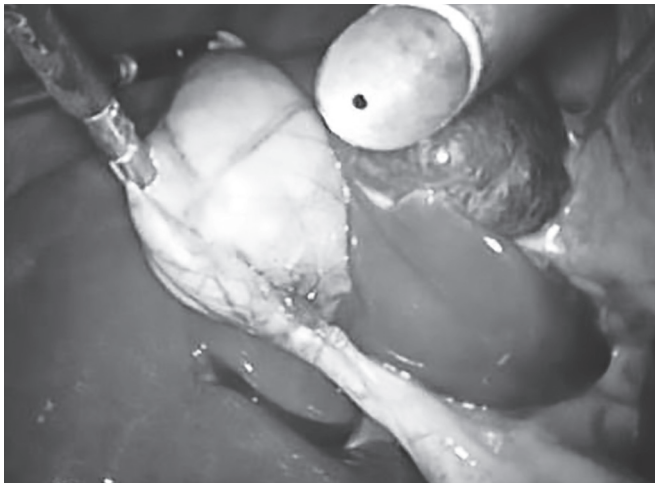
In the first scenario, the common bile duct (CBD) is mistaken to be the cystic duct and secondly, but less commonly, the identification of an aberrant right hepatic duct as the cystic duct.<sup>8</sup> The direction of traction of gallbladder has been known to contribute the appearance of CBD as cystic duct which can lead to misidentification injury.

When Hartmann's pouch is pulled superiorly and not laterally, the cystic duct and CBD get aligned and appear as single structure.<sup>9</sup> The Rouviere's sulcus (RS) described by Henri Rouviere in 1924 is now marked as a reference point to guide the commencement of safe dissection.<sup>10,11</sup> It is a cleft in liver (Fig. 1) recognizable in >90% of patients, shown by retracting the gallbladder infundibulum medially.<sup>11</sup> Similarly, a well-delineated junction of cystic duct with the gallbladder and demonstration of space between gallbladder and liver clear of any structure other than cystic artery (safety window or critical view) (Fig. 2) is also recommended as an essential step to prevent biliary tract injury.<sup>8</sup> For the last 15 years, achievement of CVS has been adopted by surgeons throughout the world for performance of laparoscopic cholecystectomy.<sup>12</sup> When it was initially described, it was done so

<sup>1,2,5,6</sup>Senior Resident, <sup>3,4</sup>Professor

<sup>1-6</sup>Department of Surgery, ESI-PGIMSR, ESI Hospital Basaidarapur, New Delhi, India

**Corresponding Author:** Atul Jain, Senior Resident, Department of Surgery, ESI-PGIMSR, ESI Hospital, Basaidarapur, New Delhi, India, e-mail: docatuljain@gmail.com



**Fig. 1:** Rouviere's sulcus



**Fig. 2:** Critical view of safety

with a brief description and picture without a thorough explanation of the rationale for this approach.

The primary purpose of study was to combine both RS and CVS and to understand why this method is protective in reducing the incidence of biliary tract injury through its use.

## MATERIALS AND METHODS

The study was done with 100 patients undergoing laparoscopic cholecystectomy in a tertiary care hospital in northern India.

The patients presented to the surgical outpatient department with diagnosis of gallbladder stones. Patients who gave informed consent after full explanation were electively admitted for an ambulatory laparoscopic cholecystectomy after preanesthetic check-up and routine investigations. Close monitoring was done in terms of vitals, postoperative complications, and morbidity.

### Inclusion Criteria

- Uncomplicated symptomatic cholelithiasis
- Medically fit and stable patients

### Exclusion Criteria

- Multiple comorbid diseases, coagulation disorders
- Suspected/proven malignancy
- Absence of RS
- Conversion to open cholecystectomy

Operative technique: Four-port technique for laparoscopic cholecystectomy was used. Two 10-mm ports and two 5-mm ports were used, 10-mm ports in the umbilical and epigastric region and 5-mm ports in the right hypochondrium and anterior axillary line (subcostal).

Pneumoperitoneum was created by inserting Veress needle in the infraumbilical region. After creating pneumoperitoneum, a 10-mm port was introduced and

a telescope was put in. After the abdominal survey, rest of the ports were put under direct vision, i.e., the 10-mm port in the epigastric region, 5-mm port in the right hypochondrium, and another 5-mm port in the anterior axillary line (subcostal). The patient was placed in reverse Trendelenburg's (Fowler's) position with the patient's head up and tilted to the left and the surgeon standing on left side of the patient. Gallbladder was grasped from the fundus through a 5-mm port and retracted.

Rouviere's sulcus was identified and dissection of triangle of Calot's was done above the level of this sulcus and CVS was created. Cystic artery and duct were defined. Cystic duct and cystic artery were clipped separately using Liga clips. Gallbladder removal was done from a 10-mm port (epigastric). Abdominal cavity was washed with normal saline to remove all the clots and spilled biliary content, if any.

Complete hemostasis was achieved. All port sites were closed with non-absorbable suture. All patients were followed up after 1 week with history and clinical examination for any postoperative complications.

## RESULTS

A total of hundred (n = 100) patients were taken up for laparoscopic cholecystectomy according to the preset selection criteria:

- Uncomplicated symptomatic cholelithiasis
- Medically fit and stable patients

The patients presented to the outpatient department with symptomatic cholelithiasis. All the patients had routine investigations and a preanesthetic check-up for fitness for surgery. The average duration of surgery after identifying RS and achievement of CVS was 65.30 minutes (20–120 min) (Table 1).

The average hospital stay was 1.33 days (1–5 days) (Table 2). There was no bile duct injury after identification

**Table 1:** Duration of surgery after identifying RS and achievement of CVS

Duration (in min)	Percentage of patients
20–40	16
41–60	40
61–80	23
81–100	16
101–120	5

**Table 2:** Length of hospital stay

Hospital stay (days)	Percentage of cases
1	80
2	12
3	4
4 or more	4

**Table 3:** Incidence of bile duct injury

Bile duct injury	Percentage of cases
Intraoperative	0
Postoperative (leak)	0

of RS and achievement of CVS. Patients were followed up after 1 week and thorough history of any complaint was taken, and clinical examination was done (Table 3).

## DISCUSSION

No other surgery has been so profoundly affected by the advent of laparoscopy as gallbladder surgery, i.e., cholecystectomy.

In fact, the converse may be more accurate; laparoscopic cholecystectomy has been instrumental in ushering in the laparoscopic era. Laparoscopic cholecystectomy has become the procedure of choice for routine gallbladder removal very rapidly.<sup>13</sup> With increasing frequency of laparoscopic cholecystectomy, the incidence of biliary tract injury has also increased simultaneously.

According to the need, many suggestions and modifications have been proposed to prevent biliary tract injury, and one of these is extrabiliary landmarks. Anatomical landmarks are the descriptions of neighboring structures crucial for identifying proper target tissue for dissection and resection. Although individual patients

may vary, their anatomical structure and certain commonalities exist.

These commonalities become obvious through the numerous cases and procedures reported. Laparoscopic surgeons must rely on these landmarks and it is crucial in laparoscopy that detour must be minimized; otherwise, an unexpected injury is likely to occur. The RS and CVS are the two landmarks mentioned in preventing bile duct injury.

Identification of RS and keeping the dissection ventral to it is one of the successful methods to prevent the bile duct injury.<sup>10</sup> Although recently its significance in laparoscopic cholecystectomy has been appreciated, there are nearly no clinical trials specifying the outcome of surgery in terms of bile duct injury. As compared with RS, the role of CVS in preventing bile duct injury has been largely appreciated and studied in preventing bile duct injury.

In our study, we have combined the above-mentioned landmarks to study their importance in safe execution of laparoscopic cholecystectomy. The importance of this combination has not been studied before according to the best of our knowledge. Heistermann et al<sup>14</sup> achieved CVS in 97 out of 100 patients and cholecystectomies were successfully completed with a minor incidence of cystic stump leak.

Incidence of bile duct injury was 1%, while the conversion rate was 3%.<sup>14</sup> Yegiyants and Collins<sup>15</sup> also achieved CVS in 3,000 patients and reported only one bile duct injury (0.033%) which occurred during the dissection of Calot's triangle prior to achieving the critical view. Similarly, Avgerinos et al<sup>16</sup> attained CVS in 998 out of 1,046 patients. Five minor bile duct leaks (0.47%) were reported which resolved spontaneously.

Their conversion rate was 2.7%.<sup>16</sup> Likewise, Sanjay et al<sup>17</sup> got success in achieving CVS in 388 out of 447 patients, all of them completed successfully without any incidence of bile duct injury. In cases where CVS was not achieved, they were converted. Rawlings et al<sup>18</sup> studied the importance of CVS in 54 patients who underwent single-incision laparoscopic cholecystectomy and reported no incidence of bile duct injury and came to a conclusion that dissection to obtain the CVS should be the goal in every patient (Table 4). In our present study, we laid emphasis

**Table 4:** Studies showing impact of CVS creation with/without identification of RS

Series	Type of study	RS identified	CVS created	Bile duct injury	Conversion to open cholecystectomy
Heistermann et al <sup>14</sup>	Case series (n = 100)	No	Yes (97 cases)	1 minor leak	3%
Yegiyants and Collins <sup>15</sup>	Case series (n = 300)	No	Yes	1	
Avgerinos et al <sup>16</sup>	Case series (n = 104)	No	Yes (998 cases)	5 minor leaks	2.7%
Sanjay et al <sup>17</sup>	Case series (n = 447)	No	Yes (388 cases)	Nil	13%
Rawlings et al <sup>18</sup>	Case series (n = 54)	No	Yes	Nil	–
Present study	Case series (n = 100)	Yes	Yes	Nil	–

on identification of RS before commencement of dissection of Calot's triangle and keeping the dissection above the level of sulcus to establish CVS before clipping and transection of cystic duct.

Although achievement of CVS is widely accepted, there are little data about the significance of RS. We created CVS in 100 patients after identifying RS. The incidence of bile duct injury among these patients was zero, based on clinical features. Our study has shown that the dreadful complications of biliary tract injuries can be avoided which greatly reduces the morbidity and mortality associated with it.

Our results should encourage additional studies to reduce the complications of laparoscopic cholecystectomies keeping in mind the significance of RS and CVS. The results obtained in our study demonstrate that laparoscopic cholecystectomy has lesser incidence of biliary tract injury according to the technique mentioned in this study.

## CONCLUSION

Rouviere's sulcus is an important anatomical landmark to increase the safety of laparoscopic cholecystectomy.

Achievement of CVS should be tried in all laparoscopic cholecystectomy. The result obtained by our study demonstrates that laparoscopic cholecystectomy is even safer in terms of biliary tract injuries after identification of RS and achievement of CVS.

## REFERENCES

1. Portincasa P, Moschetta A, Palasciano G. Cholesterol gallstone disease. *Lancet* 2006 Jul;368(9531):230-239.
2. Shehadi WH. The biliary system through the ages. *Int Surg* 1979 Nov-Dec;64(6):63-78.
3. Polychronidis A, Laftsidis P, Bounovas A, Simopoulos C. Twenty years of laparoscopic cholecystectomy: Philippe Mouret, March 17, 1987. *JLS* 2008 Jan-Mar;12(1):109-111.
4. Morgenstern L, Lagenbuch C. The first cholecystectomy. *Surg Endosc* 1992;6:113-114.
5. Reynolds W Jr. The first laparoscopic cholecystectomy. *JLS* 2001 Jan-Mar;5(1):89-94.
6. Meyer G, Hutti TP. Laparoscopic surgery in Europe: development and education. *Surg Endosc* 2001 May;15(3):229-231.
7. Maestroni U, Sortini D, Devito C, Pour Morad Kohan Brunaldi F, Anania G, Pavanelli L, Pasqualucci A, Donini A. A new method of preemptive analgesia in laparoscopic cholecystectomy. *Surg Endosc* 2002 Sep;16(9):1336-1340.
8. Strasberg SM, Hertl M, Soper NJ. An analysis of the problem of biliary injury during laparoscopic cholecystectomy. *J Am Coll Surg* 1995 Jan;180(1):101-125.
9. Strasberg SM, Eagon CJ, Drebin JA. The "hidden cystic duct" syndrome and the infundibular technique of laparoscopic cholecystectomy—the danger of the false infundibulum. *J Am Coll Surg* 2000 Dec;191(6):661-667.
10. Hugh TB, Kelly MD, Mekisic A. Rouviere's sulcus: a useful landmark in laparoscopic cholecystectomy. *Br J Surg* 1997 Sep;84(9):1253-1254.
11. Hugh TB. New strategies to prevent laparoscopic bile duct injury—surgeons can learn from pilots. *Surgery* 2002 Nov;132(5):826-835.
12. Auyang ED, Hungness ES, Vaziri K, Martin JA, Soper NJ. Natural orifice transluminal endoscopic surgery (NOTES): dissection for the critical view of safety during transcolonic cholecystectomy. *Surg Endosc* 2009 May;23(5):1117-1118.
13. Litwin DE, Cahan MA. Laparoscopic cholecystectomy. *Surg Clin North Am* 2008 Dec;88(6):1295-1313.
14. Heistermann HP, Tobusch A, Palmes D. Prevention of bile duct injuries after laparoscopic cholecystectomy. "The critical view of safety". *Zentralbl Chir* 2006 Dec;131(6):460-465.
15. Yegiyants S, Collins JC. Operative strategy can reduce the incidence of major bile duct injury in laparoscopic cholecystectomy. *Am Surg* 2008 Oct;74(10):985-987.
16. Avgerinos C, Kelgiorgi D, Touloumis Z, Baltatzi L, Dervenis C. One thousand laparoscopic cholecystectomies in a single surgical unit using the "critical view of safety" technique. *J Gastrointest Surg* 2009 Mar;13(3):498-503.
17. Sanjay P, Fulke JL, Exon DJ. Critical view of safety as an alternative to routine intraoperative cholangiography during laparoscopic cholecystectomy for acute biliary pathology. *J Gastrointest Surg* 2010 Aug;14(8):1280-1284.
18. Rawlings A, Hodgett SE, Matthews BD, Strasberg SM, Quasebarth M, Brunt LM. Single-incision laparoscopic cholecystectomy: initial experience with critical view of safety dissection and routine intraoperative cholangiography. *J Am Coll Surg* 2010 Jul;211(1):1-7.