

# Percutaneous Closure of Internal Ring: A Leap Ahead

<sup>1</sup>Ankit Shukla, <sup>2</sup>Varun Verma, <sup>3</sup>Bhanu Gupta, <sup>4</sup>Rajesh Chaudhary, <sup>5</sup>Nishant Nayar

## ABSTRACT

Surgery for inguinal hernia is commonly performed in children. Traditional approach is open herniotomy. However, numerous minimal invasive methods are evolving with the same or low complication and recurrence rates. Percutaneous internal ring suturing (PIRS) under vision is a minimal invasive technique which is simple, effective, remarkably cosmetic, economical, easy to learn and reproduce with short operative time, and helpful in identifying occult contralateral hernia. This procedure was performed first time in our secondary care set-up with gratifying results for the patient, parents, and the operating team.

**Keywords:** Inguinal hernia, Laparoscopic, Laparoscopically assisted simple suture obliteration, Percutaneous internal ring suturing.

**How to cite this article:** Shukla A, Verma V, Gupta B, Chaudhary R, Nayar N. Percutaneous Closure of Internal Ring: A Leap Ahead. *World J Lap Surg* 2018;11(1):51-53.

**Source of support:** Nil

**Conflict of interest:** None

## INTRODUCTION

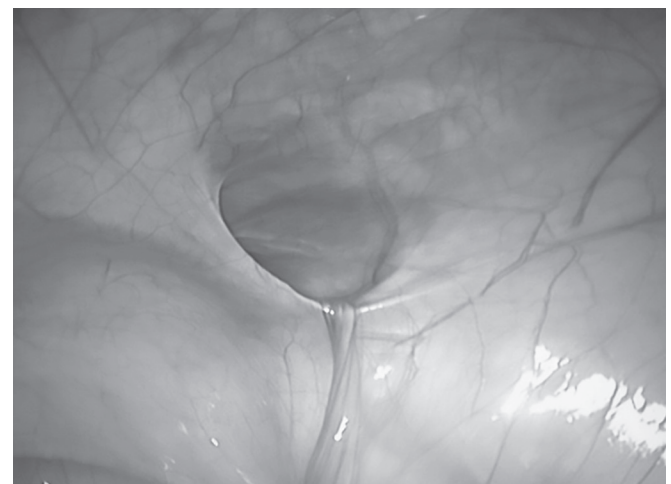Inguinal hernia surgery is performed in children quite frequently. The classical and well-established approach is open herniotomy, necessitating a groin incision and separating the sac from cord structures and ligating it at the internal ring. However, newer minimal invasive techniques have evolved with time. Laparoscopic repair of inguinal hernia in children was reported by El-Gohary.<sup>1</sup> Laparoscopic approach uses three ports usually, but some experienced surgeons prefer two-port approach, which requires intracorporeal ligation of the internal ring.

Patkowski et al<sup>2</sup> from Poland introduced a simple and easy method of suturing the internal ring percutaneously with a needle under vision with a single umbilical port, naming it PIRS. Various techniques with an aim of obliterating the internal ring in a minimal invasive way have been introduced from time to time like subcutaneous endoscopically assisted ligation (SEAL), modified SEAL, laparoscopically assisted simple suture obliteration (LASSO), laparoscopic percutaneous extraperitoneal closure (LPEC), and transumbilical endoscopic surgery.

## CASE REPORT

A 9-year-old female child presented to our surgery outpatient department with complaints of painless swelling in the right lower abdomen which appeared on coughing or while playing. On examination, a small reducible swelling was noticed in the right groin. She was diagnosed with right-sided uncomplicated inguinal hernia and planned for single-port laparoscopic surgery and PIRS under vision.

Patient was given general anesthesia with endotracheal tube intubation and pneumoperitoneum was created with the help of Veress needle maintaining a pressure of 8 to 10 mm Hg. Trocar was introduced through lower aspect of the umbilicus for camera and abdomen inspected from inside. A defect of approximately 2 cm was found on the right side lateral to the inferior epigastric artery and left internal ring was obliterated. Percutaneous purse string suturing of the right internal ring was done under vision extraperitoneally with the help of needle and a nonabsorbable 2/0 suture (Figs 1 to 3).



**Fig. 1:** Right inguinal hernia defect

<sup>1,2</sup>Surgeon, <sup>3</sup>Anesthesiologist, <sup>4</sup>Senior Resident, <sup>5</sup>Radiologist

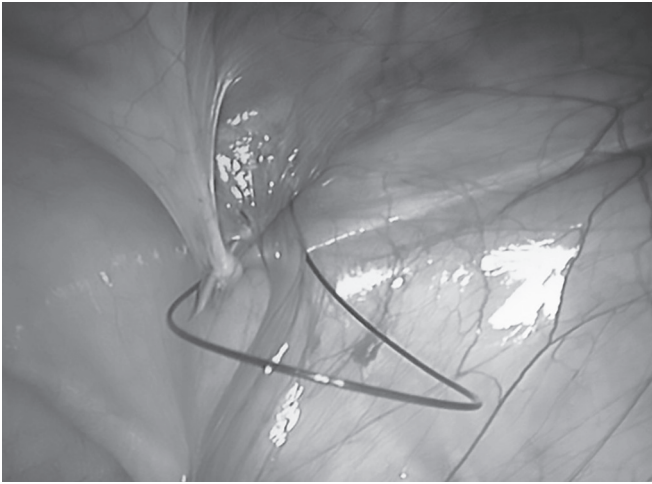
<sup>1,2</sup>Department of Surgery, Civil Hospital, Palampur, Himachal Pradesh, India

<sup>3</sup>Department of Anesthesiology, Civil Hospital, Palampur Himachal Pradesh, India

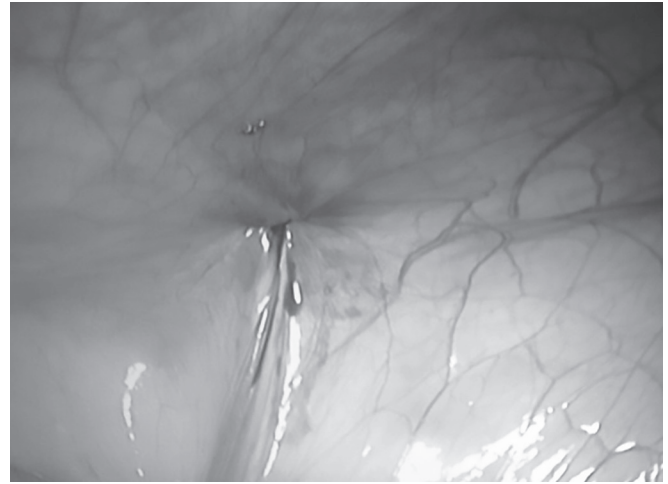
<sup>4</sup>Department of Surgery, Dr. Rajendra Prasad Government Medical College, Kangra, Himachal Pradesh, India

<sup>5</sup>Department of Radiology, Civil Hospital, Palampur, Himachal Pradesh, India

**Corresponding Author:** Ankit Shukla, Surgeon, Department of Surgery, Civil Hospital, Palampur, Himachal Pradesh, India e-mail: nkitshukla@hotmail.com



**Fig. 2:** Suturing internal ring



**Fig. 3:** Final closure of defect

The pneumoperitoneum was reduced and the umbilical incision closed and patient was extubated.

The patient recovered well, oral intake was started the same day, and she was discharged next day after uneventful postoperative stay.

## DISCUSSION

Open herniotomy is the gold standard and the most commonly performed surgery for hernia in children, and minimal invasive procedures are gaining interest.<sup>3</sup> The inception of the idea of closure of internal ring for inguinal hernia started way back in 1982, when Ger<sup>4</sup> closed the internal ring with Michel clip for hernia in an adult patient. Holcomb<sup>5</sup> introduced the concept of diagnostic laparoscopy for the evaluation of contralateral inguinal region. Laparoscopic surgery for pediatric inguinal hernia commenced in late 1990s, which included three ports for intracorporeal ligation of the internal ring, but some surgeons refined this and preferred the two-port approach.<sup>1,2</sup>

Further advancement in minimal invasive surgery shifted the focus from intracorporeal suturing, which was considered to be a difficult task, to extraperitoneal suturing of the indirect ring,<sup>1</sup> leading to development of various techniques with an identical goal of obliterating the internal ring in a minimal invasive way, namely PIRS, SEAL, modified SEAL, LASSO, single-incision pediatric endosurgery, extracorporeal with Reverdin needle, and LPEC.<sup>1-3,6</sup> All these techniques use a single umbilical port for camera and different methods of percutaneous closure of internal ring under vision. The PIRS, the most popular among these, uses an 18G needle, LASSO uses epidural needle, and SEAL is accomplished with a curved needle and a needle holder, whereas modified SEAL includes hydrodissection.<sup>1,6,7</sup>

Laparoscopic surgery for hernia when compared with the traditional open herniotomy has an equal recurrence rate of less than 4% with an edge over herniotomy by

having less chance of injury to cord structures, early recovery, assessment of contralateral hernia and its repair, and less postoperative pain.<sup>8</sup> The advantage of percutaneous repair for inguinal hernia when compared with laparoscopic repair seems to be simple, quicker to perform, economical, easy to learn, and cosmetically better with equal postoperative time and complication rates.<sup>9</sup> The recurrence rate in extraperitoneal repair is also less with some studies quoting it to be less than 1%.<sup>10</sup>

Looking at the various complications reported with the procedure was injury to iliac vessels which was controlled with pressure after deflating the abdomen. Hydrocele was seen in few patients, but resolved and did not require surgical management.<sup>7</sup> The results of electromyography for the assessment of ilioinguinal nerve entrapment were taken in 35 patients preoperatively and postoperatively which were found to be normal.<sup>10</sup>

## CONCLUSION

This procedure was performed for the first time in our secondary care set-up with gratifying results for the patient, parents, and the operating team. Percutaneous internal ring suturing under vision is a minimal invasive technique which is simple, effective, remarkably cosmetic, economical, easy to learn and reproduce with short operative time, and helpful in identifying occult contralateral hernia. The complication and recurrence rates are quite low, making it a promising procedure of choice for congenital hernia and communicating hydrocele in the near future.

## REFERENCES

1. El-Gohary MA. Laparoscopic ligation of inguinal hernia in girls. *Pediatr Endosurg Innov Techn* 1997 Jan;1(3):185-187.
2. Patkowski D, Czernik J, Chrzan R, Jaworski W, Apoznański W. Percutaneous internal ring suturing: a simple minimally invasive technique for inguinal hernia repair in children. *J Laparoendosc Adv Surg Tech A* 2006 Oct;16(5):513-517.

3. Saranga BR, Arora M, Baskaran V. Minimal access surgery of pediatric inguinal hernias: a review. *Surg Endosc* 2008 Aug;22(8):1751-1762.
4. Ger R. The management of abdominal hernia by intra abdominal closure of sac. *Ann R Coll Surg Engl* 1982 Sep;64(5):342-344.
5. Holcomb GW. Diagnostic laparoscopy for congenital inguinal hernia. *SAGE J* 1998 Mar;5(1):55-59.
6. Thomas DT, Göcmen KB, Tulgar S, Boga I. Percutaneous internal ring suturing is a safe and effective method for the minimal invasive treatment of pediatric inguinal hernia: experience with 250 cases. *J Pediatr Surg* 2016 Aug;51(8):1330-1335.
7. Wolak PK, Patkowski D. Laparoscopic inguinal hernia repair in children using the percutaneous internal ring suturing technique—own experience. *Wideochir Inne Tech Maloinwazyjne* 2014 Mar;9(1):53-58.
8. Alzahem A. Laparoscopic versus open inguinal herniotomy in infants and children: a meta-analysis. *Pediatr Surg Int* 2011 Jun;27(6):605-612.
9. Bharathi RS, Dabas AK, Arora M, Baskaran V. Laparoscopic ligation of internal ring—three ports versus single-port technique: are working ports necessary? *J Laparoendosc Adv Surg Tech A* 2008 Dec;18(6):891-894.
10. Kara O, Yildiz A, Toydemir HE, Gökyiğit FM, Akın M, Karadağ ÇA, Sever N, Dokucu AI. Does percutaneous internal ring suturing contain risk of ilioinguinal nerve entrapment? *Pediatr Surg Int* 2015 May;31(5):485-491.