

Laparoscopic Port Closure Techniques and Incidence of Port-site Hernias: A Review and Recommendations

¹Mohammed Arifuzaman, ²Asna Samreen

ABSTRACT

Minimally invasive surgeries have dawned a new era in surgical practice, cosmesis and safety. These have been heralded as one of the best surgical methods to treat a multitude of surgical disorders. Though the term minimally invasive seems attractive, in the real sense of the word, these surgeries are minimal access surgeries and do require incisions for trocars. The wounds must be closed appropriately to prevent the incidence of port-site hernia. Though rare, port-site hernias can cause considerable morbidity. Most of these are seen in the midline, particularly around the umbilicus, but there are reports of herniation at laterally placed ports. The accepted surgical practice is to close the fascial layers at all midline laparoscopic ports. There is a multitude of ways in which the ports can be closed. This article aims to review the various port closure techniques practiced by different surgeons and institutions to and reflect upon the pathophysiology of port-site hernia and recommendations to minimize them. Systematic research of the literature was performed using PubMed, Cochrane database, Google scholar and ClinicalKey. Different port-site closure techniques are described and analyzed. Though not one technique has been found to be superior to the other, all of them have their pros and cons. All of them produce similar results, and it is upon the discretion of the surgeon to accept any one of these methods. The authors have also tried to provide recommendations to minimize the incidence of port-site hernias.

Keywords: Laparoscopic hernia and port-site closure techniques, Port-site closure, Trocar site hernia.

How to cite this article: Arifuzaman M, Samreen A. Laparoscopic Port Closure Techniques and Incidence of Port-site Hernias: A Review and Recommendations. *World J Lap Surg* 2018;11(2):90-102.

Source of support: Nil

Conflict of interest: None

¹Junior Consultant, ²Registrar

¹Department of General and Laparoscopic Surgery, Princess Durru Shehvar Children's and General Hospital, Hyderabad, Telangana, India

²Department of Obstetrics and Gynecology, Princess Durru Shehvar Children's and General Hospital, Hyderabad, Telangana, India

Corresponding Author: Mohammed Arifuzaman, Junior Consultant, Department of General and Laparoscopic Surgery, Princess Durru Shehvar Children's and General Hospital, Hyderabad, Telangana, India, e-mail: mohammedarifuzaman@yahoo.com

INTRODUCTION

Throughout our history, the abdominal surgical procedures have been performed through large incisions. Most of which were concurrently associated with multiple morbidities which include postoperative pain, wound infections, wound dehiscence, longer hospital stay and a higher incidence of incisional hernias.¹ With the advances in surgery, incisions started to get smaller, and it was not very late until laparoscopic procedures were introduced in the early 1930s, when Ruddock, an American surgeon described laparoscopy as diagnostic procedure superior to Laparotomy.² The modern era of laparoscopic surgery is widely accepted to have commenced from September 12, 1985, when Professor Mühe of Böblingen³ performed the first laparoscopic cholecystectomy (LC) in Germany. The procedure has been widely accepted and has become a gold standard for surgical management of cholelithiasis.⁴

There are various access techniques used for the creation of a pneumoperitoneum in laparoscopic surgery. They can be widely classified into open access, closed access, and advanced techniques.

Open Access

This is a direct entry into the abdomen under vision without the creation of a pneumoperitoneum, and the insufflator is connected once the blunt trocar is inside the abdominal cavity. Various techniques include Hasson's technique, Scandinavian technique and Fielding technique.⁵⁻⁷

Closed Technique

Veress needle, named after Janos Veress, is used in this technique to create a pneumoperitoneum first. This is a blind technique and is widely practiced.

Advanced Techniques

These include single incision laparoscopic surgery (SILS) and natural orifice transluminal endoscopic surgery (NOTES).

Peritoneal Healing and Adhesions

All the above techniques require an opening of the parietal layer of the peritoneum to access the intraperitoneal

structures. Parietal defects are covered by mesothelial stem cells within 5–6 days in case of parietal peritoneum.⁸ The total time for repair may take from 8 days–2 weeks. At sites of peritoneal cautery and suture repair, deep submesothelial hemorrhage and necrosis prolong the duration of inflammation, and hence the collagen deposition is delayed, and healing is not seen even after 3 weeks.^{8,9} This delay in healing can be attributed to the development of adhesions and port-site hernias. Adhesions form when two injured peritoneal surfaces are opposed Lamont et al. Surgical insult to tissues results in relative or absolute ischemia which leads to local persistence of the fibrin matrix. This is replaced by vascular granulation tissue which consists of macrophages, fibroblasts, and giant cells. Eventually, the adhesions mature into fibrous bands often containing small nodules of calcification. Hence the development of intraperitoneal adhesions is a dynamic process where the surgically traumatized tissues which are in apposition bind through fibrin bridges which become organized by wound repair process often supporting a rich vascular supply as well as neuronal elements.⁸ The fibroblasts contribute collagen which stabilizes the adhesions and promotes vascular in growth.

Pathogenesis of Hernia Development After Peritoneal Injury

Fear¹⁰ first reported a trocar site hernia in his large series on laparoscopic gynecological diagnosis. While this complication has been recognized for a long time, its significance is becoming more important as more and more patients are being treated for this. The term trocar site hernia was defined by Crist and Gadacz¹¹ as a hernia developing at a cannula insertion site. A port-site hernia following laparoscopic surgery is less common compared with an incisional hernia occurring after open surgery.^{12,13} One study evaluating the risk for a late-onset hernia following a variety of open and laparoscopic surgeries reported incidences of an incisional hernia at 1.9 and 3.2 percent at two and five years after laparoscopic surgery, respectively.¹⁴ By comparison, the incidence of an incisional hernia for open surgery was 8 and 12%, respectively.

Port Closure Techniques

It is recommended that all 10–2 mm trocar sites in adults and all 5-mm port-sites in children be closed, incorporating the peritoneum into the fascial closure.¹⁵ Shaher¹⁶ classified the different port-closure techniques into three categories:

- Techniques that use assistance from inside the abdomen (requiring two additional ports);
- Techniques that use extracorporeal assistance (requiring one additional port); and

- Closure techniques that can be performed with or without visualization (no additional ports)

MATERIALS AND METHODS

A literature search was performed for the articles related to port closure techniques in laparoscopic and robotic surgeries on Pub Med, Cochrane database, Google Scholar and Clinical key. The keywords used were port-site closure, trocar site hernia, laparoscopic hernia and port-site closure techniques. Prospective and retrospective case series, randomized trials, literature reviews, and randomized animal studies of trocar hernias on abdominal wall defects from gynecologic, urologic, and general surgery literature were reviewed.

RESULTS

Various techniques and associated hernia rates:

Standard Closure Through Skin Wound^{17,18}

- This method incorporates direct visualization of the defect through the skin wound After the pneumoperitoneum has been released and the port removed.
- The fascial edges are grasped with a Kocher or Allis clamp, and the various layers are sutured together with a simple or figure-of-eight suture (Fig. 1). This tends to be difficult in obese patients with a large breadth of subcutaneous fat. Every attempt should be made to include all fascial layers and the peritoneum in the closure. It can be difficult to include the peritoneum when dealing with patients of moderate to high body mass index (BMI). In some cases, the skin incision may have to be enlarged to permit adequate closure.

Port-site Closure using Modified Aptos Needle

Ahmed et al.¹⁹ used the Lasheen needle, which is a curved needle with a length which varies from 10 to 15 cm (Fig. 2). It has two sharp pointed ends and a hole at the middle of its length, through which the thread (No. 0 Vicryl) is passed. The loaded needle was passed in one edge of the port wound at the subcutaneous pre-fascial plane to come out of the skin about 2 cms from the wound edge. At this point, the edge of the externalized thread within the wound edge was held, and the direction of the needle reversed to come out through the other wound edge about 2 cm lateral. Now the needle direction was reversed, and the needle came out through the wound itself with the other end of the thread externalized through the trocar wound. In the end, both the ends of the thread were inside the wound edge. The strands were tied, and the knot lay directly on the anterior abdominal sheath (Fig. 3). This study was

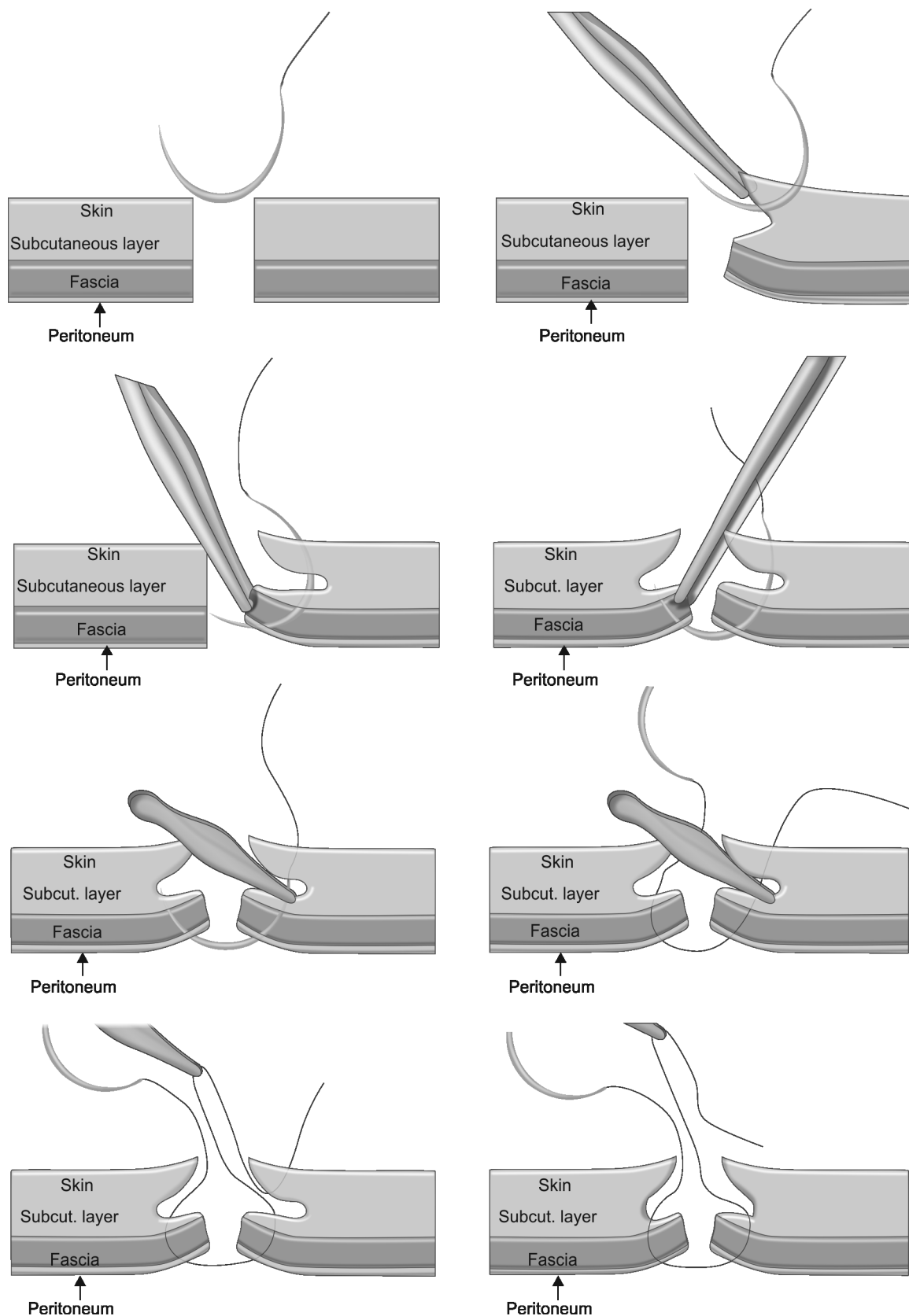


Fig. 1: Standard closure through skin wound

performed on 100 patients, and all were subjected to laparoscopic cholecystectomy. The follow-up period was from 4–32 months (mean 2 years). No port-site hernias were reported during the follow-up period. Surgical wound infection was reported in 3 patients (3%).

Skin Hooks

Shah²⁰ reported the use of skin hooks at the edges of 10 mm and 12 mm ports in laparoscopic upper and lower gastrointestinal surgeries. The skin hooks taut the edges of the skin wound, giving better visualization for suturing

the defect under vision (Fig. 4). They report the use of this technique in over 12 laparoscopic procedures over 7 years without a single port-site hernia.



Fig. 2: Lasheen needle. It is a curved needle; its length ranges from 10 to 15 cm. It has two sharp pointed ends and a hole at the middle of its length, through which the thread (No. 0 Vicryl) is passed.

Carter–Thomason Needle-point Suture Passer²¹

The Carter–Thomason needle-point suture passer functions as both a needle and a grasper, which allows for performing laparoscopic directed fascial and peritoneal closure. It uses a 2.7 mm diameter grasping tool with a single-action jaw. The device introduces the suture through the muscle, fascia, and peritoneal layers under direct laparoscopic vision drop the suture pick it up at the opposite side of the opening and are withdrawn grasping the suture (Fig. 5). The surgeon completes the mass closure of the layers by tying the suture below the skin.

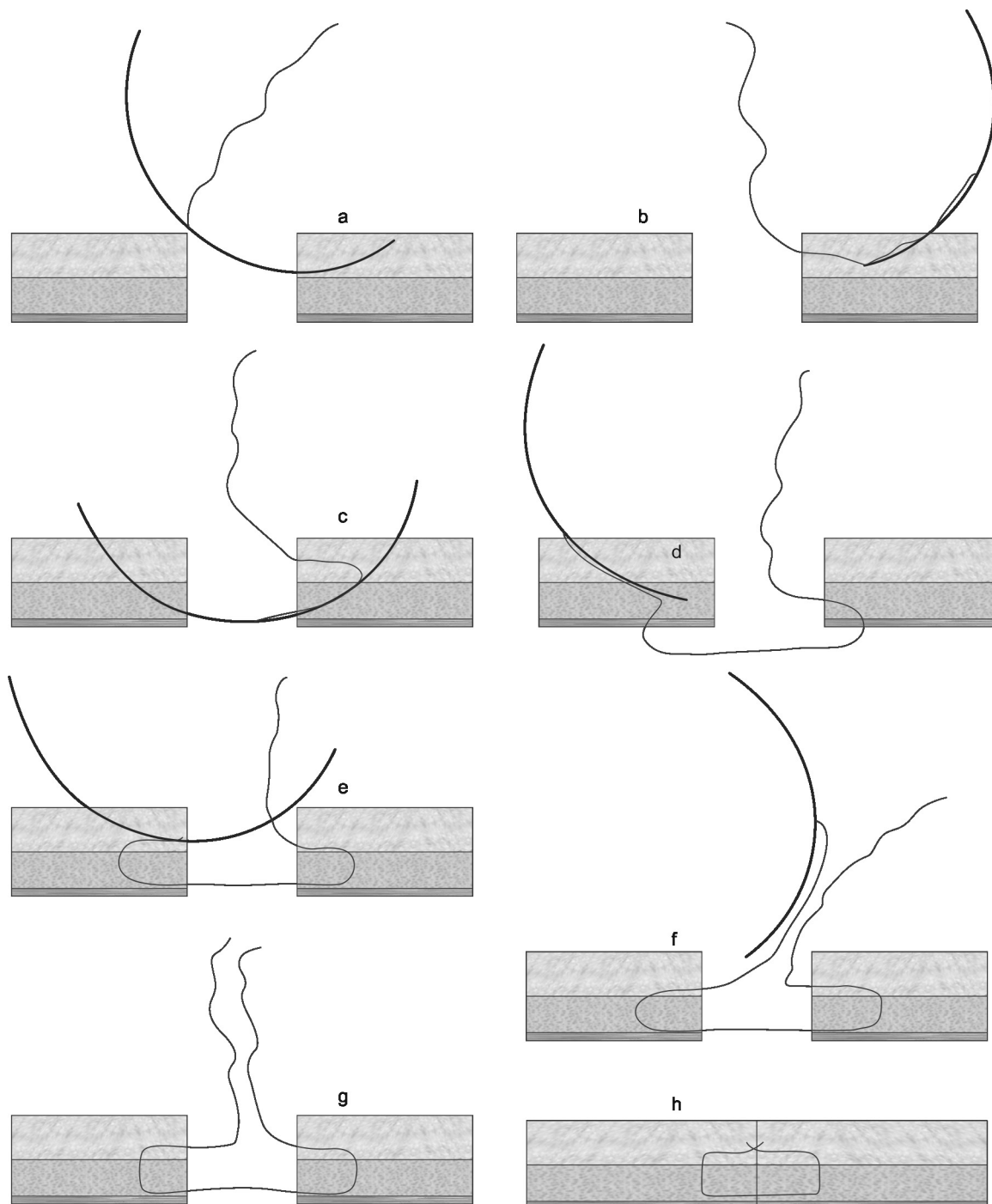


Fig. 3: Steps of lasheen needle closure technique.

Pneumoperitoneum is maintained. The closed peritoneal layer is viewed through the laparoscope, and palpation of the closure ensures that the fascial layer is completely occluded. The author reports the use of this technique in more than 200 advanced laparoscopic techniques without a single case of port-site hernia. And also been introduced, that is Carter–Thomason II, which offers better and faster closure (Fig. 6). It has a 15 mm and 10 mm suture guides and a suture passer. The suture passer useful in obese patients.

Endo Close Instrument²²

Del Junco M published a study, where the efficacy of WECK EFX™ Endo Fascial Closure System (EFx) (Fig. 7) was compared with the Carter–Thomason CloseSure System® (CT) for the closure of laparoscopic trocar site defects created by a 12 mm dilating trocar. Weck EFX is a fascial closure system where an absorbable suture is passed in the suture retrieval system once it is introduced

in the port-site and deployed with the wings which lock in the abdominal wall. The sutures are fully inserted into the guide channels and locked. The retriever is then removed and the same process continued on the other side. The wing shield is the collapsed once the slide lock is repositioned and the device removed from the defect. Both the ends of the suture are then tied, and the knot buries deep in the fascial layer. This study was performed in cadavers and reportedly better results were obtained with EFX than CT in terms of time needed for closure, safety, and facility.

Veress Needle for Port-site Closure²³

Kotakala and Mishra conducted a retrospective study of 500 patients who underwent various Laparoscopic procedures from 2006–2015 in which the port-sites of 10 mm or greater were closed with a novel technique using only the veress needle. A loop is created with a suture thread in the cannula of veress needle through and through the whole length of the cannula. Another suture, which will be used to close the port-site, is introduced in the tip of the cannula for about 2 cm and held in place with a finger. This Veress is now passed from the external skin wound of the port-site and the suture left in the abdomen under the vision of the laparoscope. The Veress is removed and introduced through the other edge of the wound, and the fascial insertion site is about 2 cm lateral to the previous Veress insertion.

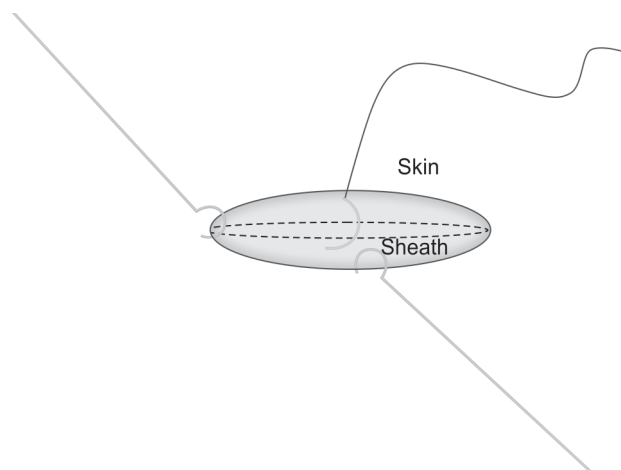


Fig. 4: Skin hooks taut the sheath and facilitate easy passage of sutures



Fig. 6: Carter–Thomason II port-site closure device is an improved version of the carter

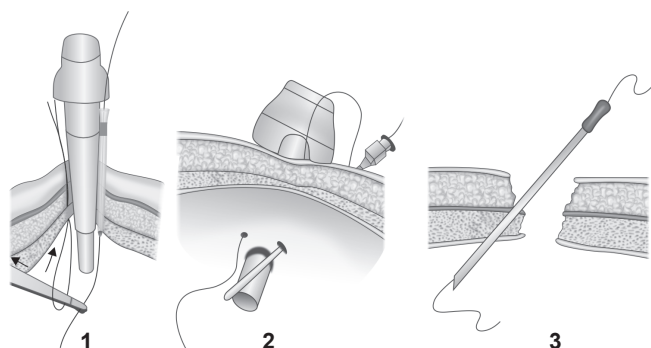


Fig. 5: Carter–Thomason needle point suture passer device

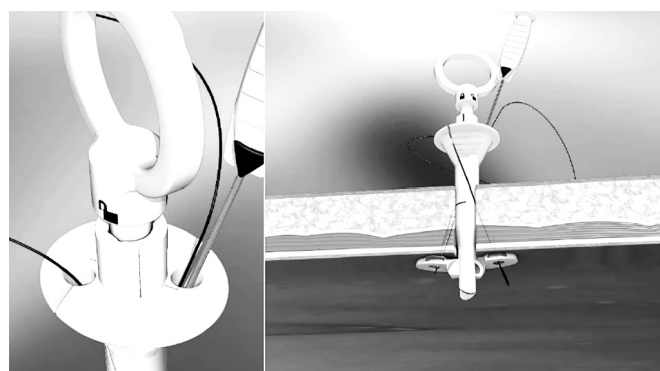


Fig. 7: WECK EFX™ Endo Fascial Closure System (EFx)

The suture end is held in the loop of the thread which is in the Veress and is pulled out through the skin incision and tied externally under vision. They report no incidence of port-site hernia or any other complications.

Maciol Suture Needle Set

Contarini²⁴ used these needles (Fig. 8). This is a set of three needles, two black handled introducers, one curved and one straight and a golden retriever. The introducer needle passes the suture into the peritoneal cavity from the subcutaneous tissue. The retriever needle (with a barb) is then passed into the peritoneal cavity on the opposite side of the defect to retrieve the suture and then pulled back through the tissue. This procedure is performed under the telescopic visualization before trocar withdrawal and does not require enlargement of skin incision.

Hypodermic Needles

Chung²⁵ used hypodermic needles as a conduit for threading the suture through the fascia. They reported used this technique in more than 150 patients without a single complication.

Five mm Trocar Technique

Chapman et al.²⁶ used the 5 mm telescope to inspect the defect from the inside of the abdomen and then a hemostat was passed through the incision. Under laparoscopic vision, the peritoneum and the rectus sheath are

grasped and pulled through the incision and facilitates the passage of the needle.

Suture Carrier

Jorge et al.²⁷ and Li and Chung developed this carrier which made use of the vertical space. This is a hook suture carrier which is modified from a simple hook retractor which has an eye in the tip through which suture can be threaded (Fig. 9). The edge of the fascia is lifted vertically using a hook retractor, and the suture carrier is partially inserted to catch the peritoneum and fascia under direct vision, piercing it from the lower surface. The 0-polypropylene suture is then fed into the eye of the carrier and brought beneath the fascia. The suture is then passed from the edge of the opposite end of the wound with the carrier and takes a stitch from inside to outside. After that, a knot is tied on the surface of the port-wound.

Using 2 S Retractors

Homayara Haque²⁸ used 2 S retractors for suture placement at a port-site under direct visualization. In this technique, one S retractor was introduced into the peritoneal cavity and supports the abdominal wall (Fig. 10). Second S retractor retracts the skin, fat, and muscle in the opposite direction exposing the fascia. A needle-suture is then used to take a bite in the fascia, and this process is repeated in the opposite edge of the wound using the same needle-suture. The two ends are tied and fascia is closed. They reported the use of this technique in 100 patients with no complications during a mean follow-up of 6 weeks and a 12-month annual follow-up.

Lasheen looped needle

Lasheen et al.²⁹ used two looped needles for laparoscopic port closure (Fig. 11). First looped needle and slowly absorbable suture no. 0 (braided coated glycolide homopolymer violet) inside it are passed through the skin about 2 cm from one side of the trocar site and appears from the abdominal cavity. The second

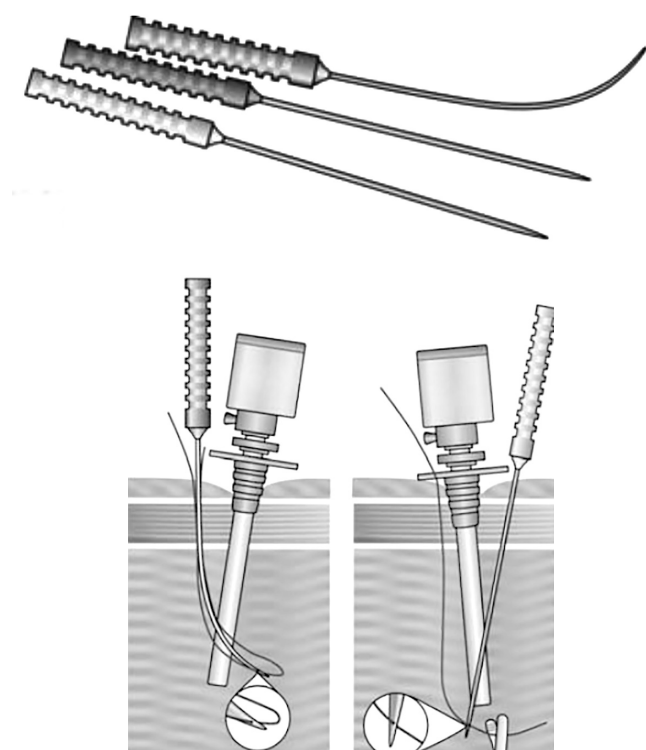


Fig. 8: Maciol suture needle set and closure technique.




Fig. 9: Single jaw action suture carrier

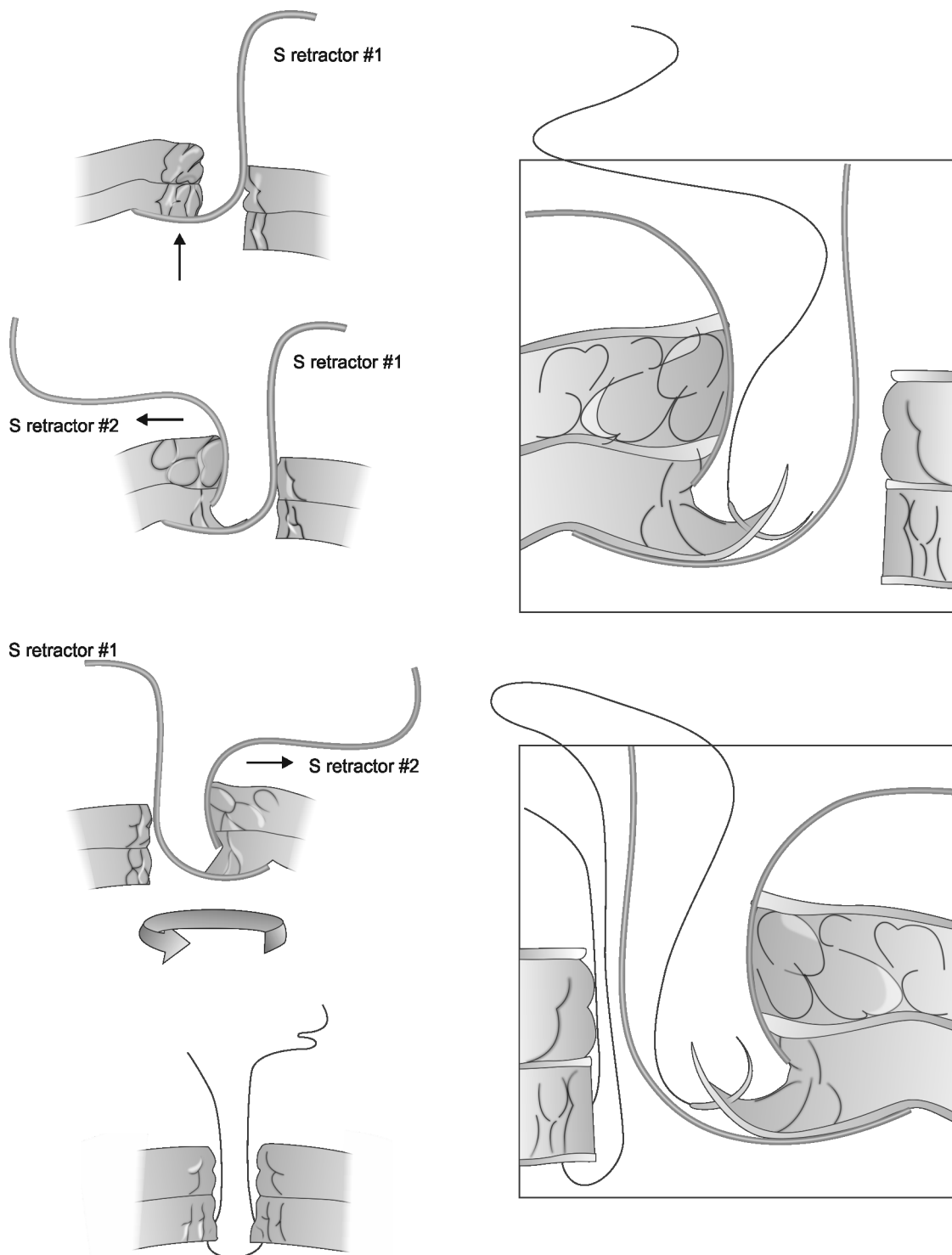


Fig. 10: Technique using 2 S-retractors for suture placement under direct visualization to secure the abdominal wall fascia and peritoneum

looped needle then passes through the skin about 2 cm from another side of the trocar site to appear from the abdominal cavity. Then, the thread end from the first needle is fed into the loop of the second needle and the stent withdraws to hold the thread end inside the needle. The stent of the first needle is pushed to make the thread free through the loop (Fig. 12). Then, both needles with thread are withdrawn until the needle tips appear at the subcutaneous plane.

The trocar sheath is removed, and both needles are redirected and pushed through the subcutaneous plane to bring the two ends of thread at the port wound. Both thread ends are detached from the looped needles and held by tissue forceps and tied after removal of the laparoscopic port. They reported the use of this technique in 87 patients of laparoscopic cholecystectomy and no port-site hernias were reported during a mean to follow-up of 18 months.

Port Plug

A bioabsorbable hernia plug (Fig. 13) is used in the trocar site with the help of bioabsorbable hernia plug device. Moreno et al.³⁰ used this technique in a pilot study on 17 patients undergoing laparoscopic surgery. The mean follow-up was 14.6 months, and no complications were reported. Different methods of placement of the hernia plug are shown in Figures 14 and 15.

DISCUSSION

Meticulous closure of laparoscopic ports is pertinent to prevent the occurrence of port-site incisional hernia,




Fig. 11: Looped needle formed of Long needle (20 cm outer sheath) and metal stent (25 cm put inside the outer sheath needle) has large loop (plastic wire).

incorporation of bowel in port-site closures, and their complications. Inadequate suturing of the fascial defect, infection, or suture disruption may lead to an incisional hernia or ascitic fluid leakage in the case of patients with cirrhosis.

The incidence of port-site hernia has been reported at about 0.23% at the 10 mm port-site, 1.9% at the 12 mm port-site. Most of the studies have reported hernias in port size 10 mm or higher.^{31,32} The 5 mm port has shown a very low incidence of port-site hernias.

Classification

Port-site hernias can be classified into:

- *Early onset:* occurring within 2 weeks of surgery with dehiscence of fascial planes and peritoneum. These present most commonly with small bowel obstruction.
- *Late-onset:* Occurring after 2 weeks with dehiscence of the fascial plane with intact peritoneal hernia sac. Around 12.50% of these present with intestinal obstruction.
- *Special:* Which presents with dehiscence of the whole abdominal wall.³³

Port-site Hernia Pathogenesis

Various factors play a role in the pathogenesis of a port-site hernia:

- *Large trocar size:* Trocar size and access technique used can affect the rate of hernia formation. Port-site hernia is related to more complex procedures that require

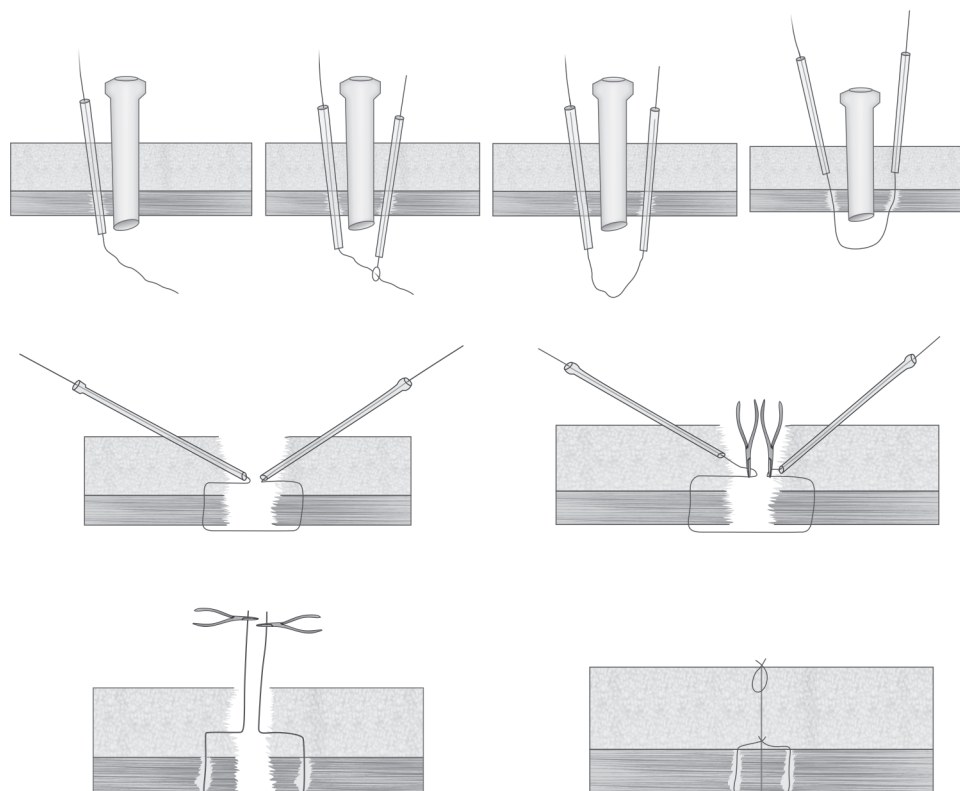


Fig. 12: Steps of closure using the looped needle




Fig. 13: Bioabsorbable hernia plug

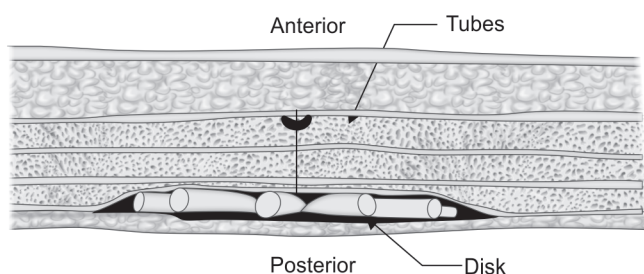


Fig. 15: Placement method 2 of bioabsorbable hernia plug –The disk and tubes are placed against the posterior wall of the defect. The defect can be closed with sutures. Care should be taken to ensure that the disk is placed flat

multiple ancillary ports and larger diameter ports used for specimen removal and stapling device.³⁴

- Single-incision surgeries have an increased risk of hernia development than multi-port laparoscopy³⁵ probably because they rely on a larger port.
- The use of port devices designed to minimize the leakage of insufflated air like fascial screws also contributes in increasing the size of the incision and may also lead to facial tissue damage, thereby increasing the risk for a port-site hernia.
- Incomplete closure of fascia at the trocar site.
- *Midline trocars:* Umbilical sites are more common.^{36,37} In a survey American Association of Gynecologic Laparoscopists reported that an umbilical hernia was the most common which was 75.70% and lateral hernias were reported at 23.70% of 152 trocar site hernias.³⁸
- Trocar site hernia incidence was higher in closed laparoscopy (Veress needle technique).³⁹
- Stretching of the port-site for retrieval might lead to an extension of the fascial defect and can be a significant risk factor.⁴⁰
- The partial vacuum created while withdrawing the port may draw the omentum and the intestines into the fascial defect.
- Although not statistically significant, higher body mass index was related to higher trocar site hernias in one study.⁴¹

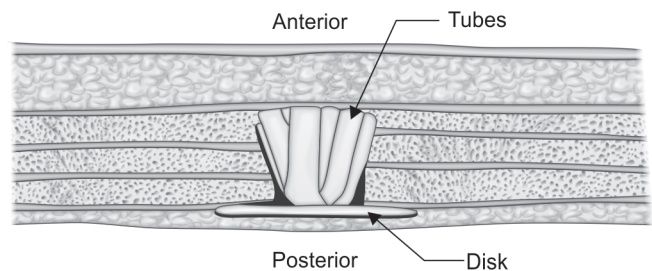


Fig. 14: Placement method 1 of bioabsorbable hernia plug–The disk is placed against the posterior wall of the defect and tubes fill the void space of the defect. It has to be ensured that the disk is placed flat

- In patients with morbid obesity, the risk of preperitoneal hernias was higher because of the thicker preperitoneal space and raised intra-abdominal pressure.⁴²
- Postoperative port-site wound infection is one important factor predisposing to the development of port-site hernia.⁴³
- Trocar type is also important in the development of port-site hernia. Blunt (conical, pyramidal, radially dilating, nonbladed) have been shown to produce reduced length and surface area of fascial defects over bladed or cutting trocars in animal studies with muscle splitting instead of cutting.^{44,45}
- Extensive manipulation of the trocar site may lead to the widening of the port-site incision. Fascial and peritoneal stretching seen in specimen removal, multiple re-insertions of the port, higher surgical difficulty leading to increased torque and force on the fascia and prolonged operative time.
- Pre-existing fascial defects–It was found in a study by Ramachandran that 18%, of the 2100 patients undergoing laparoscopic procedures, had pre-existing umbilical fascial defects. These defects were repaired, and no relation was found between pre-existing fascial defects and development of a hernia. In contrast, in a report on 1300 laparoscopic cholecystectomies, Azurin⁴⁶ reported that 9 out of 10 port-site hernias developed in patients who had been diagnosed with a pre-existing hernia preoperatively, despite intraoperative repair. These patients had umbilical closure with figure-of-eight polyglycolic acid sutures. When a hernia was symptomatic or identified preoperatively, it was repaired at the time of surgery with nonabsorbable, interrupted sutures. Hence the trocar sites of pre-existing hernias must be carefully examined to confirm adequate closure.

The Advantage of One Entry and Closure Technique Over Other

A Cochrane review from 2008 that evaluated different entry techniques reported no advantage in using any single technique over another to prevent major complications.⁴⁷

They did not report data relating to laparoscopic trocar hernias.

One randomized trial conducted an intraoperative evaluation of laparoscopic closure techniques. Elashry et al.⁴⁸ studied the closure of 95 twelve-mm trocar port-sites in 32 patients and compared the Carter-Thomason (CT-NP) needlepoint suture device (CooperSurgical, Inc, Trumbull, CT) with the Maciol suture needle set (Specialty Surgical Instrumentation, Nashville, TN), eXit disposable puncture closure device (Progressive Medical, St. Louis, MO), the Endoclose device (Covidien Surgical, Norwalk, CT), a 14-gauge angiocatheter, Lowsley retractor (CS Surgical Inc, Slidell, LA) with hand-sutured closure, and standard hand-sutured closure. They found that the CT-NP device was faster (mean time 2.5 minutes) and had secure closure confirmed digitally and endoscopically. They, however, did not follow their patients for hernia development. This study was underpowered, and hence no definitive conclusions could be made about the benefit of one closure type over another in hernia development.

Patient Presentation

The incidence can be said to be underestimated, as the patients present only if they are symptomatic. The real incidence, however, can be established only if an abdominal CT-scan will be done for each patient operated with a laparoscopic approach, which is overburdening to the patient as well as the health-care system. The usual hernia contents are omentum and to a lesser degree, small bowel.

Richter's hernia occurs when a part of the bowel wall that is the antimesenteric border, herniates through the port-site. The incidence of Richter's hernia was about 47.50% in early onset hernias in one study and they typically present with nausea, vomiting, pain and abdominal distention.³³ Computed tomography and gastrointestinal contrast studies have been used to aid the diagnosis of trocar site hernias.⁴⁹

Whether to Close or Not

A study by Singal et al.⁵⁰ a total of 200 non-obese patients, who were posted for various laparoscopic procedures, were prospectively studied. They were divided into two groups and with group A receiving only skin closure without fascial closure and group B receiving both fascial and skin closure, of the 10 mm port. The 5 mm ports were closed only with skin closure. They found no significant difference between the groups in terms of port-site hernia, bleeding and infection rates. Blunt 10 mm trocars were used in all the patients. Bladeless trocars have been shown to atraumatic, and they split, rather than cut the muscle fibers upon entry.⁵¹ Liu used

non-bladed trocars and concluded that it helps in the creation of ports with the smallest dissection without bleeding or cutting the muscle fibers.⁵² This splitting of abdominal wall musculature by trocar allows the surgeon to forego closure of small fascial defects. Bladeless 12 mm visual entry trocars have also been shown to produce no intraoperative bowel or vascular injuries, no mortality and extremely low rate of trocar site hernia of 0.2%.⁵³ Single-incision laparoscopic surgeries are finding greater acceptance among the surgeons and patients due to better cosmetic outcomes. These depend heavily on the 12 mm ports, for visualization and instrumentation. A study suggests that single incision laparoscopic surgery has a higher incidence of port-site hernia when compared to conventional laparoscopy.⁵⁴ Studies have also shown a higher incidence of port-site hernia in cases of single incision robotic procedures.⁵⁵

With the multitude of port entry and closure techniques, it will be an uphill task for the surgeon to familiarize with all the techniques. Every entry technique comes with its own set of advantages and disadvantages. Similarly, the closure techniques also have their pros and cons. It is prudent on the part of the surgeon to decide upon the preferred technique. The bladeless, blunt and radially dilating trocars have been proven to be superior in various studies.⁵¹⁻⁵³

All the 10 mm and 12 mm ports should ideally be closed otherwise the morbidity associated with the port site hernia will adversely affect the expected benefits of the intended minimally invasive surgery.

Regarding the port closure, the authors would like to present a few recommendations, after reviewing various articles on entry and closure techniques, which would help to minimize the risk of port site hernia development.

- Obese patients pose a problem due to the thickness of the abdominal wall and long needle carriers may be needed to secure proper closure.¹⁹
- Ports which are 10 mm and higher, either midline or lateral, must be closed at the level of fascia.^{29,56}
- The use of minimal necessary ports. Neudecker et al. had shown that port site complications were increased with increased number of ports.⁵⁶
- Port closure should incorporate both fascia and peritoneum.⁵⁶
- The 5 mm ports may generally be closed at skin level but in case of enlargement of the fascial and/or peritoneal defect during the surgery, mostly due to more time-consuming procedures or those which require extensive manipulation must be closed at fascial level too.⁵⁷
- The midline port sites in all patients must be closed using standard methods through the skin wound particularly if it is enlarged due to tissue retrieval.⁵⁸

- It would be advisable to view the abdominal side of each wound, wherever possible, during fascial closure via the laparoscope.⁶²
- Use of excessive torque or levering must be avoided as this may lead to enlargement of the fascial defect.⁶⁰
- Trocar insertion in an oblique fashion or a Z-tract may reduce hernia formation by putting the external and internal defects at different levels.⁶³
- Percutaneous surgical system use in place of a standard port is advisable if the port is being used only for minimal instrumentation.⁶⁴
- Use the smallest diameter ports necessary.⁶⁵
- Desufflate the abdomen carefully while port removal as the escaping CO₂ tends to draw the omentum and bowel into the port site. This is called chimney effect. This can also be seen during specimen removal.^{62,66}
- Ideally, the 5 mm ports must be removed under the vision of the laparoscope to prevent the chimney effect.^{62,66,67}
- The abdomen can be shaken before removal of the ports to dislodge any omentum or bowel adherent to the port sites.
- Palpate the abdomen before closure to identify any unrecognized or preexisting hernial defects that may require repair.
- Presence of incidental paraumbilical or umbilical hernias necessitates enlarging the incision and performing a formal umbilical herniorrhaphy and a patch may sometimes be required.⁶⁴

CONCLUSION

Port closure is one of the most pertinent steps of a minimal access surgery and closure has to be achieved in all the ports which are 10 mm or greater. Care must be taken to inspect the 5 mm ports and closure achieved in case where excessive leverage or torque has come into play. Any of the abovementioned port closure methods may be utilized. The ideal technique in the view of the authors are those that are inexpensive, require minimal additional instruments, require minimum skill, are easy to learn, can produce reproducible results and most importantly, must produce minimal to no port site hernia. The classical suture passer, veress needle or their basic modifications might come close to the ideal port closure technique.

REFERENCES

1. Kennedy GD. Laparoscopy decreases postoperative complication rates after abdominal colectomy: results from the national surgical quality improvement program. *Ann Surg.* 2009 Apr;249(4):596-601.
2. Morgenstern L. No surgeon here. John C. Ruddock, M.D., F.A.C.P., pioneer in laparoscopy. *Surg Endosc.* 1996 Jun;10(6):617-618.
3. Walker Reynolds J. The first laparoscopic cholecystectomy. *JSLS: Journal of the Society of Laparoendoscopic Surgeons.* 2001;5(1):89-94.
4. Sain AH. Laparoscopic cholecystectomy is the current "gold standard" for the treatment of gallstone disease. *Annals of surgery.* 1996;224(5):689-690.
5. Eden CG, King D, Kooiman GG, Adams TH, Sullivan ME, Vass JA. Transperitoneal or extraperitoneal laparoscopic radical prostatectomy: does the approach matter? *J Urol* 2004; 172: 2218-2223.
6. Bemelman WA, Dunker MS, Busch ORC, Den Boer KT, De Wit LTH, Gouma DJ. Efficacy of establishment of pneumoperitoneum with the Veress needle, Hasson trocar, and modified blunt trocar (TrocDoc): a randomized study. *J Laparoendosc Adv Surg Tech.* 2000;10:325-329.
7. Hasson HM. A modified instrument and method for laparoscopy. *Am J Obstet Gynecol.* 1971;110(6):886.
8. diZerega GS, Campeau JD. Peritoneal repair and post-surgical adhesion formation. Human reproduction update. 2001 Nov 1;7(6):547-555.
9. Elkins TE. A histological evaluation of peritoneal injury and repair: implications for adhesion formation. *Obstet Gynecol.* 1987;70:225-228.
10. Fear RE. Laparoscopy: a valuable aid in gynecologic diagnosis. *Obstetrics & Gynecology.* 1968 Mar 1;31(3):297-309.
11. Crist DW, Gadacz TR. Complications of laparoscopic surgery. *Surg Clin North Am* 1993;73:265-73289.
12. Phillips EH, Arregui M, Carroll BJ, Corbitt J, Crafton WB, Fallas MJ, Filipi C, Fitzgibbons RJ, Franklin MJ, McKernan B, Olsen D. Incidence of complications following laparoscopic hernioplasty. *Surgical endoscopy.* 1995 Jan 1;9(1):16-21.
13. Swank HA, Mulder IM, La Chapelle CF, Reitsma JB, Lange JF, Bemelman WA. Systematic review of trocar site hernia. *British Journal of Surgery.* 2012 Mar;99(3):315-23.
14. Bensley RP, Schermerhorn ML, Hurks R, Sachs T, Boyd CA, O'Malley AJ, Cotterill P, Landon BE. Risk of late-onset adhesions and incisional hernia repairs after surgery. *Journal of the American College of Surgeons.* 2013 Jun 1;216(6):1159-167.
15. Tonouchi H, Ohmori Y, Kobayashi M, Kusunoki M. Trocar site hernia. *Arch Surg.* 2004 Nov; 139(11):1248-1256.
16. Shaher Z. Port closure techniques. *Surg Endosc.* 2007 Aug;21(8):1264-1274. Epub 2007 Feb 7.
17. Kamber E, Unalp HR, Derici H, Tansug T, Onal MA. Laparoscopic cholecystectomy accompanied by simultaneous umbilical hernia repair: A retrospective study. *J Postgrad Med* 2007;53:176-180.
18. Botea F, Torzilli G, Sarbu V. A simple, effective technique for port-site closure after laparoscopy. *JSLS: Journal of the Society of Laparoendoscopic Surgeons.* 2011 Jan;15(1):77.
19. Lasheen A, Safwat K, Fiad A, Elmoregy A, Hamed AW. Port-site closure using a modified aptos needle. *JSLS: Journal of the Society of Laparoendoscopic Surgeons.* 2013 Apr;17(2):312-315.
20. Shah PR, Naguib N, Thippeswamy K, Masoud AG. Port site closure after laparoscopic surgery. *J Minim Access Surg.* 2010 Jan-Mar; 6(1):22-23.
21. Carter JE. A new technique of fascial closure for laparoscopic incisions. *Laparoendosc Surg.* 1994 Apr;4(2):143-148.
22. del Junco M, Okhunov Z, Juncal S, Yoon R, Landman J. Evaluation of a novel trocar-site closure and comparison with a standard Carter-Thomason closure device. *J Endourol.* 2014 Jul;28(7):814-818.

23. Kotakala BK, Mishra R. Veress Needle for Port-site Closure. Mishra RK, Fronek JP, editors. *World Journal of Laparoscopic Surgery with DVD* [Internet]. Jaypee Brothers Medical Publishing; 2015;8:39-42.
24. Contarini O. Complication of trocar wounds. Meirero M, Melotti G, Mouret Ph (eds). *Laparoscopic surgery*. Milano, Italy: Masson SpA. 1994:38-44.
25. Chung RS. Closure of trocar wounds in laparoscopic operations. The threading technique. *Surg Endosc*. 1995 May;9(5):534-536.
26. Chapman WH III. Trocar-site closure: a new and easy technique. *J Laparoendosc Adv Surg Tech A* 1999 Dec;9(6):499-502.
27. Jorge C, Carlos M, Alejandro W. A simple and safe technique for closure of trocar wounds using a new instrument. *Surgical laparoscopy & endoscopy*. 1996 Oct;6(5):392-393.
28. Aziz HH. A simple technique of laparoscopic port closure. *JLS: Journal of the Society of Laparoendoscopic Surgeons*. 2013 Oct;17(4):672-674.
29. Lasheen AE, Safwat K, Elshewael A, Ibrahim A, Mahmoud R, Alkilany M, Ismaeil A. Effective, simple, easy procedure for laparoscopic port closure in difficult cases. *Annals of medicine and surgery*. 2016 Sep 1;10:36-40.
30. Moreno-Sanz C. Prevention of trocar site hernias: description of the safe port plug technique and preliminary results. *Surg Innov*. 2008 Jun;15(2):100-104.
31. Kadar N, Reich H, Liu CY, Manko GF, Gimpelson R. Incisional hernias after major laparoscopic gynecologic procedures. *American journal of obstetrics and gynecology*. 1993 May 1;168(5):1493-1495.
32. Montz FJ, Holschneider CH, Munro MG. Incisional hernia following laparoscopy: a survey of the American Association of Gynecologic Laparoscopists. *Obstet Gynecol*. 1994 Nov; 84(5):881-884.
33. Tonouchi H, Ohmori Y, Kobayashi M, Kusonoki M. Trocar site hernia. *Arch Surg*. 2004;139:1248-1256.
34. Johnson WH, Fecher AM, McMahon RL, Grant JP, Pryor AD. VersaStep TM trocar hernia rate in unclosed fascial defects in bariatric patients. *Surgical Endoscopy And Other Interventional Techniques*. 2006 Oct 1;20(10):1584-1586.
35. Marks JM, Phillips MS, Tacchino R, Roberts K, Onders R, DeNoto G, Gecelter G, Rubach E, Rivas H, Islam A, Soper N. Single-incision laparoscopic cholecystectomy is associated with improved cosmesis scoring at the cost of significantly higher hernia rates: 1-year results of a prospective randomized, multicenter, single-blinded trial of traditional multiport laparoscopic cholecystectomy vs single-incision laparoscopic cholecystectomy. *Journal of the American College of Surgeons*. 2013 Jun 1;216(6):1037-1047.
36. Duron JJ, Hay JM, Msika S, Gaschard D, Domergue J, Gainant A, et al. Prevalence and mechanisms of small intestinal obstruction following laparoscopic abdominal surgery: a retrospective multicenter study. *Arch Surg* 2000;135208-135212.
37. Azurin DJ, Go LS, Arroyo LR, Kirkland ML. Trocar site herniation following laparoscopic cholecystectomy and the significance of an incidental preexisting umbilical hernia. *The American Surgeon*. 1995 Aug;61(8):718-720.
38. Montz FJ, Holschneider CH, Munro MG. Incisional hernia following laparoscopy: a survey of the American Association of Gynecologic Laparoscopists. *Obstet Gynecol* 1994; 84:881-84884.
39. Mayol J, Garcia-Aguilar J, Ortiz-Oshiro E, Jose A, Fernandez-Repres JA. Risks of the minimal access approach for laparoscopic surgery: multivariate analysis of morbidity related to umbilical trocar insertion. *World J Surg* 1997;21529-21533.
40. Nassar AH, Ashkar KA, Rashed AA, Abdulmoneum MG. Laparoscopic cholecystectomy and the umbilicus. *Br J Surg* 1997;84630-84633.
41. Bowrey DJ, Blom D, Crookes PF, Bremner CG, Johansson JL, Lord RV, et al. Risk factors and the prevalence of trocar site herniation after laparoscopic fundoplication. *Surgical endoscopy*. 2001 Jul 1;15(7):663-666.
42. Cottam DR, Gorecki PJ, Curvelo MW, Weltman D, Angus LD, Shaf-tan G. Preperitoneal herniation into a laparoscopic port site without a fascial defect. *Obes Surg* 2002;12121-12123.
43. Ramachandran CS. Umbilical hernial defects encountered before and after abdominal laparoscopic procedures. *Int Surg* 1998;83171-173.
44. Tarnay CM. Incisional characteristics associated with six laparoscopic trocar-cannula systems: a randomized, observer-blinded comparison. *Obstet Gynecol*. 1999. July;94(1):89-93.
45. Bhoirul S. Radially expanding dilatation. A superior method of laparoscopic trocar access. *Surg Endosc*. 1996. July;10(7):775-778.
46. Ahmad G, Duffy JM, Phillips K, Watson A. Laparoscopic entry techniques. *Cochrane Database Syst Rev*. 2008 Apr 16; (2):CD006583.
47. Elashry OM, Nakada SY, Wolf JJ, Figenschau RS, McDougall EM, Clayman RV. Comparative clinical study of port-closure techniques following laparoscopic surgery. *Journal of the American College of Surgeons*. 1996 Oct;183(4):335-344.
48. Sanz-Lopez R, Martinez-Ramos C, Nunez-Pena JR, Ruiz de Gopegui M, Pastor-Sirera L, Tamames-Escobar S. Incisional hernias after laparoscopic vs open cholecystectomy. *Surg Endosc* 1999;13:922-924.
49. Singal R. No Need of Fascia Closure to Reduce Trocar Site Hernia Rate in Laparoscopic Surgery: A Prospective Study of 200 Non-Obese Patients. *Gastroenterology Res*. 2016 Oct;9(4-5):70-73.
50. Lee J, Zheng XJ, Ng CY. Trocar site hernias from using bladeless trocars: should fascial closure be performed? *J Surg Case Rep*. 2014 May 15; 2014(5).
51. Liu CD, McFadden DW. Laparoscopic port sites do not require fascial closure when nonbladed trocars are used. *Am Surg*. 2000 Sep; 66(9):853-854.
52. Rosenthal RJ, Szomstein S, Kennedy CI, Zundel N. Direct visual insertion of primary trocar and avoidance of fascial closure with laparoscopic Roux-en-Y gastric bypass. *Surg Endosc*. 2007 Jan; 21(1):124-128.
53. Antoniou SA, Garcia-Alamino JM, Hajibandeh S, Hajibandeh S, Weitzendorfer M, Muysoms FE, et al. Single-incision surgery trocar-site hernia: an updated systematic review meta-analysis with trial sequential analysis by the Minimally Invasive Surgery Synthesis of Interventions Outcomes Network (MISSION). *Surgical endoscopy*. 2018 Jan 1;32(1):14-23.
54. Siddaiah-Subramanya M, Ashrafi D, Memon B, Memon MA. Causes of recurrence in laparoscopic inguinal hernia repair. *Hernia*. 2018 Dec;22(6):975-986.
55. Neudecker J. The European Association for Endoscopic Surgery clinical practice guideline on the pneumoperitoneum for laparoscopic surgery. *Surg Endosc*. 2002 Jul; 16(7):1121-1143.
56. Johnson WH, Fecher AM, McMahon RL, Grant JP, Pryor AD. VersaStep TM trocar hernia rate in unclosed fascial defects in bariatric patients. *Surgical Endoscopy And Other Interventional Techniques*. 2006 Oct 1;20(10):1584-1586.

57. Madhavan SM, Potunru VK, Augustine AJ. Bowel herniation through 5mm port site: an unusual complication. *Journal of clinical and diagnostic research: JCDR*. 2016 Apr;10(4):PD23-PD24.
58. Teixeira F, Yoo JH, Junior AJ. Incisional hernia at the insertion site of the laparoscopic trocar: Case report and the review of the literature. *Rev Hosp Clin Fac Med S Paulo* 2003;58:219-222.
59. Sreenivas S, Mohil RS, Singh GJ, Arora JK, Kandwal V, Chouhan J. Two-port mini laparoscopic cholecystectomy compared to standard four-port laparoscopic cholecystectomy. *Journal of minimal access surgery*. 2014 Oct;10(4):190-196.
60. Clark LH, Soliman PT, Odetto D, Munsell MF, Schmeler KM, Fleming N, et al. Incidence of trocar site herniation following robotic gynecologic surgery. *Gynecologic oncology*. 2013 Nov 1;131(2):400-403.
61. Karthik S, Augustine AJ, Shibumon MM, Pai MV. Analysis of laparoscopic port site complications: A descriptive study. *Journal of minimal access surgery*. 2013 Apr;9(2):59-64.
62. Alkatout I, Mettler L, Maass N, Noé GK, Elessawy M. Abdominal anatomy in the context of port placement and trocars. *Journal of the Turkish German Gynecological Association*. 2015;16(4):241-251.
63. Alkatout I. Principles and safety measures of electrosurgery in laparoscopy. *JSLs*. 2012 Jan-Mar; 16(1):130-139.
64. Mettler L. The past, present and future of minimally invasive endoscopy in gynecology: a review and speculative outlook. *Minim Invasive Ther Allied Technol*. 2013 Aug; 22(4):210-226.