

# Laparoscopic Inguinal Hernia Repair for Children is the Final Frontier: Experience from a Tertiary Care Center

Jyotirmaya Nayak<sup>1</sup>, Ashish Kumar Behera<sup>2</sup>, Rupashree Sahoo<sup>3</sup>

Received on: 20 August 2023; Accepted on: 15 September 2023; Published on: 14 February 2024

## ABSTRACT

**Background:** Pregnancy-induced hypertension (PIH) has been conventionally managed by open surgery and herniotomy which is the standard of care. But in the era of minimal access surgery, laparoscopic surgery for pediatric inguinal hernia has emerged as an alternative and is being routinely performed at many centers. Laparoscopic herniotomy is a safe and feasible option for pediatric inguinal hernia in present times. It has shown results similar to well-performed conventional herniotomy procedure with respect to marked reduction in operative time, and postoperative complications, postoperative pain, postoperative hospital stay, low rate of recurrence, no testicular atrophy, no iatrogenic ascent of testis, no postoperative hydrocele formation and excellent cosmesis. It provides a superior tool to diagnose contralateral patency of processus vaginalis (CPPV) or rare hernias that can be managed in the same session with minimal dissection, lesser postoperative complications, and better cosmesis thus favoring its wider adoption among surgeons globally in management of pediatric inguinal hernia.

**Method:** Data for all elective cases of PIH who underwent initial laparoscopic herniotomy repair in routine operation theater at our tertiary care center, during the period from 1st March 2010 to 1st March 2023 have been collected.

**Results:** A total of 53 laparoscopic inguinal herniotomies were performed on 50 patients. The median age of patients at the date of operation was 6.2 years. Of all patients, 47 cases were unilateral and 3 were bilateral inguinal hernias (IHs).

**Conclusion:** Laparoscopic inguinal herniotomy is a technically easier and safer technique than conventional open methods as there is no need for dissection of vas deferens and vessels. Laparoscopic herniotomy allows for the excellent visualization of cord structures and their proper safeguarding during the procedure. Simultaneous identification of CPPV in cases of unilateral IH and its repair reduces the risk of metachronous hernia as well. Less postoperative pain, early recovery, and better cosmesis make laparoscopic surgery the final frontier in the management of PIH, thus cementing its role as a viable and probably a better alternative to conventional repair.

**Keywords:** Herniotomy, Inguinal hernia, Laparoscopic.

*World Journal of Laparoscopic Surgery* (2024): 10.5005/jp-journals-10033-1600

## INTRODUCTION

The occurrence of inguinal hernia (IH) is a common surgical condition seen in infants and children, with prevalence rates varying from 1 to 4% in full-term neonates and reaching as high as 30% in preterm neonates.<sup>1-3</sup> Approximately 33% of IHs manifest before to 6 months of life, with males exhibiting an incidence rate almost 5–10 times higher than that of girls.<sup>1</sup> Contrary to expectations, the incidence of right-sided IHs is higher compared to left-sided hernias, even if bilateral hernias are present in 15–20% of children.<sup>1,4</sup> Inguinal hernia repair is a commonly performed surgical procedure that is now favored by doctors owing to its widespread occurrence.

Presently, there is ongoing research and development focused on a variety of treatments and techniques for the correction of hernias in infants and children. The current method of therapy for pediatric inguinal hernia involves the use of open surgery and herniotomy.<sup>5</sup> Nevertheless, in the era of restricted access surgery, laparoscopic surgery for pregnancy-induced hypertension (PIH) has emerged as a feasible alternative and is now routinely performed in several healthcare facilities worldwide. The use of laparoscopic ilio-pubic tract repair has been observed as a potential treatment option for cases of recurrence subsequent to laparoscopic ring closure.<sup>6</sup>

In the last 20 years, laparoscopy has gained significant recognition as both a diagnostic tool and a feasible treatment approach for managing IHs in young individuals.<sup>7</sup>

The technique of purse-string suture closure of the internal inguinal ring using sutures was first documented in a publication

<sup>1-3</sup>Department of Surgery, Srirama Chandra Bhanja Medical College and Hospital, Cuttack, Odisha, India

**Corresponding Author:** Jyotirmaya Nayak, Department of Surgery, Srirama Chandra Bhanja Medical College and Hospital, Cuttack, Odisha, India, Phone: +91 9438037714, e-mail: drjmnayak@gmail.com

**How to cite this article:** Nayak J, Behera AK, Sahoo R. Laparoscopic Inguinal Hernia Repair for Children is the Final Frontier: Experience from a Tertiary Care Center. *World J Lap Surg* 2024;17(1):5–8.

**Source of support:** Nil

**Conflict of interest:** None

in 1993. Subsequently, other modifications and alternatives to the therapeutic approach have been proposed, all aimed at the objective of excising the patent processus vaginalis in cases with IH.<sup>5</sup>

Laparoscopic herniotomy has emerged as a viable and secure therapeutic approach for the management of pediatric inguinal hernia. The results obtained are comparable to those achieved by proficient implementation of conventional herniotomy procedures. Advocates of the laparoscopic technique for hernia repair assert comparable efficacy to the open approach, accompanied by several supplementary advantages. These include notable reductions in operative duration, complications, pain, and hospitalization, as well as a low incidence of hernia recurrence, absence of testicular atrophy, iatrogenic ascent of the testis, and hydrocele formation.<sup>8</sup> Furthermore, the laparoscopic approach yields favorable cosmetic

outcomes. According to the cited source, laparoscopic surgery facilitates the identification of direct hernias. The utilization of this tool in the diagnosis of contralateral patency of the processus vaginalis (CPPV) or uncommon hernias, which can be effectively treated in a single session with minimal dissection, reduced complications, and improved cosmetic outcomes, has positioned it as a highly effective method for surgeons globally when managing pediatric inguinal hernia. In this study, we provide a retrospective review of our experience using laparoscopic herniotomy in pediatric patients at a tertiary care hospital.

## AIM AND OBJECTIVE OF THE STUDY

### Primary Objective

To perform a retrospective observational study on the prospectively collected data of pediatric patients who underwent laparoscopic IH repair (herniotomy) in the Department of general surgery, S.C.B. Medical College and Hospital between 1st March 2010 and 1st March 2023.

**Study type:** Retrospective observational study.

**Time period of study:** 1st March 2010 to 1st March 2023.

**Place of study:** Post Graduate Department of General Surgery, S.C.B. Medical College, Cuttack, Odisha, India.

**Sample size:** 50.

### Patient Selection

We retrospectively reviewed our elective surgery registry for all elective cases of PIH who underwent initial laparoscopic herniotomy repair in routine operation theater at our tertiary care center between 1st March 2010 and 1st March 2023 as per standard 3 port technique.

### Data Collection

Data on all laparoscopic herniotomies performed as elective cases in the routine operation theatre of S.C.B. Medical College and Hospital, Cuttack, from March 1, 2010 to March 1, 2023, were collected for this retrospective observational study.

Age, gender, body weight, associated co, site (unilateral or bilateral), duration of symptoms, history of any previous abdominal/surgery, findings on ultrasound of bilateral inguinoscrotal region, total duration of surgery (from placement of first port to taking last suture), operative findings, all operative events or complications, and total duration of hospital stay were all included in the data.

## METHOD

From March 1, 2010 to March 1, 2023, 50 patients with IH underwent laparoscopic herniotomy (LH) at our facility (46 men and 4 females). Parents were told about the many sorts of surgeries available and were offered laparoscopic surgery for their kid if they so wished. Under general anesthesia, all laparoscopic operations were conducted with the patient supine. For all patients, a pneumoperitoneum of 6–10 mm Hg was produced using Hasson's method via the first implanted infra umbilical trocar. (Fig. 1) The peritoneal cavity was visualized using a 5-mm telescopic camera. 3 or 2-mm triangulation tools were employed to close the inner inguinal ring. The deep inguinal rings on both sides were visualized after the ports were placed, and the inguinal hernia was detected. The sac was meticulously dissected from the chord structures (Fig. 2). Using a standard open surgery needle holder, a 3-0 suture

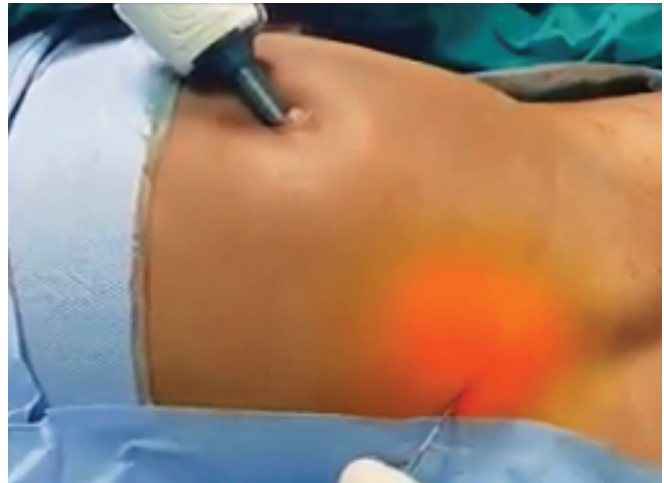

Fig. 1: Umbilical port placement

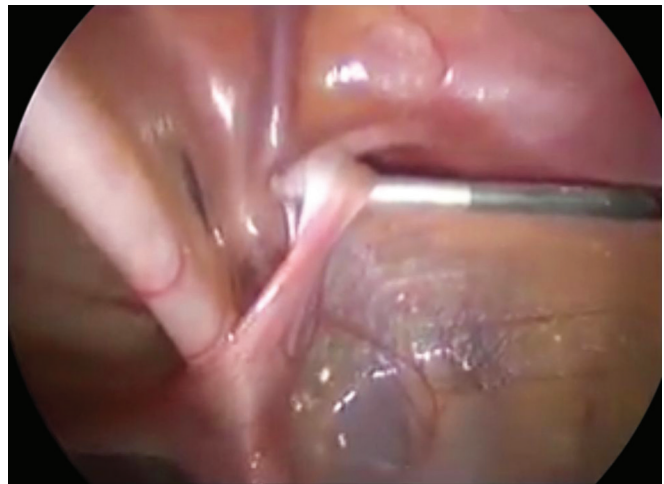

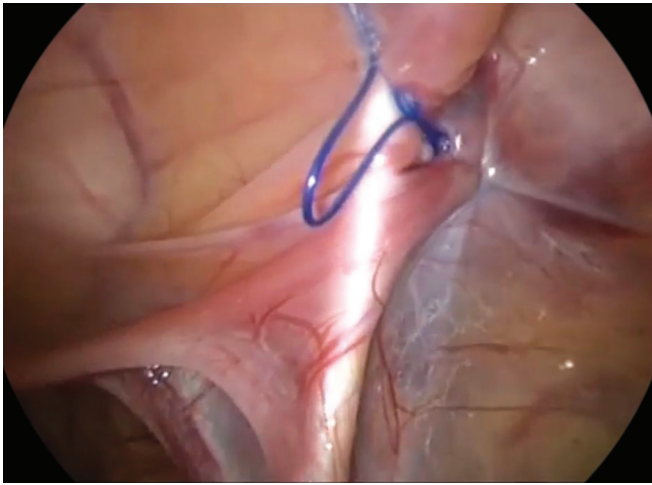
Fig. 2: Sac dissection

was cut to 8–12 cm and put straight through the abdominal wall adjacent to the internal inguinal ring. A purse string suture was used to seal the sac at the internal inguinal ring (Fig. 3). After the surgery was finished, we withdrew the two 5-mm operating ports and subsequently the umbilical camera port. The interventions were carried out in a 1-day surgical context using the following postoperative analgesic scheme: paracetamol 15 mg/kg iv, which was then repeated every 6 hours.

We utilized the Face, Legs, Activity, Cry (FLACC) scale to measure pain in children under the age of three. Children above the age of three were evaluated for pain duration using the Wong-Baker scale. Pain evaluation was completed at the end of the operating room, 2 hours, 6 hours, and at the end of the hospital stay. Outpatient department visits were scheduled 1 week, 3 months, and 6 months following the procedure.

## RESULTS

In all, 53 laparoscopic procedures were done on 50 patients. At the time of the procedure, the median age of the patients was 6.2 years. There were 47 unilateral and 3 bilateral IHs among all patients. The median surgical periods for unilateral and bilateral



**Fig. 3:** Ligation of sac

laparoscopic herniotomies were 76 and 118 minutes, respectively. The average operational time for unilateral repair was 3415.3 minutes, and 49.59.4 minutes for bilateral surgery. In 50 patients, a diagnosis of unilateral IH was made. In three of these patients (6%), laparoscopy showed a patent internal inguinal ring. Pain management was good in all patients. In 53 laparoscopic herniotomies, there were no recurrences. There were no further postoperative problems such as hydrocele, iatrogenic, testicular atrophy, or wound infection.

## DISCUSSION

The surgical correction of IHs is a commonly performed surgery in pediatric patients. The increased use of laparoscopic inguinal hernia repair may be attributed to the advancements made in the examination of the asymptomatic contralateral side since its introduction in the 1990s.<sup>4</sup> The advantages of this method include improved cosmetic outcomes, faster recovery times, less reliance on oral pain medications, enhanced visualization of anatomical structures, and the ability to identify and repair a contralateral patent processus vaginalis. Conversely, medical professionals who advocate for traditional open surgery express significant opposition against laparoscopic herniotomy, citing concerns over the augmented costs and duration associated with this particular approach. The rectification of the contralateral defect was performed concurrently during the surgical procedure, hence mitigating the potential occurrence of herniation in the future. The risk of injury to the vas deferens and blood arteries is significantly elevated in male infants who are less than 1 year old, since these anatomical structures are quite small and a delicate hernia sac is tightly attached to them. No postoperative complications, such as hydrocele, iatrogenic injury, testicular atrophy, or wound infection, were seen in any of the surgeries performed at our hospital.

All therapies were conducted inside a singular day of surgical procedures, using an identical postoperative analgesic approach. The laparoscopic technique, in contrast to the traditional approach, is a transperitoneal surgical procedure that has inherent risks. However, when managed by skilled professionals, these risks are substantially mitigated.

The preferred approach for repairing IHs in pediatric patients has traditionally been the open procedure, including the high ligation of the patent processus vaginalis.<sup>9</sup> This technique has

shown a good success rate and a low incidence of complications. In this study, we aim to investigate the effects of a new drug on patients with a nevertheless, the laparoscopic approach has emerged as a potential option because of its ability to address the limits and dangers involved with the aforementioned therapy. To start, it is important to note that herniotomy has inherent dangers, including iatrogenic complications, testicular shrinkage, and potential injuries to the vas deferens or artery. The prevalence of complete atrophy, for instance, may reach levels as significant as 0.3–3%. In this study, we aim to investigate the effects of a specific treatment on a particular population. While the aforementioned dangers are not limited only to the open procedure, they exhibit a significant occurrence rate of 2.7% after open hernia surgery, in contrast to the rate of 0.9% seen in laparoscopic hernia repair. Furthermore, it should be noted that open herniotomy procedures do not provide the opportunity to examine the contralateral internal inguinal ring for the presence of a hernia or patent processus vaginalis. It is worth mentioning that these conditions may be seen in about 56% of infants and children up to 2 years old, as well as in 40% of children older than 2 years, during the surgical intervention. Specifically in order to mitigate these concerns, several surgeons choose to do contralateral inguinal exploration as part of the open repair procedure, especially in babies between the ages of 1 and 2 years. Alternatively, some surgeons choose to conduct diagnostic laparoscopy via an umbilical incision or directly into the open hernia sac. According to a meta-analysis, the inclusion of laparoscopic inspection of the contralateral inguinal ring resulted in a little increase of 6 minutes in surgical duration. However, this procedure demonstrated a high level of sensitivity (99.4%) and specificity (99.5%) in detecting a patent processus vaginalis.<sup>10</sup>

Minimally invasive surgery has emerged as a viable and effective option for pediatric surgical treatment across a diverse spectrum of disorders and procedures, ensuring both safety and success. Laparoscopy is said to provide several advantages compared to open surgery, such as improved visualization, expedited recovery, reduced hospital stay, decreased painkiller use, diminished complications, and enhanced cosmetic outcomes. Laparoscopy has the additional benefit of facilitating straightforward viewing and assessment of the contralateral inguinal ring during the surgical correction of IHs.<sup>1,11</sup> Several new laparoscopic methods have been developed for the treatment of pediatric inguinal hernia, taking use of the numerous advantages associated with this approach.

The primary objective of various laparoscopic herniotomy techniques is to excise the patent processus vaginalis. The first technique described by Esposito and Montupet used the use of a purse-string suture to close the peritoneum at the internal inguinal ring. In 1998, Schier introduced a comparable methodology<sup>12</sup> which included the use of a series of sutures in the form of either "N" or "Z" across the internal inguinal ring. In 1999, Esposito introduced a modification in which the peritoneum located laterally to the internal inguinal ring was incised before to the placement of the purse-string suture.<sup>1,12,13</sup> Becmeur et al. subsequently proposed a technique that replicated each stage of the traditional open operation, including the excision of a portion of the patent processus vaginalis.<sup>14</sup> In the year 2011, Wheeler et al. conducted a study wherein they recorded the procedure of creating a peritoneal incision around the internal inguinal ring, followed by its closure using a purse-string suture.<sup>15</sup> Various techniques have been reported in the literature for the management of hernia sac during surgery. These techniques include the use of specialized awls or needles to



facilitate suture transfer across the hernia sac, as well as methods such as hydro dissection and the use of microincisions for ligating the sac. The success rates of these approaches exhibit variability contingent upon the laparoscopic skills and surgical expertise of the practitioner, yet demonstrating comparability to the open approach with success rates ranging from 95 to 100%.<sup>9,16</sup>

Despite the acknowledged benefits, shown equivalence to open surgery, and increasing use by juvenile general surgeons, the integration of laparoscopic herniotomy into the repertoire of pediatric surgeons has been met with caution.

## CONCLUSION

When performed in babies and children to repair an indirect hernia (i.e., patent processus vaginalis), laparoscopic herniotomy is both safe and successful. It is a safer procedure than the traditional open method since there is no need for vas deferens and vascular dissection. It enables great visualization of chord structures as well as their optimal protection throughout the treatment. In situations of unilateral IH, simultaneous diagnosis of patent processus vaginalis and treatment minimizes the likelihood of metachronous hernia.<sup>13</sup> There were no intraoperative problems. Despite its low use rate among pediatric surgeons to date, laparoscopic hernia repair is a well-established option to open surgery, particularly when double IHS are present or there is worry for a potential patent processus vaginalis. Less discomfort, faster recovery, and improved outcomes make it the ultimate frontier in the treatment of pediatric inguinal hernia, solidifying its position as a viable and likely superior option to traditional repair.

## ORCID

Jyotirmaya Nayak  <https://orcid.org/0000-0003-0452-3522>

## REFERENCES

1. Van Batavia JP, Tong C, Chu DI, et al. Laparoscopic inguinal hernia repair by modified peritoneal leaflet closure: Description and initial results in children. *J Pediatr Urol* 2018;14(3):272.e1–272.e6. DOI: 10.1016/j.jpurol.2018.02.015.
2. Esposito C, Escolino M, Turrà F, et al. Current concepts in the management of inguinal hernia and hydrocele in pediatric patients in Laparoscopic Era. *Semin Pediatr Surg* 2016;25(4):232–240. DOI: 10.1053/j.sempedsurg.2016.05.006.
3. Ein SH, Njere I, Ein A. Six thousand three hundred sixty-one pediatric inguinal hernias: A 35-year review. *J Pediatr Surg* 2006;41(5):980–986. DOI: 10.1016/j.jpedsurg.2006.01.020.
4. Shcheben'kov MV. The advantages of laparoscopic inguinal herniorrhaphy in children. *Vestn Khir Im II Grek* 1997;156(1):94–96. PMID: 9163206.
5. Palanivelu C. Laparoscopic pediatric hernia repair. In: *Operative Manual of Laparoscopic Hernia Surgery*. Coimbatore, India: Gem Foundation; 2004; pp. 195–205.
6. Schier F. Laparoscopic surgery of inguinal hernias in children—Initial experience. *J Pediatr Surg* 2000;35(9):1331–1335. DOI: 10.1053/jpsu.2000.9326.
7. Schier F. Direct inguinal hernia in children: The laparoscopic aspect. *J Pediatr Surg* 2000;16(8):562–564. DOI: 10.1007/s003830000431.
8. Davies DA, Rideout DA, Clarke SA. The International Pediatric Endosurgery Group Evidence-based guideline on minimal access approaches to the operative management of inguinal hernia in children. *J Laparoendosc Adv Surg Tech A* 2020;30(2):221–227. DOI: 10.1089/lap.2016.0453.
9. Alzahem A. Laparoscopic versus open inguinal herniotomy in infants and children: A meta-analysis. *Pediatr Surg Int* 2011;27(6):605–612. DOI: 10.1007/s00383-010-2840-x.
10. Mahmood B, Christoffersen M, Miserez M, et al. Laparoscopic or open paediatric inguinal hernia repair—A systematic review. *Dan Med J* 2020;67:A12190725. PMID: 32734885.
11. Schier F, Montupet P, Esposito C. Laparoscopic inguinal herniorrhaphy in children: A three-center experience with 933 repairs. *J Pediatr Surg* 2002;37(3):395–397. DOI: 10.1053/jpsu.2002.30842.
12. Arregui ME, Navarrete J, Davis CJ, et al. Laparoscopic inguinal herniorrhaphy—Techniques and controversies. *Surg Clin North Am* 1993;73(3):513–527. DOI: 10.1016/s0039-6109(16)46034-2.
13. Esposito C, Montupet P. Laparoscopic treatment of recurrent inguinal hernia in children. *Pediatr Surg Int* 1998;14(3):182–184. DOI: 10.1007/s003830050481.
14. Becmeur F, Philippe P, Lemandat-Schultz A, et al. A continuous series of 96 laparoscopic inguinal hernia repairs in children by a new technique. *Surg Endosc* 2004;18(12):1738–1741. DOI: 10.1007/s00464-004-9008-5.
15. Wheeler AA, Matz ST, Schmidt S, et al. Laparoscopic inguinal hernia repair in children with transperitoneal division of the hernia sac and proximal purse string closure of peritoneum: Our modified new approach. *Eur J Pediatr Surg* 2011;21(6):381–385. DOI: 10.1055/s-0031-1291181.
16. Miltenburg DM, Nuchtern JG, Jaksic T, et al. Laparoscopic evaluation of the pediatric inguinal hernia – A meta-analysis. *J Pediatr Surg* 1998;33(6):874–879. DOI: [https://doi.org/10.1016/S0022-3468\(98\)90664-9](https://doi.org/10.1016/S0022-3468(98)90664-9).